



PATIENT

Binx Cole

SPECIES

Feline

BREED

Sphynx

SEX

Neutered male

AGE

8 years

WEIGHT

4.07 kg

INTERPRETED BY

Bradley Harris, DVM,
 DACVECC, DACVIM
 (cardiology)

IMAGING PERFORMED BY

Kelly Reschny

HOSPITAL NAME

West Brant AH

REFERRING VET

Dr. Balaraju

INVOICE

77823

DATE

5/21/26

PRESENTING CLINICAL SIGNS

History: Increased respiratory effort is noted, with evidence of an expiratory push. Open-mouth breathing and paradoxical breathing pattern was observed intermittently. On auscultation, normal breath sounds were heard; no crackles or wheezes were detected. In between the cat was meowing/growling.

Oral: 1-2/4 dental plaque seen.

Cardiovascular: Normal heart sounds were auscultated with no murmurs or arrhythmias detected.

Current Medications Apo-Furosemide 20mg-- 1/2 BID, Benazepril 5mg- 1/2 BID, Prednisolone 5 mg- Give by mouth 1 tablet every 24 hours for 5 days. Then decrease to 1/2 tablet every 24 hours for 6 days. Then decrease to 1/2 tablet every other day until finished.

ULTRASONOGRAPHIC EXAMINATION OF THE HEART

The left atrium is severely enlarged, based on 3 separate methods of evaluation. There are no distinct left atrial thrombi/clots or spontaneous echo contrast appreciated. The left ventricle is normal in dimension, with moderate hypertrophy, and no evidence of restriction. Left ventricular systolic function is normal, with adequate contractility based on fractional shortening and systolic left ventricular dimensions. The right atrium and ventricle are subjectively normal in dimension and systolic function. The anterior and posterior mitral and tricuspid valve leaflets presented normal linear structure, extension in systole, and union in diastole without regurgitation. There is no evidence of systolic anterior mitral motion documented. The left ventricular outflow tract demonstrated normal laminar flow and subjective structural valvular integrity. The visible aorta is unremarkable. Pulmonary outflow tract assessment revealed normal valve structure, laminar flow, and appropriate diameter and distensibility. There is no evidence of semilunar valve insufficiency or pulmonary hypertension documented.

| FELINE CARDIAC PARAMETERS | BODY WEIGHT (kg) | HR (BPM) | IVSd (cm) | LVIDd (cm) | LVWd (cm) | FS (%) | EF (%) |
|------------------------------------------------------------------------------------------------------------------------------------------|------------------|---------------------------|----------------------|------------|-----------------|-----------------|-----------|
| NORMAL PARAMETER | ----- | 150-240 | 0.3-0.6 | 1.0-2.1 | 0.25-0.6 | 35-67 | 80-100 |
| PATIENT | 4.07 kg | 170 | 0.62 | 1.55 | 0.7 | 32 | 64 |
| FELINE CARDIAC PARAMETERS | LA/AO (M-mode) | LA/AO HEART BASE (Sisson) | LAD LA MAX 4 Chamber | | LVOT VEL. (m/s) | RVOT VEL. (m/s) | IVRT (m/) |
| NORMAL PARAMETER | <1.5 | 1.6 | 0.7-1.7 | | <1.6 | <1.3 | 40-60 |
| PATIENT | 3.2 | 3.72 | 2.32 | | 0.7 | 0.9 | NM |
| Adapted from June Boon, Veterinary Echocardiography, 1998 Sisson D et al. JVIM 1991; 5: 232, Jacobs et al. Am J Vet Res 1985; 46:1705 | | | | | | | |



| | |
|---------------------------------------------------|------------------------------------------------------------------------------------------------------------------------------------------------------------------------------------------------------------------------------------------------------------------------------------------------------------------------------------------------------------------------------------------------------------------------------------------------------------------------------------------------------------------------------------------------------------------------------------------------------------------------------------------------------------------------------------------------------------------------------------------------------------------------------------------------------------------------------------------------------------------------------------------------------------------------------------------------------------------------------------------------------------------------------------------------------------------------------------|
| PATIENT | ULTRASONOGRAPHIC FINDINGS |
| Binx Cole | These findings identify LV hypertrophy, in the absence of an outflow tract obstruction, consistent with hypertrophic cardiomyopathy (HCM). The presence of significant left atrial dilation makes CHF a likely explanation for the clinical/radiographic signs. |
| SPECIES | INTERPRETATION OF THE FINDINGS & FURTHER RECOMMENDATIONS |
| Feline | Therapy for CHF is indicated, to include Lasix (2mg/kg q24 to BID), Vetmedin (0.25-0.35mg/kg BID), and enalapril (0.5mg/kg q24, assuming normal blood pressure and kidney function). A systemic blood pressure and thyroid panel (to include a total T4 and free T4 by ED) are recommended to rule out systemic hypertension and hyperthyroidism as a cause for the left ventricular hypertrophy, respectively. If normal, then the left ventricular hypertrophy is secondary to primary hypertrophic cardiomyopathy. A repeat evaluation is recommended in 1-2 weeks, at which time the blood pressure, chemistry, thoracic radiographs should be repeated. At that time, the addition of Plavix (18.75mg q24) +/- rivaroxaban (2.5mg q24) is recommended. Due to the bitter taste of this medication, it may be best to place it in an empty gelatin capsule or use products such as a Pill Pocket. A repeat echocardiogram, blood pressure, chemistry, and thoracic radiographs are indicated in another 3-6 months, or sooner if the condition worsens. |
| BREED | |
| Sphynx | |
| SEX | |
| Neutered male | |
| AGE | |
| 8 years | |
| WEIGHT | <u>Anesthesia considerations:</u> |
| 4.07 kg | Anesthesia should be avoided until signs of congestion have resolved. If anesthesia is necessary, then alpha-2 agonists, ketamine, high dose acepromazine, and Telazol should be avoided. If an ACE inhibitor (enalapril, benazepril) or spironolactone is being given, it should not be administered on the morning of general anesthesia. Other cardiac medications should be administered per the normal dosing schedule. Anesthetic IV fluid use should be limited to < 3 ml/kg/hr and, if IV fluid therapy is administered during the procedure, a 1 mg/kg dose of IM Lasix should be administered when the patient is awake and standing in recovery. A shorter anesthetic duration will reduce the risk of complications. Pre-oxygenation is advised. Premedication with an opioid (i.e., butorphanol, hydromorphone, oxymorphone) with or without a benzodiazepine is generally the safest protocol. An induction agent such as Propofol, alfaxalone, or diazepam/etomidate can be used to effect. Maintenance of anesthesia with isoflurane or sevoflurane is reasonable. |
| INTERPRETED BY | |
| Bradley Harris, DVM, DACVECC, DACVIM (cardiology) | |
| IMAGING PERFORMED BY | <u>Diet:</u> |
| Kelly Reschny | A high-quality food from Hills, Royal Canin, Science Diet, Eukanuba, Iams, or Purina that is highly palatable with adequate protein and calories for maintaining optimal body condition with mild dietary sodium restriction (< 100 mg/100 kcal) is recommended. Consider omega-3 fatty acid supplementation. |
| HOSPITAL NAME | <u>Activity:</u> |
| West Brant AH | Avoid strenuous activity |
| REFERRING VET | |
| Dr. Balaraju | |
| INVOICE | |
| 77823 | |
| DATE | |
| 5/21/26 | |



PATIENT

Binx Cole

SPECIES

Feline

BREED

Sphynx

SEX

Neutered male

AGE

8 years

WEIGHT

4.07 kg

INTERPRETED BY

Bradley Harris, DVM,
 DACVECC, DACVIM
 (cardiology)

IMAGING PERFORMED BY

Kelly Reschny

HOSPITAL NAME

West Brant AH

REFERRING VET

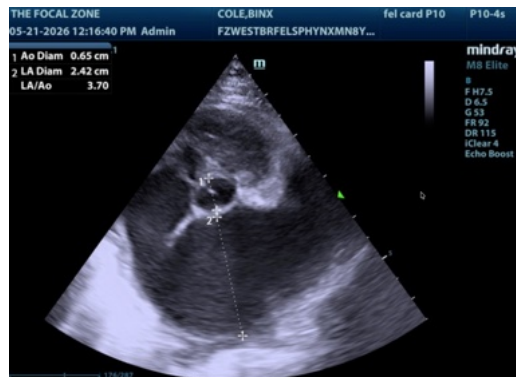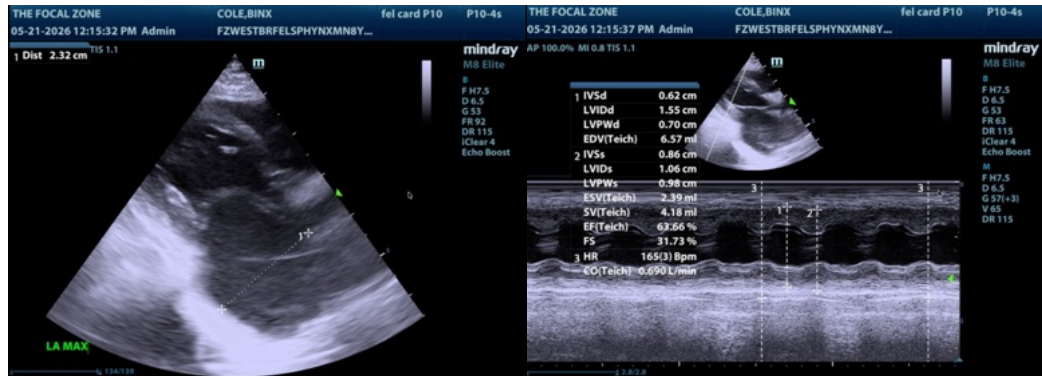
Dr. Balaraju

INVOICE

77823

DATE

5/21/26



The information and recommendations provided are based on the images presented by the referring veterinarian/sonographer. No evaluation can be communicated regarding pathology that was not visible in the image/video clips provided.

Thank you for this referral. If the clinical or image interpretation does not parallel your findings or if I can be of any further assistance please contact me.

Bradley Harris, DVM, DACVECC, DACVIM (cardiology)

info@SonoPath.com