



PATIENT PRESENTING CLINICAL SIGNS

PATIENT Rocky Santucci
SPECIES Canine
BREED Yorkie Cross
SEX Neutered male
AGE 14 years
WEIGHT 7.7 kg

PRESENTING CLINICAL SIGNS
 History: Grade 4/6 heart murmur, walnut sized mass on P's back. Would like to have mass removed, echo to access safety of anesthesia. Degenerative Mitral valve disease. Had a echo in 11/4/2025, recheck recommended in 6 months to monitor progression. Not on any therapies at this time.
 Current Medications
 Gabapentin, Apoquel

ULTRASONOGRAPHIC EXAMINATION OF THE HEART

The left atrium is normal in dimension. The left ventricle is normal in dimension, with normal systolic function. The right atrium and ventricle are normal in dimension, with normal systolic function. The anterior and posterior mitral valve leaflets are appropriately thin with adequate apposition, intact chordae, and there is no significant prolapse. There is mild mitral regurgitation identified. The tricuspid valve leaflets are appropriately thin with adequate apposition, intact chordae, no significant tricuspid regurgitation and no evidence of pulmonary hypertension. The left ventricular outflow tract demonstrated normal laminar flow and the visible aorta is unremarkable. The right ventricular outflow tract assessment revealed normal laminar flow, with appropriate main pulmonary artery diameter and right pulmonary artery distensibility. There is no pulmonic and no aortic valve insufficiency identified. There is no visible pericardial, pleural, or free peritoneal fluid documented. No evidence of hepatic venous congestion is noted. The cardiac chambers, pericardial and visible extra-cardiac regions were free of masses, spontaneous echo contrast, or thrombi.

INTERPRETED BY

Bradley Harris, DVM,
 DACVECC, DACVIM
 (cardiology)

IMAGING PERFORMED BY

Kelly Reschny

HOSPITAL NAME

BPH Stoney Creek

REFERRING VET

Dr. Ebrahimi

INVOICE

75399

DATE

5/13/26

CANINE CARDIAC PARAMETERS	Body Weight kg	HR BPM	LAD 4 ch Long	RAD 4 ch Long	La/Ao Heart Base	LVIDd	LVIDs
NORMAL PARAMETER		50-100			<1.6		
PATIENT	7.7 kg	160	3.07	1.51	1.4	2.65	1.43
CANINE CARDIAC PARAMETERS	FS	EPSS	PV V MAX (m/s)	AV V Max (m/sec)	MR Vmax	TR Vmax	RPA distensibility (normal >30%)
NORMAL PARAMETER	28-40	<0.6	0.7-1.6	0.7-1.7	4.5-5.5	< 2.7	
PATIENT	46	0.3	1.3	1.1	5.8	NM	NM

ECG:

There is a six-lead ECG available for review. The underlying rhythm is regular at an average rate of 160bpm. The rhythm appears to be sinus in origin with narrow QRS complexes. There is no atrial or ventricular ectopy and no conduction delay or block identified. This is most consistent with a normal sinus rhythm.



PATIENT

Rocky Santucci

SPECIES

Canine

BREED

Yorkie Cross

SEX

Neutered male

AGE

14 years

WEIGHT

7.7 kg

INTERPRETED BY

Bradley Harris, DVM,
DACVECC, DACVIM
(cardiology)

IMAGING PERFORMED BY

Kelly Reschny

HOSPITAL NAME

BPH Stoney Creek

REFERRING VET

Dr. Ebrahimi

INVOICE

75399

DATE

5/13/26

ULTRASONOGRAPHIC FINDINGS

These findings are consistent with degenerative/myxomatous mitral valve disease with minimal to mild hemodynamic effects consistent with ACVIM Stage B1 disease. There has been no significant progression in the underlying disease.

INTERPRETATION OF THE FINDINGS & FURTHER RECOMMENDATIONS

Given these findings, no cardiac therapy is recommended. There are no cardiac contraindications to anesthesia, fluid therapy, vasopressor therapy, or corticosteroids as indicated for further assessment and treatment. If not already performed, baseline thoracic radiographs and blood pressure are recommended. A recheck echocardiogram is recommended in 6 months.

Anesthesia considerations:

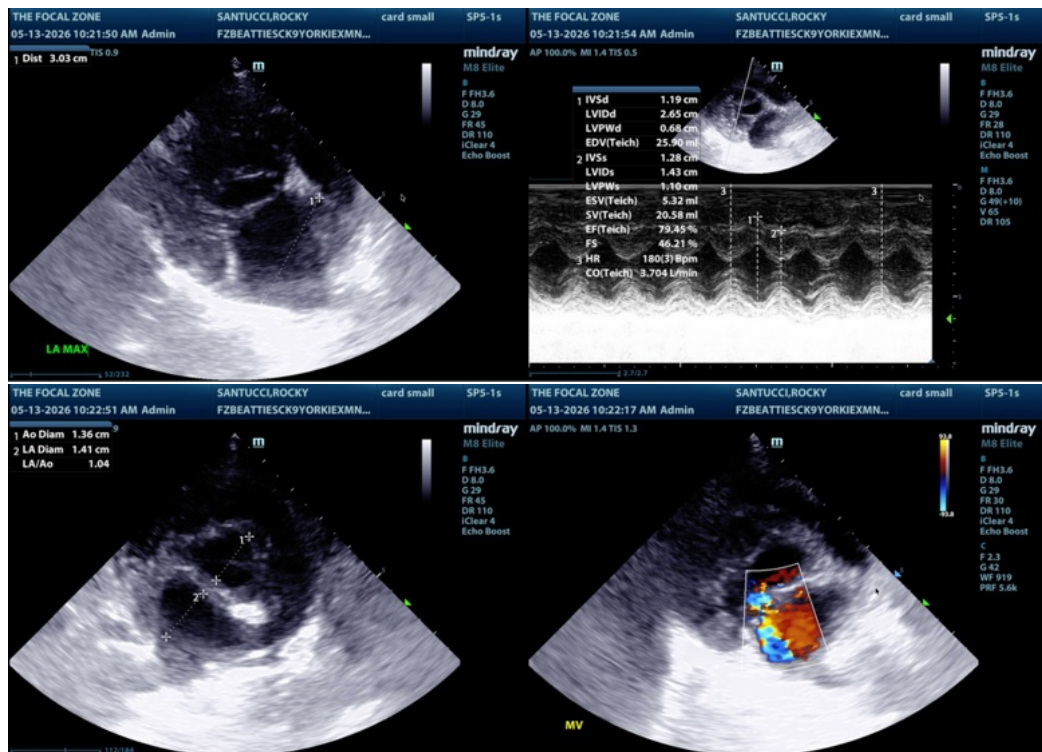
If anesthesia is necessary, alpha-2 agonists, ketamine, high dose acepromazine, and Telazol should be avoided. Fluid therapy during anesthesia should be considered at a conservative rate (e.g., 5 ml/kg/hour) if possible.

Diet:

A high-quality food from Hills, Royal Canin, Science Diet, Eukanuba, Iams, or Purina that is highly palatable with adequate protein and calories for maintaining optimal body condition is reasonable.

Activity:

No special considerations are necessary.





PATIENT

Rocky Santucci

SPECIES

Canine

BREED

Yorkie Cross

SEX

Neutered male

AGE

14 years

WEIGHT

7.7 kg

INTERPRETED BY

Bradley Harris, DVM,
DACVECC, DACVIM
(cardiology)

**IMAGING
PERFORMED BY**

Kelly Reschny

HOSPITAL NAME

BPH Stoney Creek

REFERRING VET

Dr. Ebrahimi

INVOICE

75399

DATE

5/13/26

The information and recommendations provided are based on the images presented by the referring veterinarian/sonographer. No evaluation can be communicated regarding pathology that was not visible in the image/video clips provided.

Thank you for this referral. If the clinical or image interpretation does not parallel your findings or if I can be of any further assistance please contact me.

Bradley Harris, DVM, DACVECC, DACVIM (cardiology)

info@SonoPath.com