



**PATIENT PRESENTING CLINICAL SIGNS**

**PATIENT** Kiwi Mariano  
**SPECIES** Canine  
**BREED** Chihuahua  
**SEX** Spayed female  
**AGE** 12 years  
**WEIGHT** 1.97 kg  
**INTERPRETED BY** Bradley Harris, DVM, DACVECC, DACVIM (cardiology)  
**IMAGING PERFORMED BY** Amanda Stewart  
**HOSPITAL NAME** Southside Animal Clinic London  
**REFERRING VET** Dr. Kovacs-Litman  
**INVOICE** 74341  
**DATE** 4/9/26

**PRESENTING CLINICAL SIGNS**  
 History: Lenticular sclerosis OU. Diffuse sarcopenia. No audible murmur. Thoracic auscultation unremarkable. Numerous missing teeth from prior dental  
 Current Medications: Flovent 125mcg inhaler 1 puff BID for 7d, then 1 puff SID x 7d Theophylline 100mg 1/4 tab BID x 5 day, discontinue awaiting echo, Pimobendan 1.25mg SID, Gabapentin 50mg/mL 0.4mL BID-TID  
 March 28, 2026 - CBC/Chem unremarkable Radiographic Findings Cardiomegaly on thoracic radiographs - no murmur audible Progressive tracheal collapse Diffuse bronchial pattern

**ULTRASONOGRAPHIC EXAMINATION OF THE HEART**

The left atrium is normal in dimension. The left ventricle is normal in dimension with normal systolic function. The right atrium and ventricle are normal in dimension with normal systolic function. The anterior and posterior mitral valve leaflets are thickened and redundant consistent with myxomatous changes, and there is moderate prolapse. There is mild mitral regurgitation identified. The tricuspid valve leaflets are appropriately thin with adequate apposition and intact chordae, with no significant tricuspid regurgitation and no evidence of pulmonary hypertension. The left ventricular outflow tract demonstrated normal laminar flow and the visible aorta is unremarkable. The right ventricular outflow tract assessment revealed normal laminar flow, with appropriate main pulmonary artery diameter and right pulmonary artery distensibility. There is no pulmonic and no aortic valve insufficiency identified. There is no visible pericardial, pleural, or free peritoneal fluid documented. No evidence of hepatic venous congestion is noted. The cardiac chambers, pericardial, and visible extra-cardiac regions were free of masses, spontaneous echo contrast, or thrombi.

CANINE CARDIAC PARAMETERS	Body Weight kg	HR BPM	LAD 4 ch Long	RAD 4 ch Long	La/Ao Heart Base	LVIDd	LVIDs
NORMAL PARAMETER		50-100			<1.6		
PATIENT	1.97 kg	170	1.93	1.11	1.24	1.76	1.27
CANINE CARDIAC PARAMETERS	FS	EPSS	PV V MAX (m/s)	AV V Max (m/sec)	MR Vmax	TR Vmax	RPA distensibility (normal >30%)
NORMAL PARAMETER	28-40	<0.6	0.7-1.6	0.7-1.7	4.5-5.5	< 2.7	
PATIENT	28	NM	0.8	1.0	5.0	NM	51

**ULTRASONOGRAPHIC FINDINGS**

These findings are consistent with degenerative/myxomatous mitral valve disease with minimal to mild hemodynamic effects consistent with ACVIM Stage B1 disease. It is unlikely that any current morbidity is of cardiac origin.



**PATIENT**

Kiwi Mariano

**SPECIES**

Canine

**BREED**

Chihuahua

**SEX**

Spayed female

**AGE**

12 years

**WEIGHT**

1.97 kg

**INTERPRETED BY**

Bradley Harris, DVM,  
 DACVECC, DACVIM  
 (cardiology)

**IMAGING PERFORMED BY**

Amanda Stewart

**HOSPITAL NAME**

Southside Animal Clinic  
 London

**REFERRING VET**

Dr. Kovacs-Litman

**INVOICE**

74341

**DATE**

4/9/26

**INTERPRETATION OF THE FINDINGS & FURTHER RECOMMENDATIONS**

Given these findings, no cardiac therapy is recommended. There are no cardiac contraindications to anesthesia, fluid therapy, vasopressor therapy, or corticosteroids as indicated for further assessment and treatment. If not already performed, baseline thoracic radiographs and blood pressure are recommended. A recheck echocardiogram is recommended in 6 months.

Anesthesia considerations:

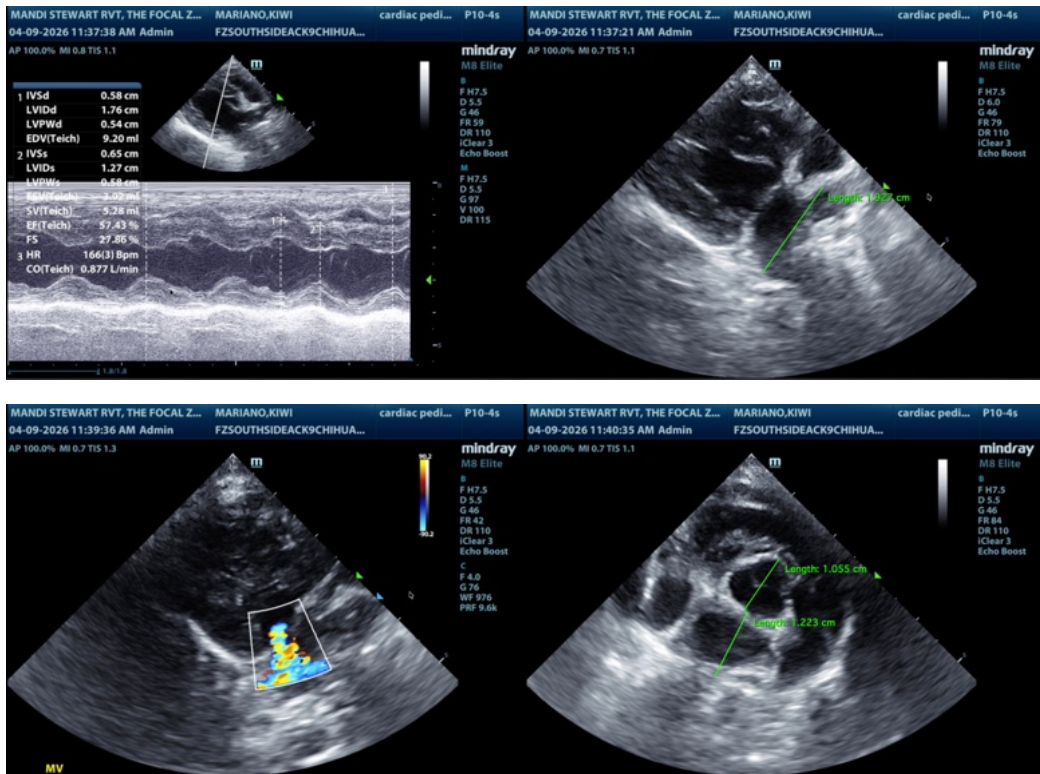
If anesthesia is necessary, alpha-2 agonists, ketamine, high dose acepromazine, and Telazol should be avoided. Fluid therapy during anesthesia should be considered at a conservative rate (e.g., 5 ml/kg/hour) if possible.

Diet:

A high-quality food from Hills, Royal Canin, Science Diet, Eukanuba, Iams, or Purina that is highly palatable with adequate protein and calories for maintaining optimal body condition is reasonable.

Activity:

No special considerations are necessary.



The information and recommendations provided are based on the images presented by the referring veterinarian/sonographer. No evaluation can be communicated regarding pathology that was not visible in the image/video clips provided.

Thank you for this referral. If the clinical or image interpretation does not parallel your findings or if I can be of any further assistance please contact me.



**PATIENT**

Bradley Harris, DVM, DACVECC, DACVIM (cardiology)

Kiwi Mariano

[info@SonoPath.com](mailto:info@SonoPath.com)

**SPECIES**

Canine

**BREED**

Chihuahua

**SEX**

Spayed female

**AGE**

12 years

**WEIGHT**

1.97 kg

**INTERPRETED BY**

Bradley Harris, DVM,  
DACVECC, DACVIM  
(cardiology)

**IMAGING  
PERFORMED BY**

Amanda Stewart

**HOSPITAL NAME**

Southside Animal Clinic  
London

**REFERRING VET**

Dr. Kovacs-Litman

**INVOICE**

74341

**DATE**

4/9/26