



**PATIENT PRESENTING CLINICAL SIGNS**

**PATIENT**  
 Kellie Jodoin

**SPECIES**

Canine

**BREED**

Poodle

**SEX**

Spayed female

**AGE**

9 years

**WEIGHT**

7.1 kg

- Grade 3-4/6 heart murmur - it is possible the cough is secondary to the enlarged heart - I rec cardiac U/S in case medication is warranted - O will consider
- O said that she coughs occ - never brings anything up
- I offered to dispense codeine but O will hold off for now - they liked the liquid hydrocodone better - I rec trying to syringe water in when she is having a coughing episode
- Current Medications None

**ULTRASONOGRAPHIC EXAMINATION OF THE HEART**

The left atrium is normal in dimension. The left ventricle is normal in dimension with normal systolic function. The right atrium and ventricle are normal in dimension with normal systolic function. The anterior and posterior mitral valve leaflets are thickened and redundant consistent with myxomatous changes, and there is no significant prolapse. There is mild to moderate mitral regurgitation identified. The tricuspid valve leaflets are thickened and redundant, with mild tricuspid regurgitation and no evidence of pulmonary hypertension. The left ventricular outflow tract demonstrated normal laminar flow and the visible aorta is unremarkable. The right ventricular outflow tract assessment revealed normal laminar flow, with appropriate main pulmonary artery diameter and right pulmonary artery distensibility. There is no pulmonic and no aortic valve insufficiency identified. There is no visible pericardial, pleural, or free peritoneal fluid documented. No evidence of hepatic venous congestion is noted. The cardiac chambers, pericardial and visible extra-cardiac regions were free of masses, spontaneous echo contrast, or thrombi.

**INTERPRETED BY**

Bradley Harris, DVM,  
 DACVECC, DACVIM  
 (cardiology)

**IMAGING PERFORMED BY**

Amanda Stewart

**HOSPITAL NAME**

Snelgrove VS

**REFERRING VET**

Dr. Ioannnou

CANINE CARDIAC PARAMETERS	Body Weight kg	HR BPM	LAD 4 ch Long	RAD 4 ch Long	La/Ao Heart Base	LVIDd	LVIDs
NORMAL PARAMETER		50-100			<1.6		
PATIENT	7.1 kg	170	2.98	NM	1.33	2.65	1.59
CANINE CARDIAC PARAMETERS	FS	EPSS	PV V MAX (m/s)	AV V Max (m/sec)	MR Vmax	TR Vmax	RPA distensibility (normal >30%)
NORMAL PARAMETER	28-40	<0.6	0.7-1.6	0.7-1.7	4.5-5.5	< 2.7	
PATIENT	40	0.2	1.2	1.1	5.7	NM	33

**INVOICE**

74230

**DATE**

4/7/26

**ECG:**

There is a six-lead ECG available for review. The underlying rhythm is regular at an average rate of 170bpm. The rhythm appears to be sinus in origin with narrow QRS complexes (<70ms). There is no atrial or ventricular ectopy and no conduction delay or block identified. This is most consistent with a normal sinus rhythm.



**PATIENT**

Kellie Jodoin

**SPECIES**

Canine

**BREED**

Poodle

**SEX**

Spayed female

**AGE**

9 years

**WEIGHT**

7.1 kg

**INTERPRETED BY**

Bradley Harris, DVM,  
DACVECC, DACVIM  
(cardiology)

**IMAGING PERFORMED BY**

Amanda Stewart

**HOSPITAL NAME**

Snelgrove VS

**REFERRING VET**

Dr. Ioannou

**INVOICE**

74230

**DATE**

4/7/26

**ULTRASONOGRAPHIC FINDINGS**

These findings are consistent with degenerative/myxomatous mitral valve disease with minimal to mild hemodynamic effects consistent with ACVIM Stage B1 disease. It is unlikely that any current morbidity is of cardiac origin.

**INTERPRETATION OF THE FINDINGS & FURTHER RECOMMENDATIONS**

Given these findings, no cardiac therapy is recommended. There are no cardiac contraindications to anesthesia, fluid therapy, vasopressor therapy, or corticosteroids as indicated for further assessment and treatment. If not already performed, baseline thoracic radiographs and blood pressure are recommended. A recheck echocardiogram is recommended in 6 months.

Anesthesia considerations:

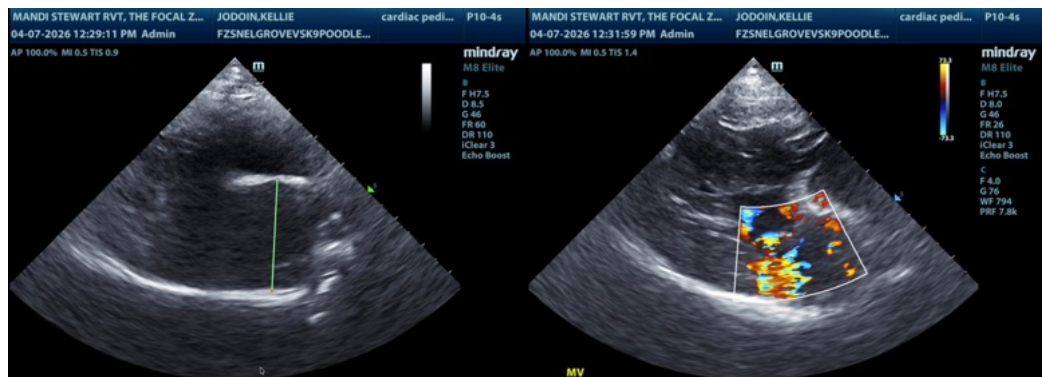
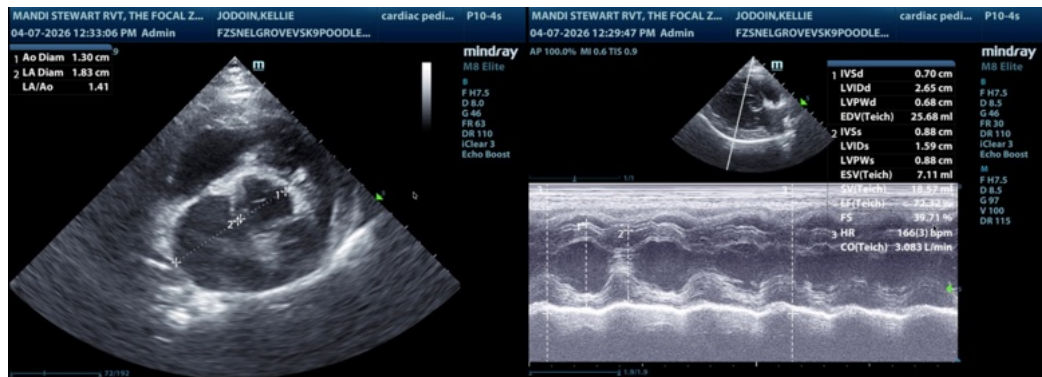
If anesthesia is necessary, alpha-2 agonists, ketamine, high dose acepromazine, and Telazol should be avoided. Fluid therapy during anesthesia should be considered at a conservative rate (e.g., 5 ml/kg/hour) if possible.

Diet:

A high-quality food from Hills, Royal Canin, Science Diet, Eukanuba, Iams, or Purina that is highly palatable with adequate protein and calories for maintaining optimal body condition is reasonable.

Activity:

No special considerations are necessary.





**PATIENT**

Kellie Jodoin

**The information and recommendations provided are based on the images presented by the referring veterinarian/sonographer. No evaluation can be communicated regarding pathology that was not visible in the image/video clips provided.**

**SPECIES**

Canine

Thank you for this referral. If the clinical or image interpretation does not parallel your findings or if I can be of any further assistance please contact me.

**BREED**

Poodle

Bradley Harris, DVM, DACVECC, DACVIM (cardiology)

[info@SonoPath.com](mailto:info@SonoPath.com)

**SEX**

Spayed female

**AGE**

9 years

**WEIGHT**

7.1 kg

**INTERPRETED BY**

Bradley Harris, DVM,  
DACVECC, DACVIM  
(cardiology)

**IMAGING PERFORMED BY**

Amanda Stewart

**HOSPITAL NAME**

Snelgrove VS

**REFERRING VET**

Dr. Ioannou

**INVOICE**

74230

**DATE**

4/7/26