



**PATIENT**

Rufus Lavinge

**SPECIES**

Canine

**BREED**

Pug Cross

**SEX**

Intact male

**AGE**

12 years

**WEIGHT**

19.6 lbs

**INTERPRETED BY**

Bradley Harris, DVM,  
 DACVECC, DACVIM  
 (cardiology)

**IMAGING PERFORMED BY**

Kelly Reschny

**HOSPITAL NAME**

Dog and Cat Clinic of  
 Niagara

**REFERRING VET**

Dr. Snieder

**INVOICE**

75012

**DATE**

4/30/26

**PRESENTING CLINICAL SIGNS**

History: Rufus presents for evaluation of episodes previously diagnosed as seizures that began two months ago, with a total of four events. The episodes are characterized by an initial high-pitched yelp, followed by a limpness, falling onto the side, and stiffness. Movement or shaking is typically absent. Normal events last approximately 40 seconds and are followed by a rapid, full recovery to normal demeanor and activity within 2-3 minutes. Today's episode was abnormal, lasting nearly two minutes, with the tongue observed to be between the teeth and a perceived absence of breathing. The owner performed mouth-to-mouth resuscitation. Recovery was prolonged, and the patient appeared disoriented with crossed eyes and experienced urinary incontinence. The patient has a history of a heart murmur  
 Current Medications Gabapentin 100mg, Denamarin 225mg, Theophylline 100mg

**ULTRASONOGRAPHIC EXAMINATION OF THE HEART**

The left atrium is normal in dimension. The left ventricle is normal in dimension, with normal systolic function. The right atrium and ventricle are normal in dimension, with normal systolic function. The anterior and posterior mitral valve leaflets are appropriately thin with adequate apposition, intact chordae, and there is no significant prolapse. There is no significant mitral regurgitation identified. The tricuspid valve leaflets are appropriately thin with adequate apposition, intact chordae, no significant tricuspid regurgitation and no evidence of pulmonary hypertension. The left ventricular outflow tract demonstrated normal laminar flow and the visible aorta is unremarkable. The right ventricular outflow tract assessment revealed normal laminar flow, with appropriate main pulmonary artery diameter and right pulmonary artery distensibility. There is no pulmonic and no aortic valve insufficiency identified. There is no visible pericardial, pleural, or free peritoneal fluid documented. No evidence of hepatic venous congestion is noted. The cardiac chambers, pericardial and visible extra-cardiac regions were free of masses, spontaneous echo contrast, or thrombi.

CANINE CARDIAC PARAMETERS	Body Weight kg	HR BPM	LAD 4 ch Long	RAD 4 ch Long	La/Ao Heart Base	LVIDd	LVIDs
NORMAL PARAMETER		50-100			<1.6		
PATIENT	8.91 kg	60	3.09	1.82	1.13	2.84	1.57
CANINE CARDIAC PARAMETERS	FS	EPSS	PV V MAX (m/s)	AV V Max (m/sec)	MR Vmax	TR Vmax	RPA distensibility (normal >30%)
NORMAL PARAMETER	28-40	<0.6	0.7-1.6	0.7-1.7	4.5-5.5	< 2.7	
PATIENT	45	0.6	1.4	0.8	4.1	NM	NM

**ULTRASONOGRAPHIC FINDINGS**

These findings are consistent with degenerative/myxomatous mitral valve disease with minimal to mild hemodynamic effects consistent with ACVIM Stage B1 disease. It is unlikely that any current morbidity is of cardiac origin.



**PATIENT**

Rufus Lavinge

**SPECIES**

Canine

**BREED**

Pug Cross

**SEX**

Intact male

**AGE**

12 years

**WEIGHT**

19.6 lbs

**INTERPRETED BY**

Bradley Harris, DVM,  
 DACVECC, DACVIM  
 (cardiology)

**IMAGING PERFORMED BY**

Kelly Reschny

**HOSPITAL NAME**

Dog and Cat Clinic of  
 Niagara

**REFERRING VET**

Dr. Snieder

**INVOICE**

75012

**DATE**

4/30/26

**INTERPRETATION OF THE FINDINGS & FURTHER RECOMMENDATIONS**

Given these findings, no cardiac therapy is recommended. There are no cardiac contraindications to anesthesia, fluid therapy, vasopressor therapy, or corticosteroids as indicated for further assessment and treatment. If not already performed, baseline thoracic radiographs and blood pressure are recommended. A recheck echocardiogram is recommended in 6 months.

Anesthesia considerations:

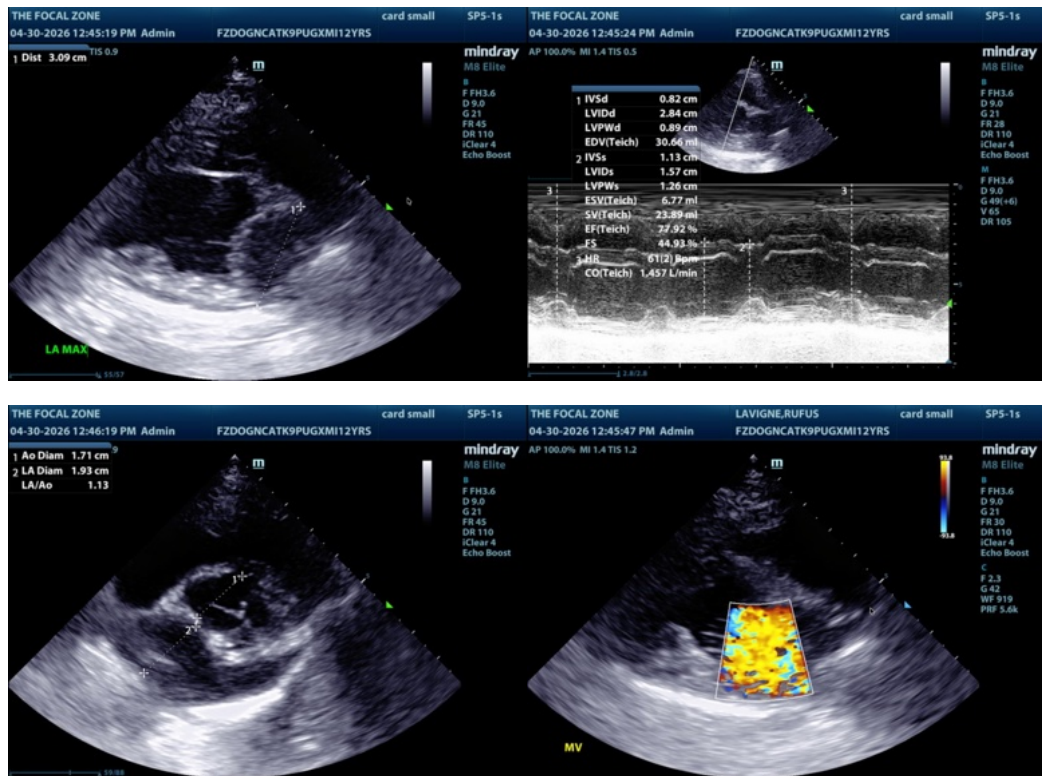
If anesthesia is necessary, alpha-2 agonists, ketamine, high dose acepromazine, and Telazol should be avoided. Fluid therapy during anesthesia should be considered at a conservative rate (e.g., 5 ml/kg/hour) if possible.

Diet:

A high-quality food from Hills, Royal Canin, Science Diet, Eukanuba, Iams, or Purina that is highly palatable with adequate protein and calories for maintaining optimal body condition is reasonable.

Activity:

No special considerations are necessary.



The information and recommendations provided are based on the images presented by the referring veterinarian/sonographer. No evaluation can be communicated regarding pathology that was not visible in the image/video clips provided.

Thank you for this referral. If the clinical or image interpretation does not parallel your findings or if I can be of any further assistance please contact me.



**PATIENT**

Bradley Harris, DVM, DACVECC, DACVIM (cardiology)

Rufus Lavinge

[info@SonoPath.com](mailto:info@SonoPath.com)

**SPECIES**

Canine

**BREED**

Pug Cross

**SEX**

Intact male

**AGE**

12 years

**WEIGHT**

19.6 lbs

**INTERPRETED BY**

Bradley Harris, DVM,  
DACVECC, DACVIM  
(cardiology)

**IMAGING  
PERFORMED BY**

Kelly Reschny

**HOSPITAL NAME**

Dog and Cat Clinic of  
Niagara

**REFERRING VET**

Dr. Snieder

**INVOICE**

75012

**DATE**

4/30/26