

**PATIENT**

Nova Elliot

**SPECIES**

Feline

**BREED**

Domestic Shorthair

**SEX**

Spayed female

**AGE**

12 years

**WEIGHT**

3 kg

**INTERPRETED BY**

Bradley Harris, DVM,  
 DACVECC, DACVIM  
 (cardiology)

**IMAGING PERFORMED BY**

Kelly Reschny

**HOSPITAL NAME**

St Catharines AH

**REFERRING VET**

Dr. Collado-Torres

**INVOICE**

74718

**DATE**

4/22/26

**PRESENTING CLINICAL SIGNS**

History: A low-grade heart murmur was auscultated; it was not audible with q heartbeat. No arrhythmias were noted, grade 2/6 HM. Nova occasionally brings up a small amount of vomit. Nausea seems to recur towards the end of the 3-day dosing interval for her appetite stimulant.

Current Medications: - Mirataz (transdermal Mirtazapine) Gabapentin and Trazodone: calming purposes.

Abnormal PE/Chem/CBC/UA Results: CBC is within normal limits, this includes the red & white blood cells and the platelets. In other news, her thyroid values (TT4) are also within normal limits (on the high end of normal limits with a value of 43.8 nmol/L and the reference range is between 10 and 60 nmol/L).

**ULTRASONOGRAPHIC EXAMINATION OF THE HEART**

The left atrium is normal in dimension. There are no distinct left atrial thrombi/clots or spontaneous echo contrast appreciated. The left ventricle is normal in dimension as well as wall thickness, and no evidence of restriction. Left ventricular systolic function is normal, with adequate contractility. The right atrium and ventricle are subjectively normal in dimension and systolic function. The anterior and posterior mitral and tricuspid valve leaflets presented normal linear structure, extension in systole, and union in diastole without regurgitation. There is no evidence of systolic anterior mitral valve motion documented. The left ventricular outflow tract demonstrated normal laminar flow and subjective structural valvular integrity. The visible aorta is unremarkable. Pulmonary outflow tract assessment revealed normal valve structure, laminar flow, and appropriate diameter and distensibility. There is no evidence of pulmonary hypertension documented. There is no visible pericardial, pleural, or free peritoneal fluid noted. Diffuse B-lines are noted within the pulmonary parenchyma.

FELINE CARDIAC PARAMETERS	BODY WEIGHT (kg)	HR (BPM)	IVSd (cm)	LVIDd (cm)	LVWd (cm)	FS (%)	EF (%)
NORMAL PARAMETER	-----	150-240	0.3-0.6	1.0-2.1	0.25-0.6	35-67	80-100
PATIENT	3.0 kg	150	0.51	1.34	0.52	67	95
FELINE CARDIAC PARAMETERS	LA/AO (M-mode)	LA/AO HEART BASE (Sisson)	LAD LA MAX 4 Chamber		LVOT VEL. (m/s)	RVOT VEL. (m/s)	IVRT (m/)
NORMAL PARAMETER	<1.5	1.6	0.7-1.7		<1.6	<1.3	40-60
PATIENT	1.17	1.1	NM		0.7	1.1	NM
Adapted from June Boon, Veterinary Echocardiography, 1998 Sisson D et al. JVIM 1991; 5: 232, Jacobs et al. Am J Vet Res 1985; 46:1705							

**ULTRASONOGRAPHIC FINDINGS**

These findings are consistent with an essentially normal echocardiogram. Any murmur auscultated will be considered functional in origin. A cardiac cause of the pulmonary pathology is considered unlikely, however, if diuretics have been administered recently, this cannot be completely ruled out.



**PATIENT**

Nova Elliot

**SPECIES**

Feline

**BREED**

Domestic Shorthair

**SEX**

Spayed female

**AGE**

12 years

**WEIGHT**

3 kg

**INTERPRETED BY**

Bradley Harris, DVM,  
 DACVECC, DACVIM  
 (cardiology)

**IMAGING PERFORMED BY**

Kelly Reschny

**HOSPITAL NAME**

St Catharines AH

**REFERRING VET**

Dr. Collado-Torres

**INVOICE**

74718

**DATE**

4/22/26

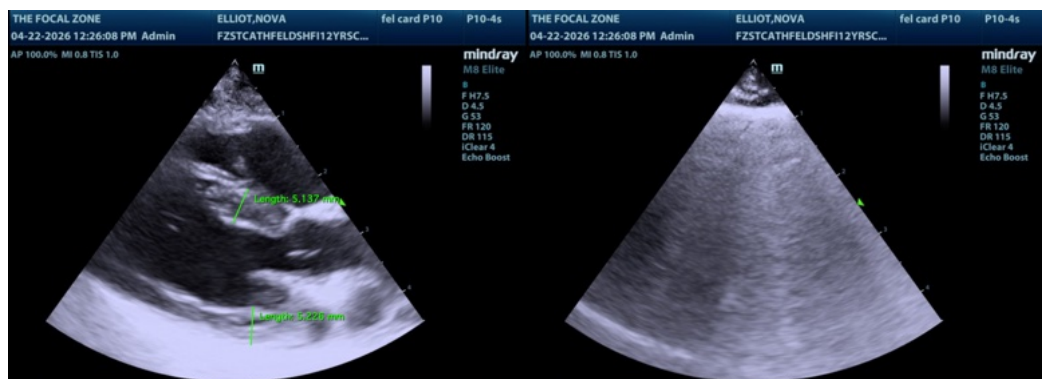
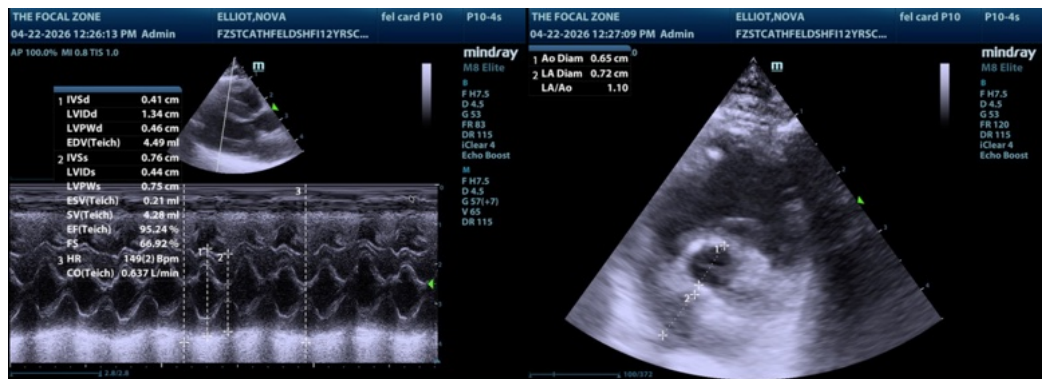
**INTERPRETATION OF THE FINDINGS & FURTHER RECOMMENDATIONS**

Given these findings, no cardiac therapy is recommended. There are no cardiac contraindications to corticosteroids or fluid therapy as indicated for further treatment. Thoracic radiographs are indicated. No specific recheck echocardiogram is recommended.

Anesthesia considerations:  
 No special cardiac considerations are necessary

Diet:  
 No special considerations are necessary. Any high-quality food from Hills, Royal Canin, Science Diet, Eukanuba, Iams, or Purina is reasonable.

Activity:  
 No special considerations are necessary.



The information and recommendations provided are based on the images presented by the referring veterinarian/sonographer. No evaluation can be communicated regarding pathology that was not visible in the image/video clips provided.

Thank you for this referral. If the clinical or image interpretation does not parallel your findings or if I can be of any further assistance please contact me.

Bradley Harris, DVM, DACVECC, DACVIM (cardiology)

[info@SonoPath.com](mailto:info@SonoPath.com)