



PATIENT

Tavie Purrfect
Companions Rescue

SPECIES

Feline

BREED

Domestic Medium Hair

SEX

Intact female

AGE

12 months

WEIGHT

3.4 kg

INTERPRETED BY

Bradley Harris, DVM,
DACVECC, DACVIM
(cardiology)

IMAGING PERFORMED BY

Crystal Hill

HOSPITAL NAME

Queensway VH

REFERRING VET

Dr. Afifi

INVOICE

74685

DATE

4/21/26

PRESENTING CLINICAL SIGNS

History: Has turned blue under sedation two times at two different clinics when attempting GA for Spay surgery. Noted bradycardia. No meds.

ULTRASONOGRAPHIC EXAMINATION OF THE HEART

The left atrium is normal in dimension. There are no distinct left atrial thrombi/clots or spontaneous echo contrast appreciated. The left ventricle is normal in dimension as well as wall thickness, and no evidence of restriction. Left ventricular systolic function is normal, with adequate contractility. The right atrium and ventricle are subjectively prominent with adequate systolic function. The anterior and posterior mitral and tricuspid valve leaflets presented normal linear structure, extension in systole, and union in diastole without regurgitation. There is no evidence of systolic anterior mitral valve motion documented. The left ventricular outflow tract demonstrated normal laminar flow and subjective structural valvular integrity. The visible aorta is unremarkable. Pulmonary outflow tract assessment revealed normal valve structure, laminar flow, and appropriate diameter and distensibility. There is no evidence of pulmonary hypertension documented. There is no visible pericardial, pleural, or free peritoneal fluid noted.

FELINE CARDIAC PARAMETERS	BODY WEIGHT (kg)	HR (BPM)	IVSd (cm)	LVIDd (cm)	LVWd (cm)	FS (%)	EF (%)
NORMAL PARAMETER	-----	150-240	0.3-0.6	1.0-2.1	0.25-0.6	35-67	80-100
PATIENT	3.4 kg	180	0.35	1.6	0.35	40	74
FELINE CARDIAC PARAMETERS	LA/AO (M-mode)	LA/AO HEART BASE (Sisson)	LAD LA MAX 4 Chamber	LVOT VEL. (m/s)	RVOT VEL. (m/s)	IVRT (m/)	
NORMAL PARAMETER	<1.5	1.6	0.7-1.7	<1.6	<1.3	40-60	
PATIENT	1.9	1.61	1.23	0.6	1.0	NM	
Adapted from June Boon, Veterinary Echocardiography, 1998 Sisson D et al. JVIM 1991; 5: 232, Jacobs et al. Am J Vet Res 1985; 46:1705							

ULTRASONOGRAPHIC FINDINGS

These findings are consistent with an essentially normal echocardiogram. However, given the history, a right to left shunt cannot be completely excluded. The absence of significant tricuspid regurgitation makes evaluation of pulmonary hypertension a challenge, but the subjectively enlarged right atrium and ventricle make it a concern.

INTERPRETATION OF THE FINDINGS & FURTHER RECOMMENDATIONS

Given these findings, no cardiac therapy is recommended. Consideration should be given to referral to a veterinary cardiologist for a contrast bubble study for further evaluation of a potential right to left



PATIENT

Tavie Purrfect
 Companions Rescue

SPECIES

Feline

BREED

Domestic Medium Hair

SEX

Intact female

AGE

12 months

WEIGHT

3.4 kg

INTERPRETED BY

Bradley Harris, DVM,
 DACVECC, DACVIM
 (cardiology)

IMAGING PERFORMED BY

Crystal Hill

HOSPITAL NAME

Queensway VH

REFERRING VET

Dr. Afifi

INVOICE

74685

DATE

4/21/26

shunt. In the meantime, there are no cardiac contraindications to corticosteroids or fluid therapy as indicated for further treatment.

Anesthesia considerations:

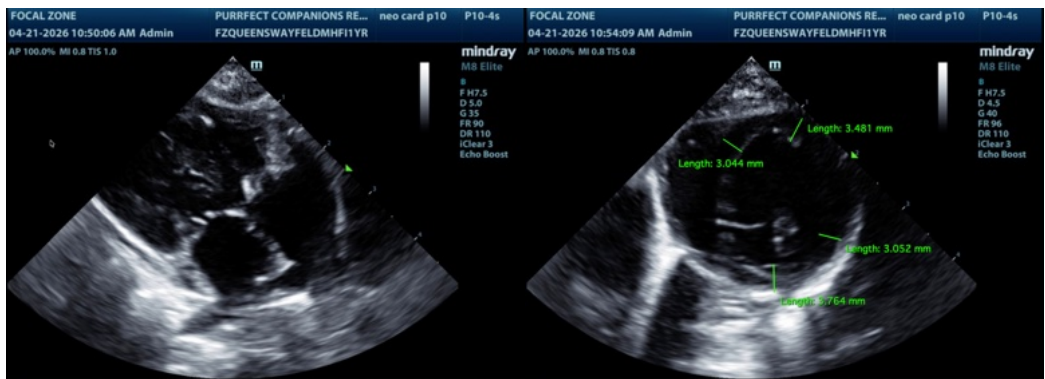
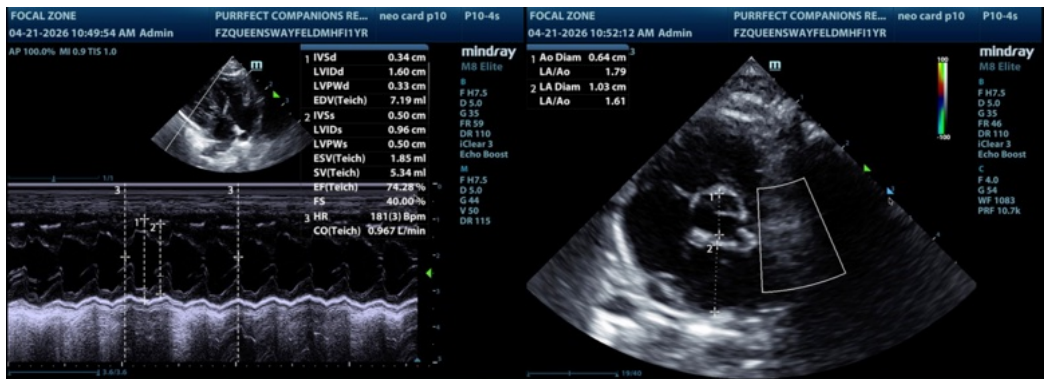
Anesthesia should be avoided until a right to left shunt is either confirmed or ruled out.

Diet:

No special considerations are necessary. Any high-quality food from Hills, Royal Canin, Science Diet, Eukanuba, Iams, or Purina is reasonable.

Activity:

No special considerations are necessary.



The information and recommendations provided are based on the images presented by the referring veterinarian/sonographer. No evaluation can be communicated regarding pathology that was not visible in the image/video clips provided.

Thank you for this referral. If the clinical or image interpretation does not parallel your findings or if I can be of any further assistance please contact me.

Bradley Harris, DVM, DACVECC, DACVIM (cardiology)

info@SonoPath.com