



PATIENT

Sophia Silveira

SPECIES

Canine

BREED

American Bulldog

SEX

Spayed female

AGE

5 years

WEIGHT

30.5 kg

INTERPRETED BY

Bradley Harris, DVM,
 DACVECC, DACVIM
 (cardiology)

IMAGING PERFORMED BY

Crystal Hill

HOSPITAL NAME

East Credit VH

REFERRING VET

Dr. Webster

INVOICE

74618

DATE

4/20/26

PRESENTING CLINICAL SIGNS

History: New heart murmur first noted Feb 12, 26. Grade 1-2/6 cranial left chest, normal rhythm. Owner was feeding a grain free diet but has transitioned to a grain inclusive diet. Meds - Nexgard Spectra monthly
 Abnormal PE/Chem/CBC/UA Results: Please see attached recent lab results

ULTRASONOGRAPHIC EXAMINATION OF THE HEART

The left atrium is normal in dimension. The left ventricle is normal in dimension with normal systolic function. The right atrium and ventricle are normal in dimension with normal systolic function. The anterior and posterior mitral valve leaflets are appropriately thin with adequate apposition and intact chordae, and there is no significant prolapse. There is no significant mitral regurgitation identified. The tricuspid valve leaflets are appropriately thin with adequate apposition and intact chordae, with trivial tricuspid regurgitation and no evidence of pulmonary hypertension. The left ventricular outflow tract demonstrates normal laminar flow, and the visible aorta is unremarkable. The right ventricular outflow tract assessment reveals normal laminar flow with appropriate main pulmonary artery diameter and right pulmonary artery distensibility. There is no pulmonic and no aortic valve insufficiency identified. There is no visible pericardial, pleural, or free peritoneal fluid documented. No evidence of hepatic venous congestion is noted. The cardiac chambers, pericardial, and visible extra-cardiac regions are free of masses, spontaneous echo contrast, or thrombi.

CANINE CARDIAC PARAMETERS	Body Weight kg	HR BPM	LAD 4 ch Long	RAD 4 ch Long	La/Ao Heart Base	LVIDd	LVIDs
NORMAL PARAMETER		50-100			<1.6		
PATIENT	30.5 kg	130	3.95	3.14	1.24	4.0	2.62
CANINE CARDIAC PARAMETERS	FS	EPSS	PV V MAX (m/s)	AV V Max (m/sec)	MR Vmax	TR Vmax	RPA distensibility (normal >30%)
NORMAL PARAMETER	28-40	<0.6	0.7-1.6	0.7-1.7	4.5-5.5	< 2.7	
PATIENT	35	0.4	1.8	2.4	Not present	2.5	42

ULTRASONOGRAPHIC FINDINGS

These findings are consistent with an essentially normal echocardiogram. Any murmur will be considered functional in origin (dynamic left and right ventricular outflow tracts). No cardiac cause of the morbidity is identified.



PATIENT

Sophia Silveira

SPECIES

Canine

BREED

American Bulldog

SEX

Spayed female

AGE

5 years

WEIGHT

30.5 kg

INTERPRETED BY

Bradley Harris, DVM,
 DACVECC, DACVIM
 (cardiology)

IMAGING PERFORMED BY

Crystal Hill

HOSPITAL NAME

East Credit VH

REFERRING VET

Dr. Webster

INVOICE

74618

DATE

4/20/26

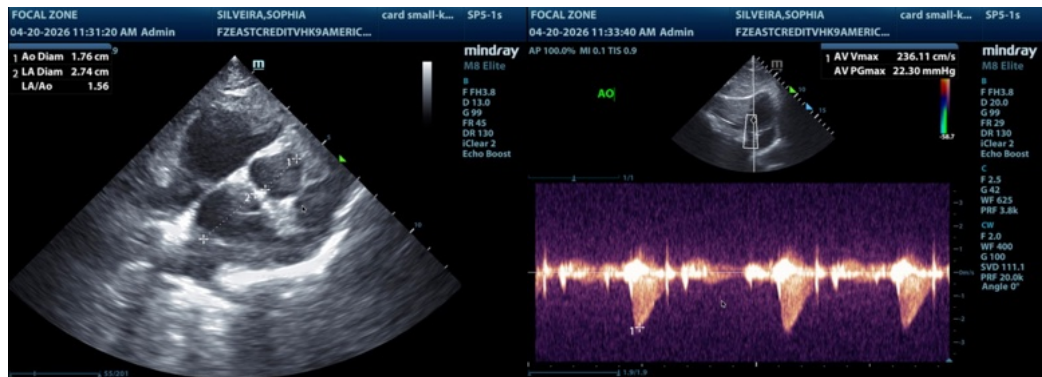
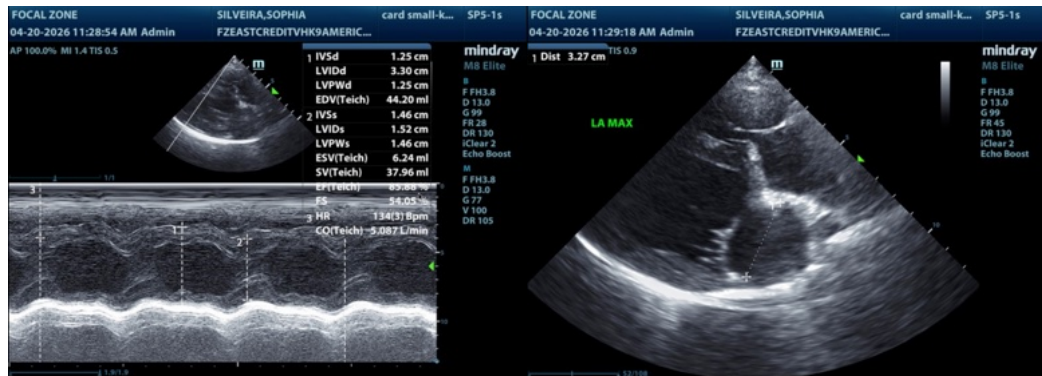
INTERPRETATION OF THE FINDINGS & FURTHER RECOMMENDATIONS

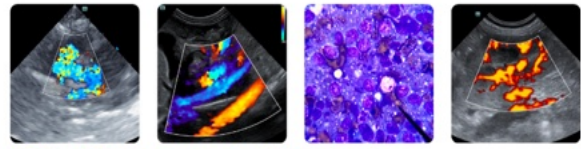
Given these findings, no cardiac therapy is recommended. There are no cardiac contraindications to fluid therapy or corticosteroid therapy, as indicated for further assessment and treatment. No specific cardiac recheck is recommended unless a murmur or clinical signs of heart disease develop.

Anesthesia considerations:
 No special considerations are necessary.

Diet:
 No special considerations are necessary. Any high-quality food from Hills, Royal Canin, Science Diet, Eukanuba, Iams, or Purina is reasonable.

Activity:
 No special considerations are necessary.





PATIENT

Sophia Silveira

SPECIES

Canine

BREED

American Bulldog

SEX

Spayed female

AGE

5 years

WEIGHT

30.5 kg

INTERPRETED BY

Bradley Harris, DVM,
DACVECC, DACVIM
(cardiology)

IMAGING PERFORMED BY

Crystal Hill

HOSPITAL NAME

East Credit VH

REFERRING VET

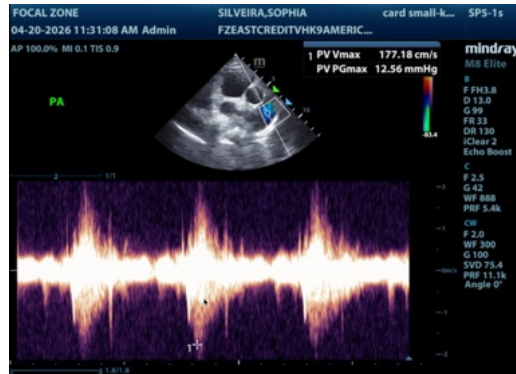
Dr. Webster

INVOICE

74618

DATE

4/20/26



The information and recommendations provided are based on the images presented by the referring veterinarian/sonographer. No evaluation can be communicated regarding pathology that was not visible in the image/video clips provided.

Thank you for this referral. If the clinical or image interpretation does not parallel your findings or if I can be of any further assistance please contact me.

Bradley Harris, DVM, DACVECC, DACVIM (cardiology)

info@SonoPath.com