



PATIENT

Manny Elderdog
 Canada

SPECIES

Canine

BREED

Jack Russell Terrier
 Cross

SEX

Neutered male

AGE

11 years

WEIGHT

7.9 kg

INTERPRETED BY

Bradley Harris, DVM,
 DACVECC, DACVIM
 (cardiology)

IMAGING PERFORMED BY

Kelly Reschny

HOSPITAL NAME

Parkside AH

REFERRING VET

Dr. Zek

INVOICE

73988

DATE

4/1/26

PRESENTING CLINICAL SIGNS

- Coughing after walking and during night time has loud breathing sound. Heart murmur I-II/VI
- Current Medications Cytopoint
- Radiographic Findings There is mild interstitial opacification of the lungs and thickening of the bronchial walls. These findings are consistent with bronchitis. Normal variation or artifact due to digital enhancement cannot be definitively ruled out. Differential diagnoses for a bronchial pattern are primarily inflammatory and include chronic bronchitis, viral/infectious tracheobronchitis, eosinophilic infiltrates, parasitic infections, allergenic stimulation, inhaled irritant, or (less likely) bronchopneumonia. Dynamic tracheal collapse, tracheitis or laryngitis cannot be definitively ruled out. The cardiac silhouette appears normal in size and shape with no evidence of heart failure. Primary consideration would be given to compensated cardiac disease in light of the clinical history.

ULTRASONOGRAPHIC EXAMINATION OF THE HEART

The left atrium is normal in dimension. The left ventricle is normal in dimension, with normal systolic function. The right atrium and ventricle are normal in dimension, with normal systolic function. The anterior and posterior mitral valve leaflets are thickened and redundant consistent with myxomatous changes, and there is no significant prolapse. There is mild mitral regurgitation identified. The tricuspid valve leaflets are thickened and redundant, with mild tricuspid regurgitation and no evidence of pulmonary hypertension. The left ventricular outflow tract demonstrated normal laminar flow and the visible aorta is unremarkable. The right ventricular outflow tract assessment revealed normal laminar flow, with appropriate main pulmonary artery diameter and right pulmonary artery distensibility. There is no pulmonic and no aortic valve insufficiency identified. There is no visible pericardial, pleural, or free peritoneal fluid documented. No evidence of hepatic venous congestion is noted. The cardiac chambers, pericardial and visible extra-cardiac regions were free of masses, spontaneous echo contrast, or thrombi.

CANINE CARDIAC PARAMETERS	Body Weight kg	HR BPM	LAD 4 ch Long	RAD 4 ch Long	La/Ao Heart Base	LVIDd	LVIDs
NORMAL PARAMETER		50-100			<1.6		
PATIENT	7.9 kg	90	3.26	NM	1.25	2.4	1.5
CANINE CARDIAC PARAMETERS	FS	EPSS	PV V MAX (m/s)	AV V Max (m/sec)	MR Vmax	TR Vmax	RPA distensibility (normal >30%)
NORMAL PARAMETER	28-40	<0.6	0.7-1.6	0.7-1.7	4.5-5.5	< 2.7	
PATIENT	38	0.2	1.0	1.0	NM	3.0	NM

ECG:

There is a six-lead ECG available for review. The underlying rhythm is regular. The rhythm appears to be sinus in origin with narrow QRS complexes (<70ms). There is no atrial or ventricular ectopy and no conduction delay or block identified. This is most consistent with a normal sinus rhythm.



PATIENT

Manny Elderdog
 Canada

SPECIES

Canine

BREED

Jack Russell Terrier
 Cross

SEX

Neutered male

AGE

11 years

WEIGHT

7.9 kg

INTERPRETED BY

Bradley Harris, DVM,
 DACVECC, DACVIM
 (cardiology)

IMAGING PERFORMED BY

Kelly Reschny

HOSPITAL NAME

Parkside AH

REFERRING VET

Dr. Zek

INVOICE

73988

DATE

4/1/26

ULTRASONOGRAPHIC FINDINGS

These findings are consistent with degenerative/myxomatous mitral valve disease with minimal to mild hemodynamic effects consistent with ACVIM Stage B1 disease. It is unlikely that any current morbidity is of cardiac origin.

INTERPRETATION OF THE FINDINGS & FURTHER RECOMMENDATIONS

Given these findings, no cardiac therapy is recommended. There are no cardiac contraindications to anesthesia, fluid therapy, vasopressor therapy, or corticosteroids as indicated for further assessment and treatment. If not already performed, baseline thoracic radiographs and blood pressure are recommended. A recheck echocardiogram is recommended in 6 months.

Anesthesia considerations:

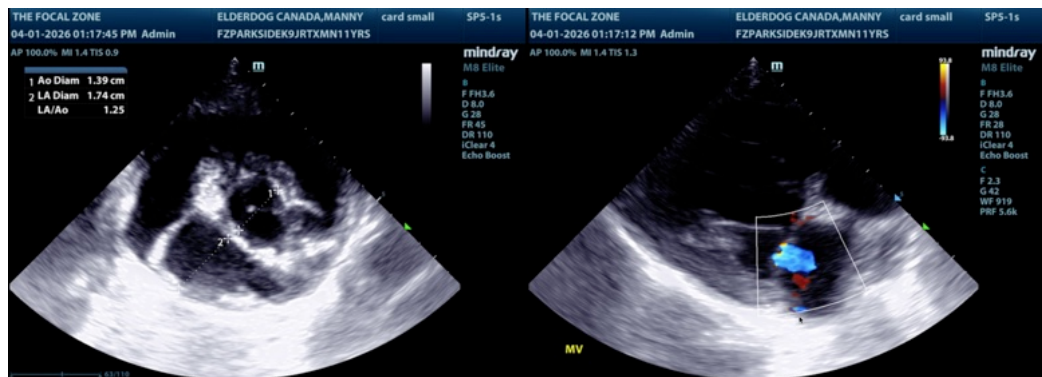
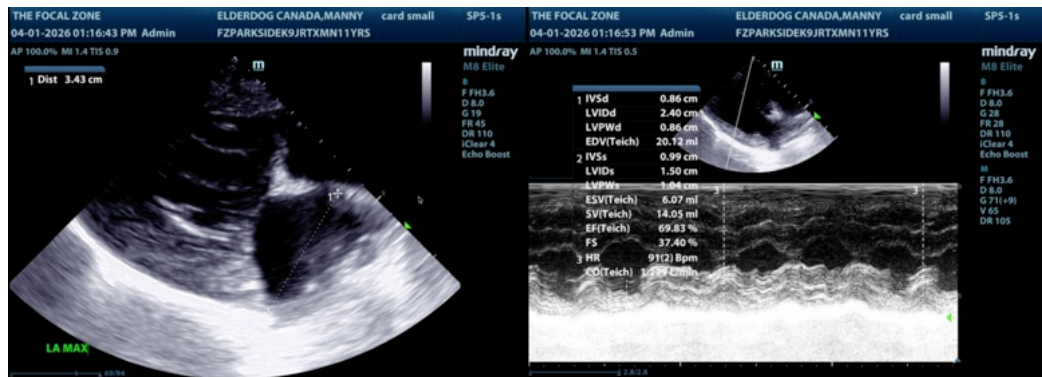
If anesthesia is necessary, alpha-2 agonists, ketamine, high dose acepromazine, and Telazol should be avoided. Fluid therapy during anesthesia should be considered at a conservative rate (e.g., 5 ml/kg/hour) if possible.

Diet:

A high-quality food from Hills, Royal Canin, Science Diet, Eukanuba, Iams, or Purina that is highly palatable with adequate protein and calories for maintaining optimal body condition is reasonable.

Activity:

No special considerations are necessary.





PATIENT

Manny Elderdog
Canada

SPECIES

Canine

BREED

Jack Russell Terrier
Cross

SEX

Neutered male

AGE

11 years

WEIGHT

7.9 kg

INTERPRETED BY

Bradley Harris, DVM,
DACVECC, DACVIM
(cardiology)

**IMAGING
PERFORMED BY**

Kelly Reschny

HOSPITAL NAME

Parkside AH

REFERRING VET

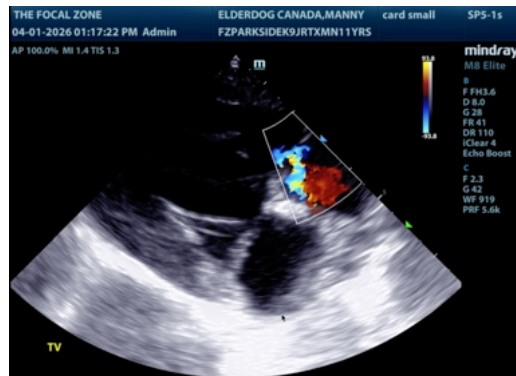
Dr. Zek

INVOICE

73988

DATE

4/1/26



The information and recommendations provided are based on the images presented by the referring veterinarian/sonographer. No evaluation can be communicated regarding pathology that was not visible in the image/video clips provided.

Thank you for this referral. If the clinical or image interpretation does not parallel your findings or if I can be of any further assistance please contact me.

Bradley Harris, DVM, DACVECC, DACVIM (cardiology)

info@SonoPath.com