

PATIENT

Oreo Mencil

SPECIES

Feline

BREED

Domestic Shorthair

SEX

Spayed female

AGE

5 months

WEIGHT

1.54 kg

INTERPRETED BY

Bradley Harris, DVM,
 DACVECC, DACVIM
 (cardiology)

IMAGING PERFORMED BY

Amanda Stewart

HOSPITAL NAME

Hawkins AH

REFERRING VET

Dr. Rutledge

INVOICE

69140

DATE

11/26/25

PRESENTING CLINICAL SIGNS

History: Failure to thrive. Intermittent but increase in tachycardia, systolic hm 2-3/6, neuro signs/ataxia/incontinence/losing weight Current Medications lactulose 0.5ml TID

Abnormal PE/Chem/CBC/UA Results: FELv/FIV/corona NEG on PCR, Pro BNP normal. Normal pre/post bile acids, m1 monocytosis, m1 decrease MCV, mild decrease Creat Urine: Normal clear, yellow. B1 +, PH 6.0, prot +, odd RBC, epithelial cell, odd hyaline cast, SG- >1.050 See attached ECG and bloodwork

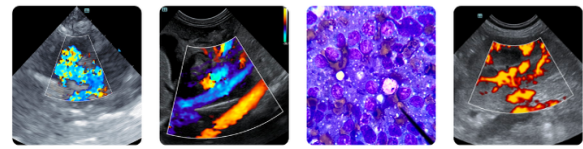
ULTRASONOGRAPHIC EXAMINATION OF THE HEART

The left atrium is normal in dimension. There are no distinct left atrial thrombi/clots or spontaneous echo contrast appreciated. The left ventricle is normal in dimension as well as wall thickness, and no evidence of restriction. Left ventricular systolic function is normal, with adequate contractility. The right atrium and ventricle are subjectively normal in dimension and systolic function. The anterior and posterior mitral and tricuspid valve leaflets presented normal linear structure, extension in systole, and union in diastole without regurgitation. There is no evidence of systolic anterior mitral valve motion documented. The left ventricular outflow tract demonstrated normal laminar flow and subjective structural valvular integrity. The visible aorta is unremarkable. Pulmonary outflow tract assessment revealed normal valve structure, laminar flow, and appropriate diameter and distensibility. There is no evidence of pulmonary hypertension documented. There is no visible pericardial, pleural, or free peritoneal fluid noted.

FELINE CARDIAC PARAMETERS	BODY WEIGHT (kg)	HR (BPM)	IVSd (cm)	LVIDd (cm)	LVWd (cm)	FS (%)	EF (%)
NORMAL PARAMETER	-----	150-240	0.3-0.6	1.0-2.1	0.25-0.6	35-67	80-100
PATIENT	1.54 kg	180	0.41	0.79	0.33	35	70
FELINE CARDIAC PARAMETERS	LA/AO (M-mode)	LA/AO HEART BASE (Sisson)	LAD LA MAX 4 Chamber		LVOT VEL. (m/s)	RVOT VEL. (m/s)	IVRT (m/)
NORMAL PARAMETER	<1.5	1.6	0.7-1.7		<1.6	<1.3	40-60
PATIENT	1.23	1.23	1.04		0.6	1.1	NM
Adapted from June Boon, Veterinary Echocardiography, 1998 Sisson D et al. JVIM 1991; 5: 232, Jacobs et al. Am J Vet Res 1985; 46:1705							

ECG:

There is a six-lead ECG with mild to moderate baseline artifact available for review. The underlying rhythm is regular at an average rate of 180bpm. The rhythm appears to be sinus in origin with narrow QRS complexes (<40ms). There is no atrial or ventricular ectopy and no conduction delay or block identified. This is most consistent with a normal sinus rhythm.



PATIENT

Oreo Mencil

SPECIES

Feline

BREED

Domestic Shorthair

SEX

Spayed female

AGE

5 months

WEIGHT

1.54 kg

INTERPRETED BY

Bradley Harris, DVM,
 DACVECC, DACVIM
 (cardiology)

IMAGING PERFORMED BY

Amanda Stewart

HOSPITAL NAME

Hawkins AH

REFERRING VET

Dr. Rutledge

INVOICE

69140

DATE

11/26/25

ULTRASONOGRAPHIC FINDINGS

These findings are consistent with an essentially normal echocardiogram. Any murmur auscultated will be considered functional in origin.

INTERPRETATION OF THE FINDINGS & FURTHER RECOMMENDATIONS

Given these findings, no cardiac therapy is recommended. There are no cardiac contraindications to corticosteroids or fluid therapy as indicated for further treatment. No specific recheck echocardiogram is recommended.

Anesthesia considerations:

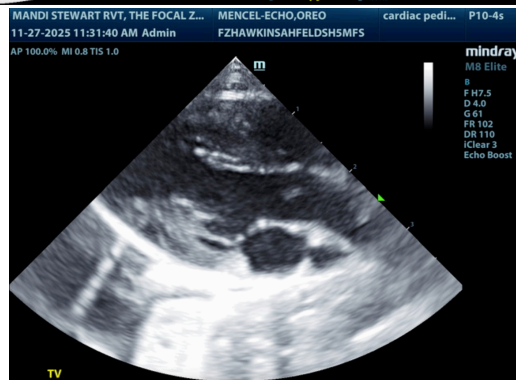
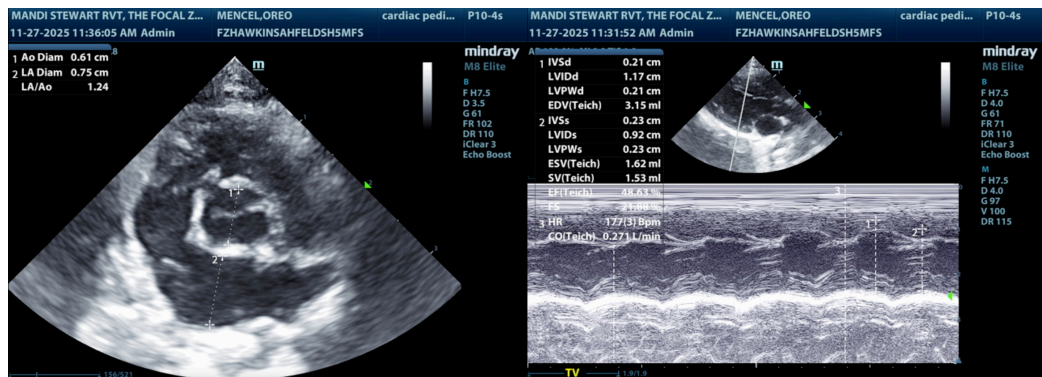
No special cardiac considerations are necessary

Diet:

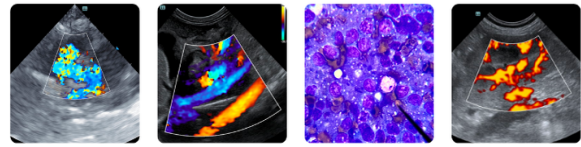
No special considerations are necessary. Any high-quality food from Hills, Royal Canin, Science Diet, Eukanuba, Iams, or Purina is reasonable.

Activity:

No special considerations are necessary.



The information and recommendations provided are based on the images presented by the referring veterinarian/sonographer. No evaluation can be communicated regarding pathology that was not visible in the image/video clips provided.



PATIENT

Oreo Mencil

SPECIES

Feline

BREED

Domestic Shorthair

SEX

Spayed female

AGE

5 months

WEIGHT

1.54 kg

INTERPRETED BY

Bradley Harris, DVM,
DACVECC, DACVIM
(cardiology)

**IMAGING
PERFORMED BY**

Amanda Stewart

HOSPITAL NAME

Hawkins AH

REFERRING VET

Dr. Rutledge

INVOICE

69140

DATE

11/26/25

Thank you for this referral. If the clinical or image interpretation does not parallel your findings or if I can be of any further assistance please contact me.

Bradley Harris, DVM, DACVECC, DACVIM (cardiology)

info@SonoPath.com