



**PATIENT PRESENTING CLINICAL SIGNS**

**Diesel Smith** History: P presented for recheck echo- for the past few days P has been coughing a lot, wet cough with occasional white foam

**SPECIES** Current meds- Pimobendan 10mg 1 PO am and 1/2 PM, Benazepril 10mg 1.5 tab SID, Fluoxetine 20mg 2 PO SID

Canine

**BREED ULTRASONOGRAPHIC EXAMINATION OF THE HEART**

**Boxer** The left atrium is moderately enlarged. The left ventricle is severely enlarged, with severely reduced systolic function. The right atrium and ventricle are normal in dimension, with normal systolic function. The anterior and posterior mitral valve leaflets are mildly thickened, but do not completely appose during systole due to the annular dilation, and there is no significant prolapse. There is mild to moderate mitral regurgitation identified. The tricuspid valve leaflets are appropriately thin with adequate apposition, intact chordae, with mild tricuspid regurgitation and no evidence of pulmonary hypertension. The left ventricular outflow tract demonstrated severely turbulent flow and the aortic valve appears thickened with no overt vegetative lesion noted. The right ventricular outflow tract assessment revealed normal laminar flow, with appropriate main pulmonary artery diameter and right pulmonary artery distensibility. There is no pulmonic and severe aortic valve insufficiency identified. There is no visible pericardial, pleural, or free peritoneal fluid documented. No evidence of hepatic venous congestion is noted. There is a small hyperechoic mass at the heart base in the periaortic region. It is not currently compromising pulmonary vasculature or atrial filling at this time. The cardiac chambers, pericardial and visible extra-cardiac regions were free of spontaneous echo contrast, or thrombi.

**INTERPRETED BY**

Bradley Harris, DVM, DACVECC, DACVIM (cardiology)

**IMAGING PERFORMED BY**

Kathleen Byrnes

**HOSPITAL NAME**

Animal Clinic Madison Mayodan

**REFERRING VET**

Dr. McKinlay

CANINE CARDIAC PARAMETERS	Body Weight kg	HR BPM	LAD 4 ch Long	RAD 4 ch Long	La/Ao Heart Base	LVIDd	LVIDs
NORMAL PARAMETER		50-100			<1.6		
PATIENT	30.0 kg	140	5.6	3.66	1.65	6.78	4.52
CANINE CARDIAC PARAMETERS	FS	EPSS	PV V MAX (m/s)	AV V Max (m/sec)	MR Vmax	TR Vmax	RPA distensibility (normal >30%)
NORMAL PARAMETER	28-40	<0.6	0.7-1.6	0.7-1.7	4.5-5.5	< 2.7	
PATIENT	33	1.0	1.0	4.4	5.8	2.6	30

**INVOICE ULTRASONOGRAPHIC FINDINGS**

**77947** These findings identify reduced left ventricular function in the setting of an enlarged left ventricle. There appears to have been a progression in the systolic dysfunction since the previous evaluation. Intrinsic myocardial dysfunction (ie DCM) is a concern. Other possibilities, including primary valve disease with secondary ventricular changes or myocardial depressant effects of systemic disease must also be considered. It would also be important to verify that the owners are not feeding a grain-free, exotic, or boutique diet, as a secondary nutritional cardiomyopathy must also be considered. The left ventricular outflow tract is persistently elevated, suggesting a congenital (sub)aortic stenosis may be

**DATE** 5/26/26



**PATIENT**

Diesel Smith

present. A small heart base mass lesion was also noted on today's study. Given its location, a chemodectoma is considered most likely, and this is likely an incidental finding.

**SPECIES**

Canine

**BREED**

Boxer

**SEX**

Intact male

**AGE**

8 ½ years

**WEIGHT**

66 lbs

**INTERPRETATION OF THE FINDINGS & FURTHER RECOMMENDATIONS**

At this time, continued therapy for the myocardial dysfunction is recommended, to include Vetmedin (0.25-0.35 mg/kg BID) and benazepril (0.5 mg/kg BID, assuming normotension and lack of renal insult). If the owners are feeding a grain free diet, an immediate diet change would be necessary, and the addition of taurine (50 mg/kg BID) would be appropriate. If there is any concern for metabolic/systemic disease, additional testing (complete bloodwork including T4 and resting cortisol, abdominal ultrasound) should be considered. Otherwise, thoracic radiographs, blood pressure, and chemistry panel should be performed now for a baseline. A follow-up echocardiogram, thoracic radiographs, blood pressure, and chemistry panel is recommended in 3-6 months to assess for either static, improved, or progressive changes. Owners should monitor resting respiratory rate at home. Values above 30 breaths/minute or an increase in respiratory rate 10% above baseline should prompt veterinary re-evaluation.

The following sources for supplemental taurine are recommended:

- Mega taurine caps by Twinlab (1000mg capsule)
- Taurine by Swanson Health Products (500mg capsule)
- Taurine by NOW foods (500mg capsule)
- Taurine 500 by GNC (500mg tablet)

**INTERPRETED BY**

Bradley Harris, DVM,  
 DACVECC, DACVIM  
 (cardiology)

Anesthesia considerations:

Anesthesia should be avoided if possible. If anesthesia is necessary, then alpha-2 agonists, ketamine, high dose acepromazine, and Telazol should be avoided. If an ACE inhibitor (enalapril, benazepril) or spironolactone is being given, it should not be administered on the morning of general anesthesia. Other cardiac medications should be administered per the normal dosing schedule. Fluid therapy during anesthesia should be considered at a reduced rate (e.g., 5 ml/kg/hour) if possible (i.e., if not hypotensive). A shorter anesthetic duration will reduce the risk of complications. Pre-oxygenation is advised. Premedication with an opioid (i.e., butorphanol, hydromorphone, oxymorphone) with or without a benzodiazepine is generally the safest protocol. An induction agent such as Propofol, alfaxalone, or diazepam/etomidate can be used to effect. Maintenance of anesthesia with isoflurane or sevoflurane is reasonable. Dobutamine (2.5-10 µg/kg/min as a CRI, starting at 2.5 µg/kg/min and increasing the dosage incrementally) may be used in lieu of fluid boluses to augment systemic blood pressure.

**IMAGING PERFORMED BY**

Kathleen Byrnes

Diet:

A high-quality food from Hills, Royal Canin, Science Diet, Eukanuba, Iams, or Purina that is highly palatable with adequate protein and calories for maintaining optimal body condition. Consider omega-3 fatty acid supplementation. Ensure the patient is not currently receiving a boutique, exotic, or grain-free diet.

**HOSPITAL NAME**

Animal Clinic Madison  
 Mayodan

**REFERRING VET**

Dr. McKinlay

**INVOICE**

77947

**DATE**

5/26/26

Activity:

Moderate physical activity (meandering walks, exploring the backyard, playing with toys inside, getting excited when family gets home, etc.) is encouraged, but periods of strenuous aerobic activity (jogging, strenuous outdoor ball play, prolonged play at the dog park, etc.) should be avoided, especially during periods of high heat (> 80 F) and humidity. Dogs with heart disease tend to tolerate cool and cold temperatures much better than high temperatures. Avoid sudden increases in activity (e.g. 2 block walks during the week but 2 mile walks followed by 30 minutes at the dog park on the weekends) as this may be difficult for the cardiovascular system to deal with.



**PATIENT**

Diesel Smith

**SPECIES**

Canine

**BREED**

Boxer

**SEX**

Intact male

**AGE**

8 ½ years

**WEIGHT**

66 lbs

**INTERPRETED BY**

Bradley Harris, DVM,  
 DACVECC, DACVIM  
 (cardiology)

**IMAGING PERFORMED BY**

Kathleen Byrnes

**HOSPITAL NAME**

Animal Clinic Madison  
 Mayodan

**REFERRING VET**

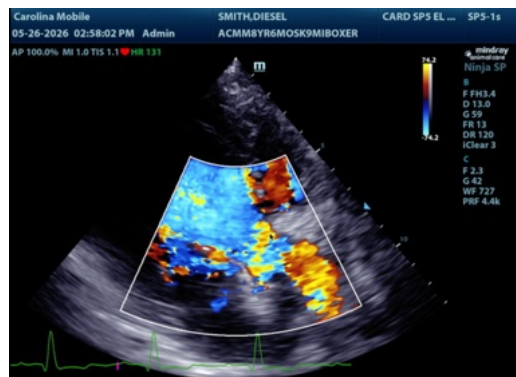
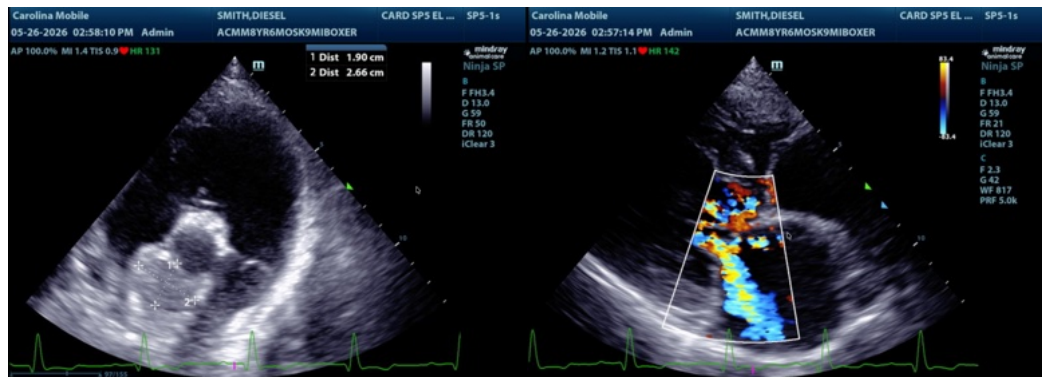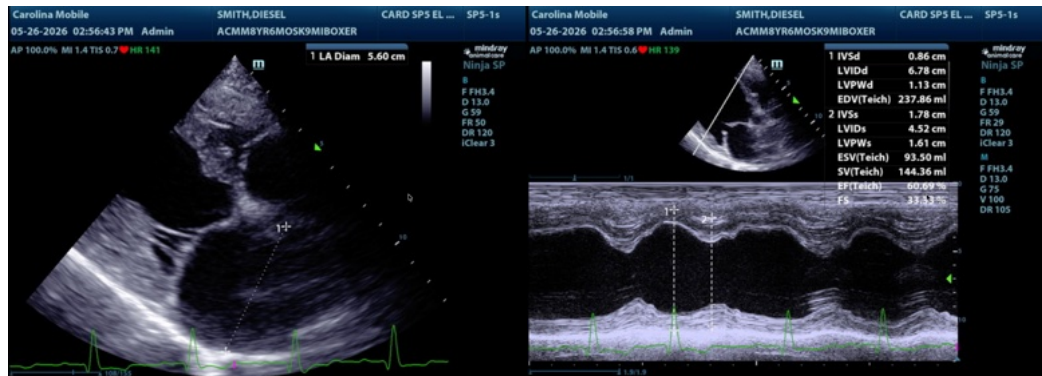
Dr. McKinlay

**INVOICE**

77947

**DATE**

5/26/26



The information and recommendations provided are based on the images presented by the referring veterinarian/sonographer. No evaluation can be communicated regarding pathology that was not visible in the image/video clips provided.

Thank you for this referral. If the clinical or image interpretation does not parallel your findings or if I can be of any further assistance please contact me.

Bradley Harris, DVM, DACVECC, DACVIM (cardiology)

[info@SonoPath.com](mailto:info@SonoPath.com)