

**PATIENT PRESENTING CLINICAL SIGNS**

Sebastian Campbell History: P has history of splenectomy 2 yrs ago for hemangiosarcoma  
 P presented for coughing, gagging, chest xrays showed very large globoid heart.

**SPECIES**

Canine

**ULTRASONOGRAPHIC EXAMINATION OF THE HEART**

**BREED**

Pittie

The left atrium is normal in dimension. The left ventricle is normal in dimension with normal systolic function. The right atrium is poorly visualized due to a large heart-based mass, and the right ventricle is subjectively normal in dimension and displays evidence of diastolic collapse/compression. The anterior and posterior mitral and tricuspid valve leaflets are mildly thickened and redundant, consistent with myxomatous changes. There is mild mitral and tricuspid valve regurgitation noted. The left ventricular outflow tract demonstrated normal laminar flow and the visible aorta is unremarkable. The right ventricular outflow tract assessment revealed normal laminar flow, and appropriate diameter and distensibility. There is no evidence of semilunar valve insufficiency. There is moderate pericardial, and no overt pleural or peritoneal fluid noted. There is a large heterogenous mass effect at the heart base that is suspected to originate from the right auricle; however, due to its size, the true origin of the mass is unclear. The remaining cardiac chambers and visible extra-cardiac regions were free of masses, spontaneous echo contrast, or thrombi.

**SEX**

Neutered male

**AGE**

8 years

**WEIGHT**

51 lbs

**INTERPRETED BY**

Bradley Harris, DVM,  
 DACVECC, DACVIM  
 (cardiology)

CANINE CARDIAC PARAMETERS	Body Weight kg	HR BPM	LAD 4 ch Long	RAD 4 ch Long	La/Ao Heart Base	LVIDd	LVIDs
NORMAL PARAMETER		50-100			<1.6		
PATIENT	23.18 kg	100	3.35	NM	NM	3.93	2.74
CANINE CARDIAC PARAMETERS	FS	EPSS	PV V MAX (m/s)	AV V Max (m/sec)	MR Vmax	TR Vmax	RPA distensibility (normal >30%)
NORMAL PARAMETER	28-40	<0.6	0.7-1.6	0.7-1.7	4.5-5.5	< 2.7	
PATIENT	30	0.2	0.8	1.2	NM	2.7	NM

**IMAGING PERFORMED BY**

Kathleen Byrnes

**HOSPITAL NAME**

Shallowford AH

**REFERRING VET**

Dr. Eads

**INVOICE**

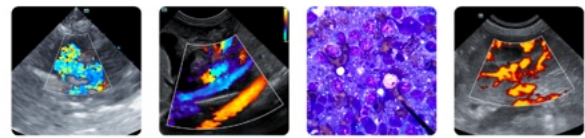
74634

**DATE**

4/20/26

**ULTRASONOGRAPHIC FINDINGS**

These findings identify pericardial effusion in the setting of a mass lesion that is suspected to originate from the wall of the right atrium. The location/appearance of the mass is consistent with hemangiosarcoma, but other forms of neoplasia (chemodectoma, lymphoma, mesothelioma, etc.) cannot be completely excluded based on location alone. The pericardial effusion is most likely neoplastic in origin.



**PATIENT**

Sebastian Campbell

**SPECIES**

Canine

**BREED**

Pittie

**SEX**

Neutered male

**AGE**

8 years

**WEIGHT**

51 lbs

**INTERPRETED BY**

Bradley Harris, DVM,  
 DACVECC, DACVIM  
 (cardiology)

**IMAGING PERFORMED BY**

Kathleen Byrnes

**HOSPITAL NAME**

Shallowford AH

**REFERRING VET**

Dr. Eads

**INVOICE**

74634

**DATE**

4/20/26

**INTERPRETATION OF THE FINDINGS & FURTHER RECOMMENDATIONS**

There is a therapeutic benefit to tapping the pericardium (if there is enough fluid). Evaluation of the fluid will occasionally be of diagnostic value, but in most cases the results are simply compatible with hemorrhage. If it is hemangiosarcoma, the prognosis is very poor, as recurrent effusions are likely, as is the presence of neoplasia elsewhere in the body. Ideally, an abdominal ultrasound should be considered to identify evidence of neoplasia elsewhere in the body, which (or may not) affect prognosis. If no additional masses can be identified, there may be merit to considering surgical intervention, either by taking the entire pericardium (subtotal pericardiectomy), or creation of a smaller hole via approaches less invasive than a median sternotomy. The value of surgery is simply to avoid the effects of recurrent effusion and need for multiple taps; unfortunately, surgery does not alter the natural course of disease, which usually only affords a prognosis of a few months. Chemotherapy concurrent with surgery can be associated with a prognosis of up to 4-5 months, but this path is considered too aggressive by many owners who will elect to euthanize rather than pursue surgery/chemotherapy.

Anesthesia considerations:

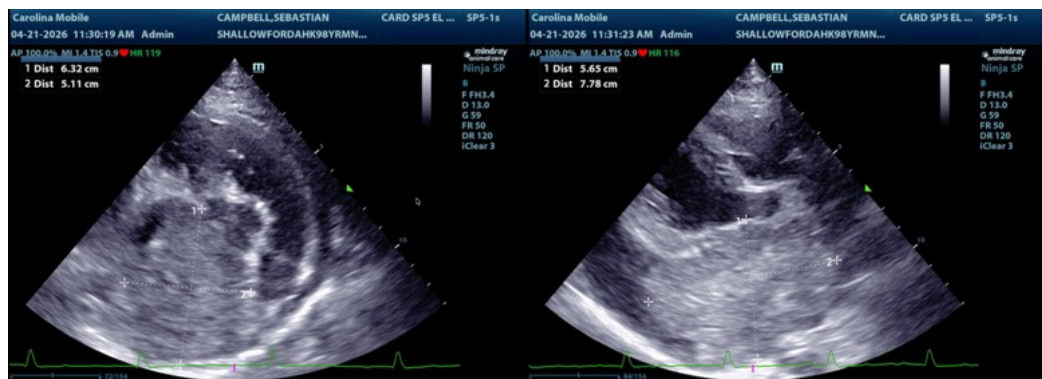
Anesthesia should be avoided until any signs of CHF and pericardial effusion have resolved. If anesthesia is necessary after that time, then alpha-2 agonists, ketamine, high dose acepromazine, and Telazol should be avoided. Fluid therapy is often necessary in the setting of cardiac tamponade to improve venous return. A shorter anesthetic duration will reduce the risk of complications. Pre-oxygenation is advised. Premedication with an opioid (e.g., butorphanol, hydromorphone, oxymorphone) with or without a benzodiazepine is generally the safest protocol. An induction agent such as Propofol, alfaxalone, or diazepam/etomidate can be used to effect. Maintenance of anesthesia with isoflurane or sevoflurane is reasonable.

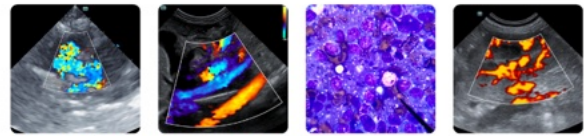
Diet:

No special considerations are necessary. Any high-quality food from Hills, Royal Canin, Science Diet, Eukanuba, Iams, or Purina is reasonable.

Activity:

Moderate physical activity (meandering walks, exploring the back yard, playing with toys inside, getting excited when family gets home, etc.) is encouraged, but periods of strenuous aerobic activity (jogging, strenuous outdoor ball play, prolonged play at the dog park, etc.) should be avoided, especially during periods of high heat (> 80 F) and humidity. Dogs with heart disease tend to tolerate cool and cold temperatures much better than high temperatures. Avoid sudden increases in activity (e.g. 2 block walks during the week but 2 mile walks followed by 30 minutes at the dog park on the weekends) as this may be difficult for the cardiovascular system to deal with.





**PATIENT**

Sebastian Campbell

**SPECIES**

Canine

**BREED**

Pittie

**SEX**

Neutered male

**AGE**

8 years

**WEIGHT**

51 lbs

**INTERPRETED BY**

Bradley Harris, DVM,  
 DACVECC, DACVIM  
 (cardiology)

**IMAGING PERFORMED BY**

Kathleen Byrnes

**HOSPITAL NAME**

Shallowford AH

**REFERRING VET**

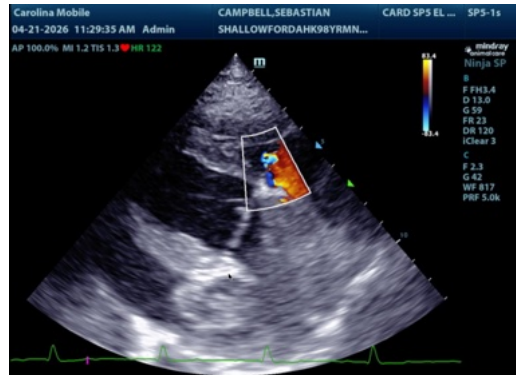
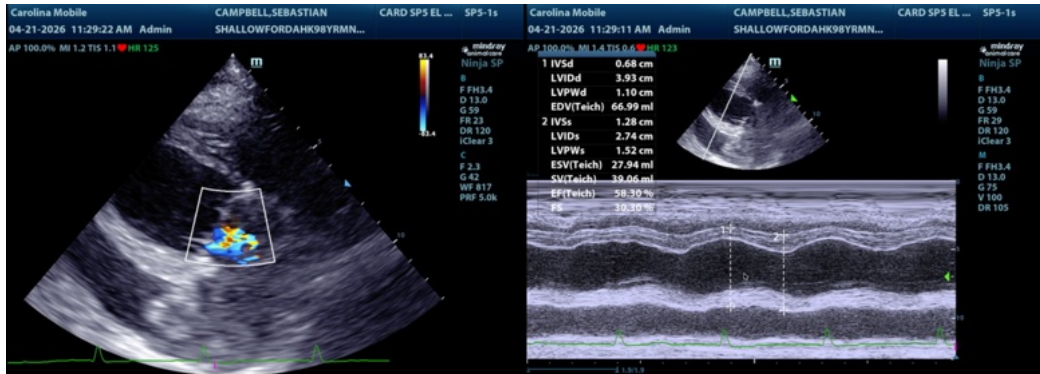
Dr. Eads

**INVOICE**

74634

**DATE**

4/20/26



The information and recommendations provided are based on the images presented by the referring veterinarian/sonographer. No evaluation can be communicated regarding pathology that was not visible in the image/video clips provided.

Thank you for this referral. If the clinical or image interpretation does not parallel your findings or if I can be of any further assistance please contact me.

Bradley Harris, DVM, DACVECC, DACVIM (cardiology)

[info@SonoPath.com](mailto:info@SonoPath.com)