



PATIENT

Sunny Sheperd

SPECIES

Canine

BREED

Toy Poodle

SEX

Spayed female

AGE

10 years

WEIGHT

6.2 lbs

INTERPRETED BY

Bradley Harris, DVM,
 DACVECC, DACVIM
 (cardiology)

IMAGING PERFORMED BY

Kathleen Byrnes

HOSPITAL NAME

Scotts Creek AH

REFERRING VET

Dr. Cartner

INVOICE

72029

DATE

2/27/26

PRESENTING CLINICAL SIGNS

- P presented for echo due to new murmur

ULTRASONOGRAPHIC EXAMINATION OF THE HEART

The left atrium is normal in dimension. The left ventricle is normal in dimension, with normal systolic function. The right atrium and ventricle are normal in dimension, with normal systolic function. The anterior and posterior mitral valve leaflets are thickened and redundant consistent with myxomatous changes, and there is no significant prolapse. There is mild mitral regurgitation identified. The tricuspid valve leaflets are appropriately thin with adequate apposition, intact chordae, no significant tricuspid regurgitation and no evidence of pulmonary hypertension. The left ventricular outflow tract demonstrated normal laminar flow and the visible aorta is unremarkable. The right ventricular outflow tract assessment revealed normal laminar flow, and appropriate diameter and distensibility. There is trivial pulmonic and no aortic valve insufficiency identified. There is no visible pericardial, pleural, or free peritoneal fluid documented. No evidence of hepatic venous congestion is noted. The cardiac chambers, pericardial and visible extra-cardiac regions were free of masses, spontaneous echo contrast, or thrombi.

CANINE CARDIAC PARAMETERS	Body Weight kg	HR BPM	LAD 4 ch Long	RAD 4 ch Long	La/Ao Heart Base	LVIDd	LVIDs
NORMAL PARAMETER		50-100			<1.6		
PATIENT	2.82	140	2.03	1.32	1.33	2.29	0.83
CANINE CARDIAC PARAMETERS	FS	EPSS	PV V MAX (m/s)	AV V Max (m/sec)	MR Vmax	TR Vmax	RPA distensibility (normal >30%)
NORMAL PARAMETER	28-40	<0.6	0.7-1.6	0.7-1.7	4.5-5.5	< 2.7	
PATIENT	64	0.1	0.7	1.0	5.3	Not present	NM

ULTRASONOGRAPHIC FINDINGS

These findings are consistent with degenerative/myxomatous mitral valve disease with minimal to mild hemodynamic effects consistent with ACVIM Stage B1 disease. It is unlikely that any current morbidity is of cardiac origin.

INTERPRETATION OF THE FINDINGS & FURTHER RECOMMENDATIONS

Given these findings, no cardiac therapy is recommended. There are no cardiac contraindications to anesthesia, fluid therapy, vasopressor therapy, or corticosteroids as indicated for further assessment



PATIENT

Sunny Sheperd

and treatment. If not already performed, baseline thoracic radiographs and blood pressure are recommended. A recheck echocardiogram is recommended in 6 months.

SPECIES

Canine

Anesthesia considerations:

If anesthesia is necessary, alpha-2 agonists, ketamine, high dose acepromazine, and Telazol should be avoided. Fluid therapy during anesthesia should be considered at a conservative rate (e.g., 5 ml/kg/hour) if possible.

BREED

Toy Poodle

Diet:

A high-quality food from Hills, Royal Canin, Science Diet, Eukanuba, Iams, or Purina that is highly palatable with adequate protein and calories for maintaining optimal body condition is reasonable.

SEX

Spayed female

Activity:

No special considerations are necessary.

AGE

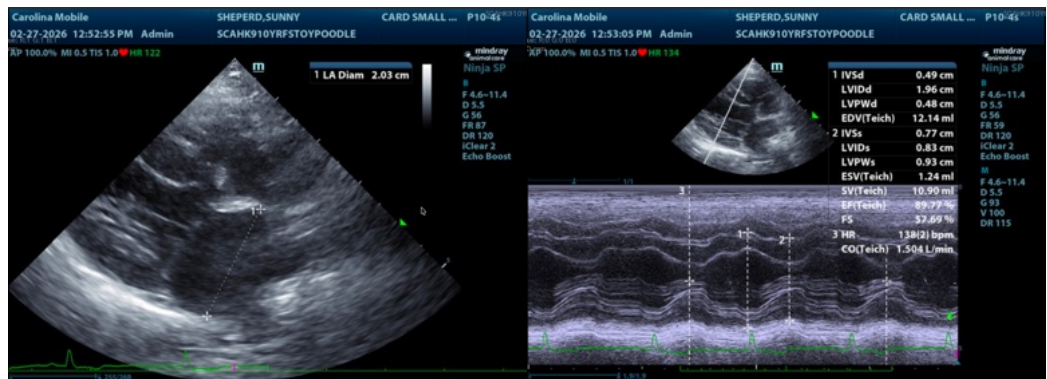
10 years

WEIGHT

6.2 lbs

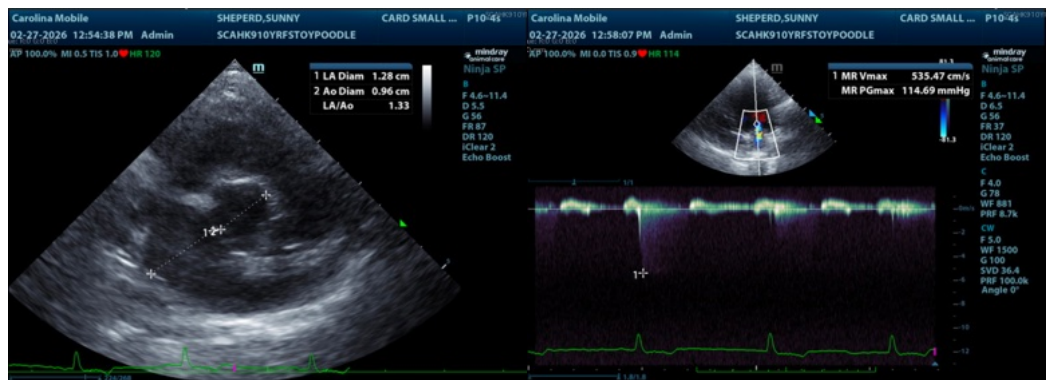INTERPRETED BY

Bradley Harris, DVM,
 DACVECC, DACVIM
 (cardiology)



IMAGING PERFORMED BY

Kathleen Byrnes



HOSPITAL NAME

Scotts Creek AH

REFERRING VET

Dr. Cartner

INVOICE

72029

DATE

2/27/26



PATIENT

Sunny Sheperd

SPECIES

Canine

BREED

Toy Poodle

SEX

Spayed female

AGE

10 years

WEIGHT

6.2 lbs

INTERPRETED BY

Bradley Harris, DVM,
DACVECC, DACVIM
(cardiology)

IMAGING PERFORMED BY

Kathleen Byrnes

HOSPITAL NAME

Scotts Creek AH

REFERRING VET

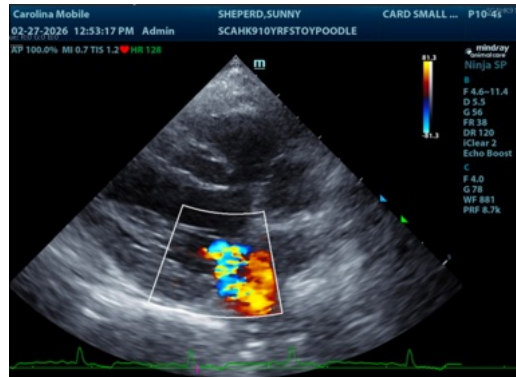
Dr. Cartner

INVOICE

72029

DATE

2/27/26



The information and recommendations provided are based on the images presented by the referring veterinarian/sonographer. No evaluation can be communicated regarding pathology that was not visible in the image/video clips provided.

Thank you for this referral. If the clinical or image interpretation does not parallel your findings or if I can be of any further assistance please contact me.

Bradley Harris, DVM, DACVECC, DACVIM (cardiology)

info@SonoPath.com