

PATIENT

Millie Stovall

SPECIES

Canine

BREED

Yorkie

SEX

Intact female

AGE

2 years

WEIGHT

6.8 lbs

INTERPRETED BY

Bradley Harris, DVM,
 DACVECC, DACVIM
 (cardiology)

IMAGING PERFORMED BY

Kathleen Byrnes

HOSPITAL NAME

Animal Clinic of
 Madison Mayodan

REFERRING VET

Dr. McKinlay

INVOICE

69421

DATE

12/18/25

PRESENTING CLINICAL SIGNS

History: P presented for repeat echo due to lethargy following heat cycle. P previously seen at NC state at 3 months old and diagnosed with Reverse PDA, severe PAH and Eisenmenger physiology. Currently on Sildenafil 5mg PO BID

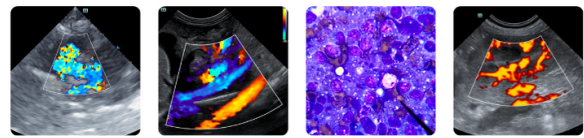
ULTRASONOGRAPHIC EXAMINATION OF THE HEART

The left atrium is normal in dimension. The left ventricle is normal in dimension with normal systolic function. The right atrium and ventricle are subjectively dilated with marginal systolic function and moderate right ventricular hypertrophy. Intraventricular septal flattening is documented. The anterior and posterior mitral valve leaflets presented normal linear structure, extension in systole, and union in diastole, without regurgitation, prolapse, or myxomatous changes noted. The tricuspid valve leaflets display trace regurgitation with evidence of severe pulmonary hypertension. The left ventricular outflow tract demonstrated normal laminar flow and the visible aorta is unremarkable. The right ventricular outflow tract assessment revealed normal laminar flow, with an increased main pulmonary artery diameter and reduced distensibility. There is mild pulmonic insufficiency and no aortic valve insufficiency documented. There is no pericardial, pleural, or free peritoneal fluid noted. The cardiac chambers, pericardial and visible extra-cardiac regions were free of masses, spontaneous echo contrast, or thrombi.

CANINE CARDIAC PARAMETERS	Body Weight kg	HR BPM	LAD 4 ch Long	RAD 4 ch Long	La/Ao Heart Base	LVIDd	LVIDs
NORMAL PARAMETER		50-100			<1.6		
PATIENT	3.09	180	1.53	1.87	1.06	1.32	0.71
CANINE CARDIAC PARAMETERS	FS	EPSS	PV V MAX (m/s)	AV V Max (m/sec)	MR Vmax	TR Vmax	RPA distensibility (normal >30%)
NORMAL PARAMETER	28-40	<0.6	0.7-1.6	0.7-1.7	4.5-5.5	< 2.7	
PATIENT	46	0.2	0.9	0.8	None	NM	14

ULTRASONOGRAPHIC FINDINGS

These findings identify significant pulmonary hypertension (PH) in the absence of any clinically relevant left-sided disease. Therefore, cor pulmonale secondary to primary pulmonary disease/PH is the likely cause for morbidity. Given the history of a patent ductus arteriosus, a right to left shunt is also a likely contributor to any clinical signs.



PATIENT

Millie Stovall

SPECIES

Canine

BREED

Yorkie

SEX

Intact female

AGE

2 years

WEIGHT

6.8 lbs

INTERPRETED BY

Bradley Harris, DVM,
 DACVECC, DACVIM
 (cardiology)

IMAGING PERFORMED BY

Kathleen Byrnes

HOSPITAL NAME

Animal Clinic of
 Madison Mayodan

REFERRING VET

Dr. McKinlay

INVOICE

69421

DATE

12/18/25

INTERPRETATION OF THE FINDINGS & FURTHER RECOMMENDATIONS

At this time, given the right sided enlargement and clinical signs, adjustments to current cardiac therapy are recommended. Vetmedin (.25-.35mg/kg BID) and enalapril (0.5mg/kg BID assuming normotension and lack of azotemia) are recommended in addition to the current sildenafil (5mg BID). If persistent lethargy, or respiratory signs develop with the addition of cardiac therapy, an increase in the sildenafil could be considered. A repeat echo is indicated in 6 months.

Anesthesia considerations:

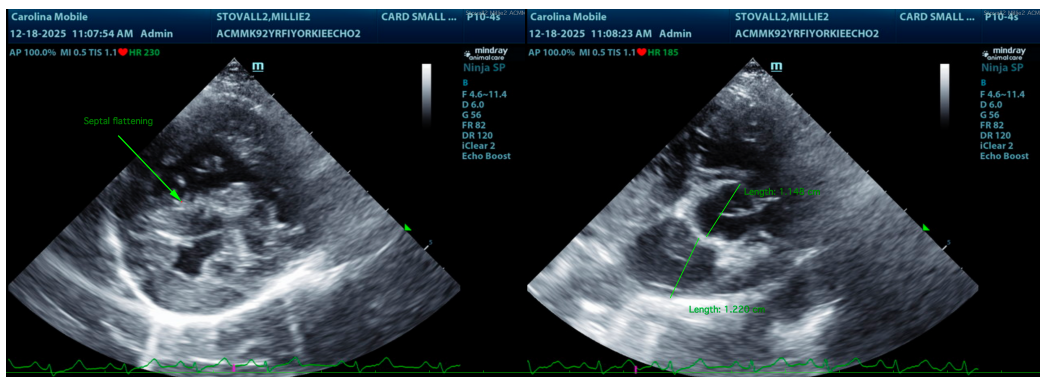
Anesthesia should be avoided if possible. If anesthesia is necessary, then alpha-2 agonists, ketamine, and Telazol should be avoided. If an ACE inhibitor (enalapril, benazepril) or spironolactone is being given, it should not be administered on the morning of general anesthesia. Other cardiac medications should be administered per the normal dosing schedule. Fluid therapy during anesthesia should be considered at a reduced rate (5 ml/kg/hour) if possible (i.e., if not hypotensive). A shorter anesthetic duration will reduce the risk of complications. Pre-oxygenation is mandatory. Premedication with an opioid (e.g., butorphanol, hydromorphone, oxymorphone) with or without a benzodiazepine is generally the safest protocol. An induction agent such as Propofol, alfaxalone, or diazepam/etomidate can be used to effect. Maintenance of anesthesia with isoflurane or sevoflurane is reasonable.

Diet:

A high-quality food from Hills, Royal Canin, Science Diet, Eukanuba, Iams, or Purina that is highly palatable with adequate protein and calories for maintaining optimal body condition with mild dietary sodium restriction (< 100 mg/100 kcal) is recommended. Consider omega-3 fatty acid supplementation. Ensure the patient is not currently receiving a boutique, exotic, or grain-free diet.

Activity:

Moderate physical activity (meandering walks, exploring the backyard, playing with toys inside, getting excited when family gets home, etc.) is encouraged, but periods of strenuous aerobic activity (jogging, strenuous outdoor ball play, prolonged play at the dog park, etc.) should be avoided, especially during periods of high heat (> 80 F) and humidity. Dogs with heart disease tend to tolerate cool and cold temperatures much better than high temperatures. Avoid sudden increases in activity (e.g. 2 block walks during the week but 2 mile walks followed by 30 minutes at the dog park on the weekends) as this may be difficult for the cardiovascular system to deal with.





PATIENT

Millie Stovall

SPECIES

Canine

BREED

Yorkie

SEX

Intact female

AGE

2 years

WEIGHT

6.8 lbs

INTERPRETED BY

Bradley Harris, DVM,
 DACVECC, DACVIM
 (cardiology)

IMAGING PERFORMED BY

Kathleen Byrnes

HOSPITAL NAME

Animal Clinic of
 Madison Mayodan

REFERRING VET

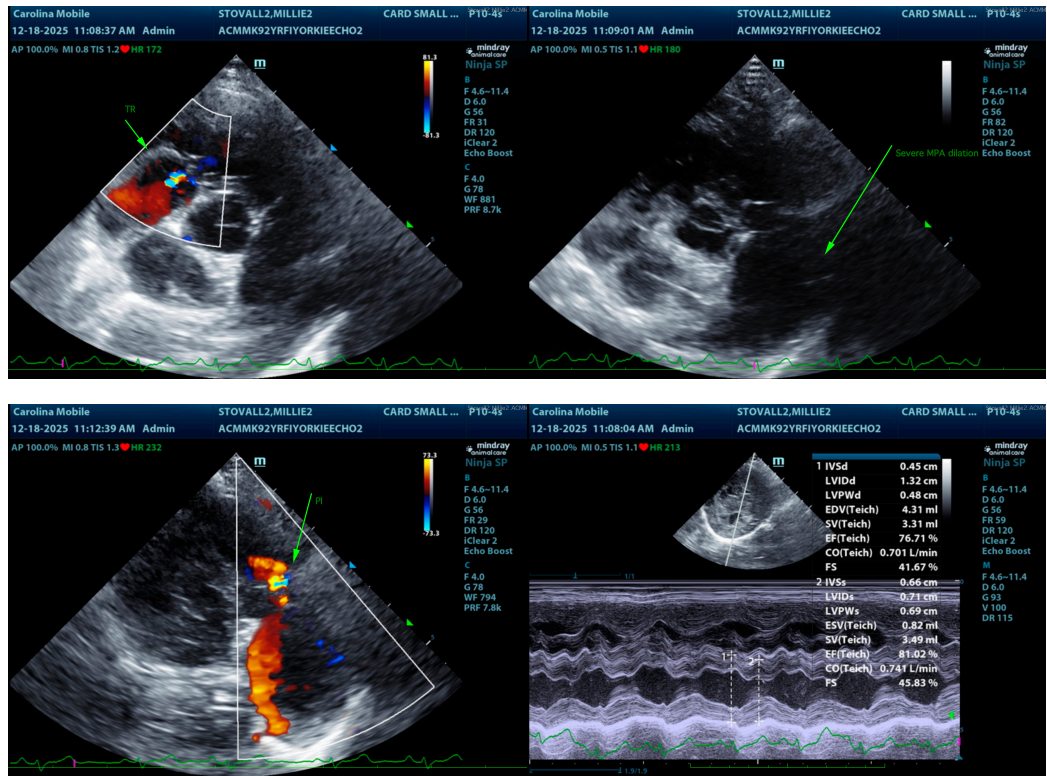
Dr. McKinlay

INVOICE

69421

DATE

12/18/25



The information and recommendations provided are based on the images presented by the referring veterinarian/sonographer. No evaluation can be communicated regarding pathology that was not visible in the image/video clips provided.

Thank you for this referral. If the clinical or image interpretation does not parallel your findings or if I can be of any further assistance please contact me.

Bradley Harris, DVM, DACVECC, DACVIM (cardiology)

info@SonoPath.com