

PATIENT

Bella Murray

PRESENTING CLINICAL SIGNS

History: 2-3/6 murmur

SPECIES

Canine

BREED

French Bulldog

SEX

Intact female

AGE

6 months

WEIGHT

20 lbs

INTERPRETED BY

Bradley Harris, DVM,
 DACVECC, DACVIM
 (cardiology)

IMAGING PERFORMED BY

Andrea Nicastro, DVM,
 DACVIM

ULTRASONOGRAPHIC EXAMINATION OF THE HEART

The left atrium is normal in dimension. The left ventricle is normal in dimension as well as systolic function. The right atrium and ventricle are subjectively enlarged, with adequate systolic function, and evidence of mild intraventricular septal flattening. There is turbulent flow across the intra-atrial septum at the level of the fossa/foramen ovale. This flow disturbance is not interrogated with spectral doppler. The anterior and posterior mitral and tricuspid valve leaflets presented normal linear structure, extension in systole, and union in diastole with mild tricuspid regurgitation. The left ventricular outflow tract demonstrated normal laminar flow and subjective structural valvular integrity with no aortic insufficiency. The visible aorta is unremarkable. Pulmonary outflow tract assessment revealed a narrowed valve orifice with evidence of dysplasia, turbulent flow, an increased main pulmonary artery dimension, and moderate pulmonic insufficiency. Coronary artery anomalies are not excluded based on this study. There is no visible pericardial, pleural, or free peritoneal fluid noted. The cardiac chambers, pericardial and visible extra-cardiac regions were free of masses, spontaneous echo contrast, or thrombi.

CANINE CARDIAC PARAMETERS	Body Weight kg	HR BPM	LAD 4 ch Long	RAD 4 ch Long	La/Ao Heart Base	LVIDd	LVIDs
NORMAL PARAMETER		50-100			<1.6		
PATIENT	9.09	80	1.77	2.26	1.23	2.1	1.12
CANINE CARDIAC PARAMETERS	FS	EPSS	PV V MAX (m/s)	AV V Max (m/sec)	MR Vmax	TR Vmax	RPA distensibility (normal >30%)
NORMAL PARAMETER	28-40	<0.6	0.7-1.6	0.7-1.7	4.5-5.5	< 2.7	
PATIENT	47	0.2	0.4	1.0	NM	NM	NM

HOSPITAL NAME

Trinity Island

REFERRING VET

Dr. Oldham

ULTRASONOGRAPHIC FINDINGS

- These findings are consistent moderate to severe pulmonic stenosis, which is a likely explanation for the enlarged right side. The turbulent flow across the atrial septum is most consistent with a patent foramen ovale, with likely right to left flow, although this is not confirmed on this study.

INVOICE

78359

DATE

6/4/26

INTERPRETATION OF THE FINDINGS & FURTHER RECOMMENDATIONS

Cardiac therapy with atenolol (initial dose 1-2 mg/kg BID, higher doses may be needed especially as the patient grows) is recommended. Given the severity of disease, the merits of a balloon valvuloplasty/transvalvular stent angioplasty should be discussed with the owner. If an intervention is being considered, a re-evaluation by a cardiologist would be appropriate. Otherwise, a repeat echo is recommended in another 6-12 months.

Anesthesia:



PATIENT

Bella Murray

SPECIES

Canine

BREED

French Bulldog

SEX

Intact female

AGE

6 months

WEIGHT

20 lbs

INTERPRETED BY

Bradley Harris, DVM,
 DACVECC, DACVIM
 (cardiology)

IMAGING PERFORMED BY

Andrea Nicastro, DVM,
 DACVIM

HOSPITAL NAME

Trinity Island

REFERRING VET

Dr. Oldham

INVOICE

78359

DATE

6/4/26

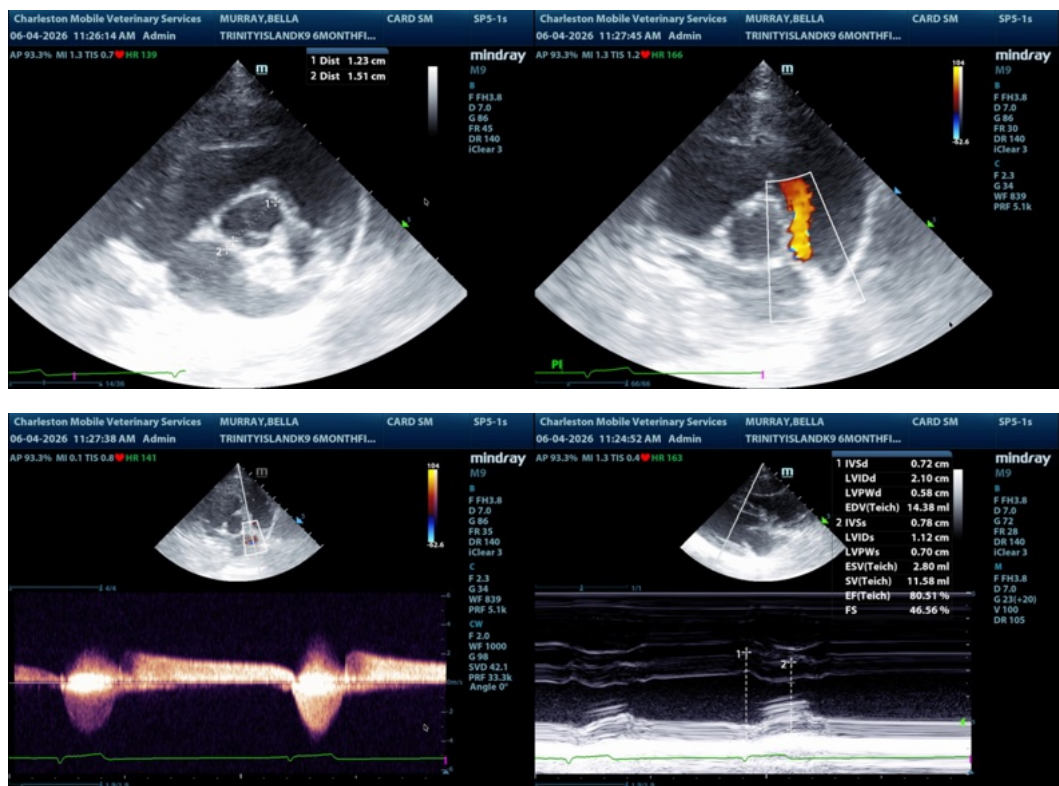
If anesthesia is necessary, then alpha-2 agonists, ketamine, high dose acepromazine, and Telazol should be avoided. Skip any ACE-inhibitor (if receiving) on morning of anesthesia. Fluid therapy during anesthesia should be considered at a reduced rate (e.g., 5 ml/kg/hour) if possible. A shorter anesthetic duration will reduce the risk of complications. Pre-oxygenation is advised. Pre-medication with an opioid (i.e., butorphanol, hydromorphone, oxymorphone) with or without a benzodiazepine is generally the safest protocol. An induction agent such as Propofol, alfaxalone, or diazepam/etomidate can be used to effect. Maintenance of anesthesia with isoflurane or sevoflurane is reasonable.

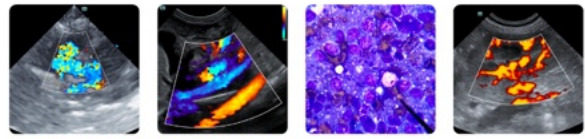
Diet:

A high-quality food from Hills, Royal Canin, Science Diet, Eukanuba, Iams, or Purina that is highly palatable with adequate protein and calories for maintaining optimal body condition is reasonable.

Activity:

Avoid overly strenuous activity.





PATIENT

Bella Murray

SPECIES

Canine

BREED

French Bulldog

SEX

Intact female

AGE

6 months

WEIGHT

20 lbs

INTERPRETED BY

Bradley Harris, DVM,
 DACVECC, DACVIM
 (cardiology)

IMAGING PERFORMED BY

Andrea Nicastro, DVM,
 DACVIM

HOSPITAL NAME

Trinity Island

REFERRING VET

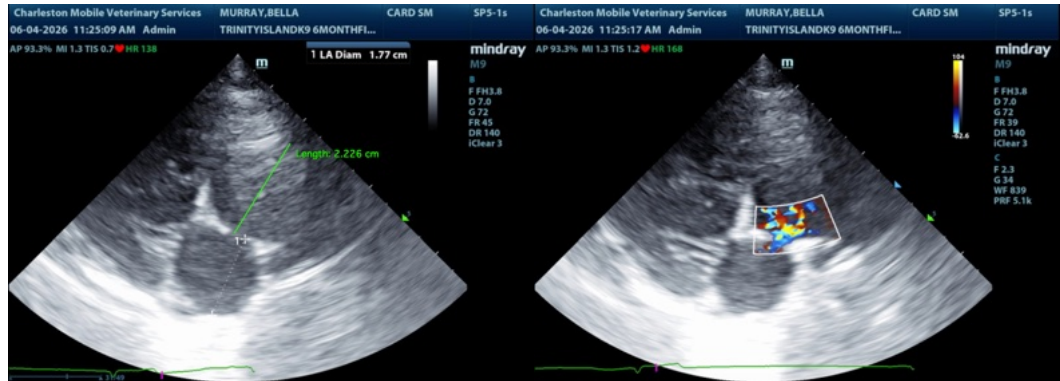
Dr. Oldham

INVOICE

78359

DATE

6/4/26



The information and recommendations provided are based on the images presented by the referring veterinarian/sonographer. No evaluation can be communicated regarding pathology that was not visible in the image/video clips provided.

Thank you for this referral. If the clinical or image interpretation does not parallel your findings or if I can be of any further assistance please contact me.

Bradley Harris, DVM, DACVECC, DACVIM (cardiology)

info@SonoPath.com