

PATIENT

Petey Heminger

SPECIES

Canine

BREED

Chihuahua

SEX

Neutered male

AGE

15 years

WEIGHT

2.7 kg

INTERPRETED BY

Bradley Harris, DVM,
 DACVECC, DACVIM
 (cardiology)

IMAGING PERFORMED BY

Andrea Nicastro, DVM,
 DACVIM

HOSPITAL NAME

River Oaks

REFERRING VET

Dr. DiNicola

INVOICE

74295

DATE

4/8/26

PRESENTING CLINICAL SIGNS

History: Tooth root abscess. Grade 2-3/6 heart murmur on most recent exam
 O had wanted to schedule grade 3 dental, but after consulting Safe Pet Anesthesia and based on previous recommendations, agreed to an echo for staging prior to any anesthetic event. Platelets elevated at 545 (148-484) BUN 28 (7-27) TT4 0.6 (1.0 to 4.0) - suspected euthyroid sick syndrome

BP: sys 103 sys 100 sys 102 dia 83 dia 82 dia 83 map 94 map 93 map 93 resp rate 24bpm HR: 114-185bpm

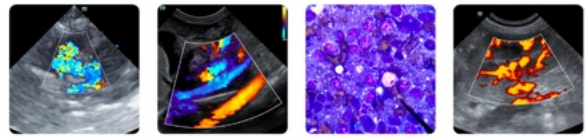
ULTRASONOGRAPHIC EXAMINATION OF THE HEART

The left atrium is at the upper limits of normal to mildly enlarged. The left ventricle is normal in dimension with normal systolic function. The right atrium and ventricle are normal in dimension with normal systolic function. The anterior and posterior mitral valve leaflets are thickened and redundant consistent with myxomatous changes, and there is moderate prolapse. There is mild to moderate mitral regurgitation identified. The tricuspid valve leaflets are appropriately thin with adequate apposition and intact chordae, with mild tricuspid regurgitation and no evidence of pulmonary hypertension. The left ventricular outflow tract demonstrated normal laminar flow and the visible aorta is unremarkable. The right ventricular outflow tract assessment revealed normal laminar flow, with appropriate main pulmonary artery diameter and right pulmonary artery distensibility. There is no pulmonic and trivial aortic valve insufficiency identified. There is no visible pericardial, pleural, or free peritoneal fluid documented. No evidence of hepatic venous congestion is noted. The cardiac chambers, pericardial, and visible extra-cardiac regions were free of masses, spontaneous echo contrast, or thrombi.

CANINE CARDIAC PARAMETERS	Body Weight kg	HR BPM	LAD 4 ch Long	RAD 4 ch Long	La/Ao Heart Base	LVIDd	LVIDs
NORMAL PARAMETER		50-100			<1.6		
PATIENT	2.7 kg	80	2.35	1.03	1.35	2.09	1.17
CANINE CARDIAC PARAMETERS	FS	EPSS	PV V MAX (m/s)	AV V Max (m/sec)	MR Vmax	TR Vmax	RPA distensibility (normal >30%)
NORMAL PARAMETER	28-40	<0.6	0.7-1.6	0.7-1.7	4.5-5.5	< 2.7	
PATIENT	44	0.3	0.7	1.1	4.7	2.6	30

ECG:

There is a six-lead ECG with mild baseline artifact available for review. The underlying rhythm is regular at an average rate of 120bpm. The rhythm appears to be sinus in origin with narrow QRS complexes (<70ms). There is no atrial or ventricular ectopy and no conduction delay or block identified. This is most consistent with a normal sinus rhythm.



PATIENT

Petey Heminger

SPECIES

Canine

BREED

Chihuahua

SEX

Neutered male

AGE

15 years

WEIGHT

2.7 kg

INTERPRETED BY

Bradley Harris, DVM,
 DACVECC, DACVIM
 (cardiology)

IMAGING PERFORMED BY

Andrea Nicastro, DVM,
 DACVIM

HOSPITAL NAME

River Oaks

REFERRING VET

Dr. DiNicola

INVOICE

74295

DATE

4/8/26

ULTRASONOGRAPHIC FINDINGS

These findings are consistent with degenerative/myxomatous mitral valve disease with moderate hemodynamic effects consistent with at least ACVIM Stage B1 and possibly early stage B2 (MINE 2 score 3 - mild). Stage B2 criteria for heart enlargement that are used to identify dogs that may benefit substantially from treatment before the onset of clinical signs of heart failure include hear murmur intensity $\geq 3/6$, echocardiographic LA/Ao in the right-sided short axis view in early diastole ≥ 1.6 , left ventricular internal diameter in diastole, normalized for body weight (LVIDDN) ≥ 1.7 , VLAS > 3 , and breed-adjusted radiographic vertebral heart score (VHS) > 10.5 .

INTERPRETATION OF THE FINDINGS & FURTHER RECOMMENDATIONS

Given the degree of chamber dilation, an aggressive treatment approach would be to start cardiac therapy. Therapy would include enalapril or benazepril (0.5 mg/kg BID assuming normotension and lack of renal insult) and Vetmedin (0.25-0.35 mg/kg BID). While there is an increased risk of IV fluids, corticosteroids, or anesthesia, there is no overt objection, as the need likely outweighs the risks. If not already performed, baseline thoracic radiographs in addition to the provided doppler blood pressures are recommended. A repeat chest X-rays, BP, and chemistry should be performed again in 1-2 weeks. A repeat echo, blood pressure, chemistry panel and thoracic radiographs are indicated in 6 months.

As the results are on the border between stages B1 and B2 (B2 is where therapy is typically recommended), a conservative approach is to hold off on therapy and just follow the 6 month recheck plan. Either option is acceptable and should be discussed with the owner. Regardless of approach, owners should begin monitoring the resting respiratory rate. If a progressive increase in respiratory rate is seen, then evaluation by a veterinarian is necessary.

Anesthesia considerations:

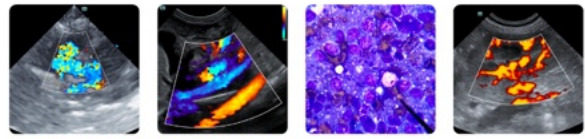
If anesthesia is necessary, then alpha-2 agonists, ketamine, high dose acepromazine, and Telazol should be avoided. Skip any ACE-inhibitor (if receiving) on morning of anesthesia. Fluid therapy during anesthesia should be considered at a reduced rate (e.g., 5 ml/kg/hour) if possible. A shorter anesthetic duration will reduce the risk of complications. Pre-oxygenation is advised. Pre-medication with an opioid (i.e., butorphanol, hydromorphone, oxymorphone) with or without a benzodiazepine is generally the safest protocol. An induction agent such as Propofol, alfaxalone, or diazepam/etomidate can be used to effect. Maintenance of anesthesia with isoflurane or sevoflurane is reasonable.

Diet:

Ensure feeding a grain-inclusive diet if possible. A high-quality food from Hills, Royal Canin, Science Diet, Eukanuba, Iams, or Purina that is highly palatable with adequate protein and calories for maintaining optimal body condition with mild dietary sodium restriction (< 100 mg/100 kcal) is recommended. Consider omega-3 fatty acid supplementation.

Activity:

Moderate physical activity (meandering walks, exploring the backyard, playing with toys inside, getting excited when family gets home, etc.) is encouraged, but periods of strenuous aerobic activity (jogging, strenuous outdoor ball play, prolonged play at the dog park, etc.) should be avoided, especially during periods of high heat (> 80 F) and humidity. Dogs with heart disease tend to tolerate cool and cold temperatures much better than high temperatures. Avoid sudden increases in activity (e.g. 2 block walks during the week but 2 mile walks followed by 30 minutes at the dog park on the weekends) as this may be difficult for the cardiovascular system to deal with.



PATIENT

Petey Heminger

SPECIES

Canine

BREED

Chihuahua

SEX

Neutered male

AGE

15 years

WEIGHT

2.7 kg

INTERPRETED BY

Bradley Harris, DVM,
 DACVECC, DACVIM
 (cardiology)

IMAGING PERFORMED BY

Andrea Nicastro, DVM,
 DACVIM

HOSPITAL NAME

River Oaks

REFERRING VET

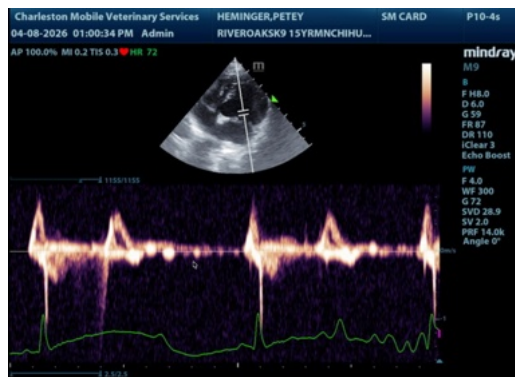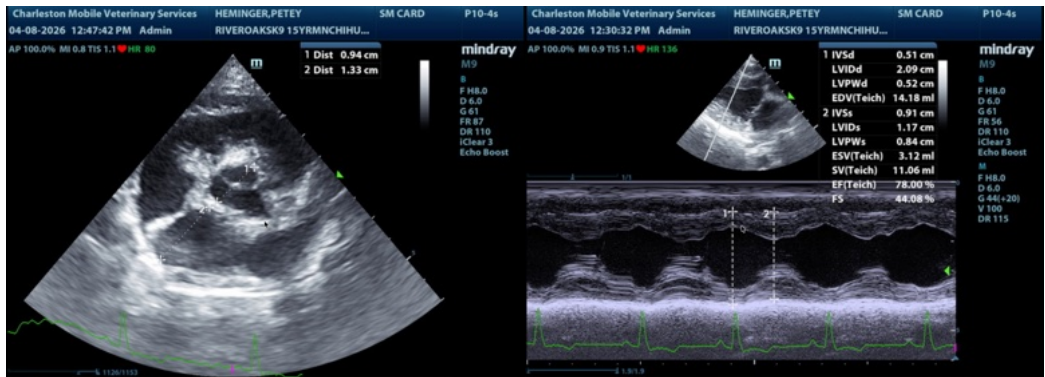
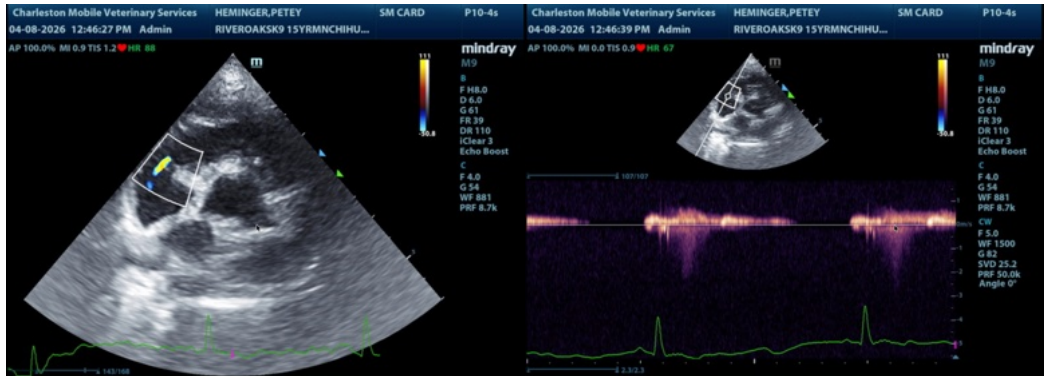
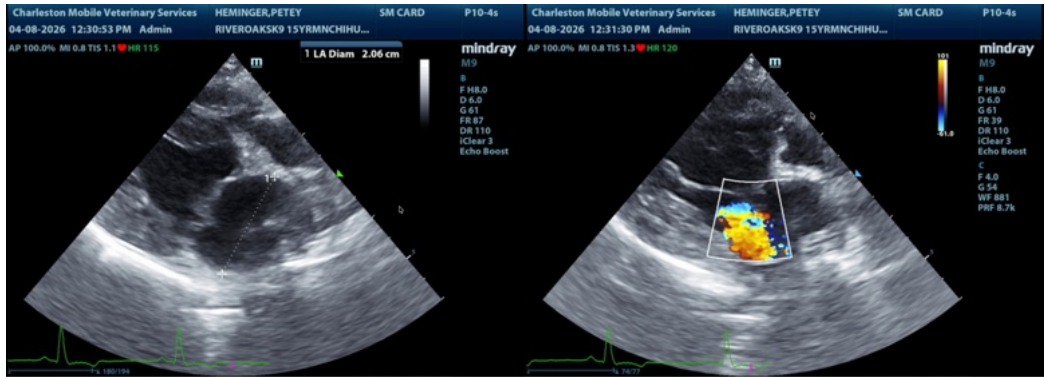
Dr. DiNicola

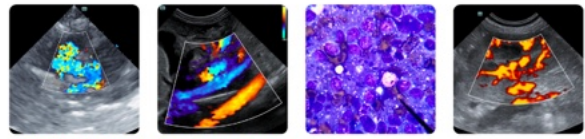
INVOICE

74295

DATE

4/8/26





PATIENT

Petey Heminger

SPECIES

Canine

BREED

Chihuahua

SEX

Neutered male

AGE

15 years

WEIGHT

2.7 kg

INTERPRETED BY

Bradley Harris, DVM,
DACVECC, DACVIM
(cardiology)

**IMAGING
PERFORMED BY**

Andrea Nicastro, DVM,
DACVIM

HOSPITAL NAME

River Oaks

REFERRING VET

Dr. DiNicola

INVOICE

74295

DATE

4/8/26

The information and recommendations provided are based on the images presented by the referring veterinarian/sonographer. No evaluation can be communicated regarding pathology that was not visible in the image/video clips provided.

Thank you for this referral. If the clinical or image interpretation does not parallel your findings or if I can be of any further assistance please contact me.

Bradley Harris, DVM, DACVECC, DACVIM (cardiology)

info@SonoPath.com