

**PATIENT**

Mocha Vaughn

**SPECIES**

Feline

**BREED**

Maine Coon

**SEX**

Spayed female

**AGE**

8 years

**WEIGHT**

13.7 lbs

**INTERPRETED BY**

Bradley Harris, DVM,  
 DACVECC, DACVIM  
 (cardiology)

**IMAGING PERFORMED BY**

Andrea Nicastro, DVM,  
 DACVIM

**HOSPITAL NAME**

Meadowlawn Animal  
 Services Conway

**REFERRING VET**

Dr. Heim

**INVOICE**

73992

**DATE**

4/1/26

**PRESENTING CLINICAL SIGNS**

- Hx of coughing. Mediastinal masses (2) found on an ultrasound done previous July at a different clinic. One mass measured 4.5 x 3.4 cm, the other measured 3.5 x 1.9 cm per RDVM notes. Has gained weight since previous evaluation. No current meds.

**ULTRASONOGRAPHIC EXAMINATION OF THE HEART**

The left atrium is normal in dimension. There are no distinct left atrial thrombi/clots or spontaneous echo contrast appreciated. The left ventricle is normal in dimension as well as wall thickness, and no evidence of restriction. Left ventricular systolic function is normal, with adequate contractility. The right atrium and ventricle are subjectively normal in dimension and systolic function. The anterior and posterior mitral and tricuspid valve leaflets presented normal linear structure, extension in systole, and union in diastole with mild tricuspid regurgitation. There is no evidence of systolic anterior mitral valve motion documented. The left ventricular outflow tract demonstrated normal laminar flow and subjective structural valvular integrity. The visible aorta is unremarkable. Pulmonary outflow tract assessment revealed normal valve structure, laminar flow, and appropriate diameter and distensibility. There is no evidence of pulmonary hypertension documented. There are multiple mixed echogenic intrathoracic mass effects that are distorting the normal position of the cardiac window. These masses appear to be extra-pericardial, and there origin is uncertain. There is no visible pericardial effusion, but a moderate volume of pleural fluid is noted.

FELINE CARDIAC PARAMETERS	BODY WEIGHT (kg)	HR (BPM)	IVSd (cm)	LVIDd (cm)	LVWd (cm)	FS (%)	EF (%)
NORMAL PARAMETER	-----	150-240	0.3-0.6	1.0-2.1	0.25-0.6	35-67	80-100
PATIENT	6.23 kg	NM	0.45	1.59	0.44	49	84
FELINE CARDIAC PARAMETERS	LA/AO (M-mode)	LA/AO HEART BASE (Sisson)	LAD LA MAX 4 Chamber	LVOT VEL. (m/s)	RVOT VEL. (m/s)	IVRT (m/)	
NORMAL PARAMETER	<1.5	1.6	0.7-1.7	<1.6	<1.3	40-60	
PATIENT	1.04	1.18	1.12	1.5	0.8	NM	
Adapted from June Boon, Veterinary Echocardiography, 1998 Sisson D et al. JVIM 1991; 5: 232, Jacobs et al. Am J Vet Res 1985; 46:1705							

**ULTRASONOGRAPHIC FINDINGS**

These findings are consistent with an essentially normal echocardiogram. Any murmur auscultated will be considered functional in origin. The origin of the mediastinal/intrathoracic masses is uncertain, and while they are distorting the normal cardiac window, cardiac hemodynamics appear to be preserved at this time.



**PATIENT**

Mocha Vaughn

**SPECIES**

Feline

**BREED**

Maine Coon

**SEX**

Spayed female

**AGE**

8 years

**WEIGHT**

13.7 lbs

**INTERPRETED BY**

Bradley Harris, DVM,  
 DACVECC, DACVIM  
 (cardiology)

**IMAGING PERFORMED BY**

Andrea Nicastro, DVM,  
 DACVIM

**HOSPITAL NAME**

Meadowlawn Animal  
 Services Conway

**REFERRING VET**

Dr. Heim

**INVOICE**

73992

**DATE**

4/1/26

**INTERPRETATION OF THE FINDINGS & FURTHER RECOMMENDATIONS**

Given these findings, no cardiac therapy is recommended. There are no cardiac contraindications to corticosteroids or fluid therapy as indicated for further treatment. No specific recheck echocardiogram is recommended. A thoracocentesis with fluid analysis and cytology may provide additional information as far as the nature of the masses, as would fine needle aspirates of the masses depending on their location.

Anesthesia considerations:

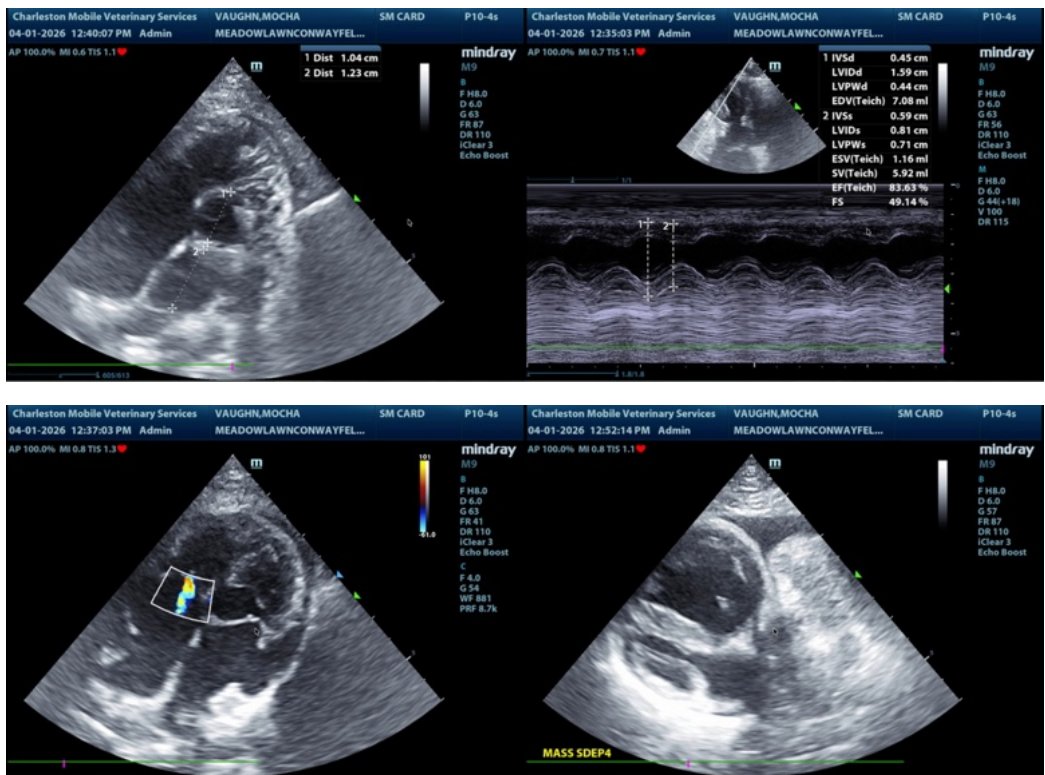
No special cardiac considerations are necessary

Diet:

No special considerations are necessary. Any high-quality food from Hills, Royal Canin, Science Diet, Eukanuba, Iams, or Purina is reasonable.

Activity:

No special considerations are necessary.



The information and recommendations provided are based on the images presented by the referring veterinarian/sonographer. No evaluation can be communicated regarding pathology that was not visible in the image/video clips provided.

Thank you for this referral. If the clinical or image interpretation does not parallel your findings or if I can be of any further assistance please contact me.

Bradley Harris, DVM, DACVECC, DACVIM (cardiology)  
[info@SonoPath.com](mailto:info@SonoPath.com)