



**PATIENT**

Honey Bun Onkka

**SPECIES**

Feline

**BREED**

Domestic Shorthair

**SEX**

Intact male

**AGE**

11 months

**WEIGHT**

4.7 kg

**INTERPRETED BY**

Bradley Harris, DVM,  
 DACVECC, DACVIM  
 (cardiology)

**IMAGING PERFORMED BY**

Andrea Nicastro, DVM,  
 DACVIM

**HOSPITAL NAME**

Blue Pearl Summerville

**REFERRING VET**

Dr. Wasiak

**INVOICE**

73546

**DATE**

3/18/26

**PRESENTING CLINICAL SIGNS**

- Pleural effusion; dyspnea
- Cardiomegaly and pleural effusion on rads BP - 150 mmHg HR/RR - 240/60

**ULTRASONOGRAPHIC EXAMINATION OF THE HEART**

The left atrium is normal in some dimensions and moderately enlarged in others. There are no distinct left atrial thrombi/clots or spontaneous echo contrast appreciated. The left ventricle is normal in dimension with normal wall thickness, and no evidence of restriction. Left ventricular systolic function is normal, with paradoxical septal motion. The right atrium and ventricle are severely enlarged with reduced systolic function. The anterior and posterior mitral valve leaflets presented normal linear structure, extension in systole, and union in diastole without regurgitation. The tricuspid valve is mildly irregular with mild to moderate tricuspid regurgitation, but no overt evidence of pulmonary hypertension. There is no evidence of systolic anterior mitral motion documented. The left ventricular outflow tract demonstrated normal laminar flow and subjective structural valvular integrity. The visible aorta is unremarkable. Pulmonary outflow tract assessment revealed normal valve structure, laminar flow, and appropriate diameter and distensibility. There is trace aortic insufficiency. There is no pericardial, but moderate pleural effusion noted. Mild hepatic venous congestion is documented

FELINE CARDIAC PARAMETERS	BODY WEIGHT (kg)	HR (BPM)	IVSd (cm)	LVIDd (cm)	LWVd (cm)	FS (%)	EF (%)
NORMAL PARAMETER	-----	150-240	0.3-0.6	1.0-2.1	0.25-0.6	35-67	80-100
PATIENT	4.7	NM	0.48	1.53	0.42	27	67
FELINE CARDIAC PARAMETERS	LA/AO (M-mode)	LA/AO HEART BASE (Sisson)	LAD LA MAX 4 Chamber		LVOT VEL. (m/s)	RVOT VEL. (m/s)	IVRT (m/)
NORMAL PARAMETER	<1.5	1.6	0.7-1.7		<1.6	<1.3	40-60
PATIENT	2.4	1.79	1.19		0.6	0.6	NM
Adapted from June Boon, Veterinary Echocardiography, 1998 Sisson D et al. JVIM 1991; 5: 232, Jacobs et al. Am J Vet Res 1985; 46:1705							

**ULTRASONOGRAPHIC FINDINGS**

These findings identify significant right sided dilation in the absence of any right sided pressure load (pulmonary stenosis or hypertension). The left atrial dilation noted is suspected to be artifactual, and secondary to the small aortic diameter. Given the degree of tricuspid valve regurgitation, a congenital tricuspid dysplasia is considered a differential. However, in the absence of congenital valve disease, a right ventricular cardiomyopathy (ARVC) is also a possibility. The degree of atrial dilation makes CHF a likely explanation for the clinical signs.



**PATIENT**

Honey Bun Onkka

**SPECIES**

Feline

**BREED**

Domestic Shorthair

**SEX**

Intact male

**AGE**

11 months

**WEIGHT**

4.7 kg

**INTERPRETED BY**

Bradley Harris, DVM,  
 DACVECC, DACVIM  
 (cardiology)

**IMAGING PERFORMED BY**

Andrea Nicastro, DVM,  
 DACVIM

**HOSPITAL NAME**

Blue Pearl Summerville

**REFERRING VET**

Dr. Wasiak

**INVOICE**

73546

**DATE**

3/18/26

**INTERPRETATION OF THE FINDINGS & FURTHER RECOMMENDATIONS**

Treatment for CHF is recommended, to include Lasix (2mg/kg BID), enalapril (0.5mg/kg q24, assuming normal BP and kidney function), Vetmedin (0.25-0.35mg/kg BID), and spironolactone (1mg/kg BID). A repeat chest X-rays, chemistry, and BP is recommended prior to discharge, and again in 1-2 weeks. Additionally, Plavix/clopidogrel (1/4 of a 75 mg tablet, or 18.75 mg PO q 24 h) +/- rivaroxaban (2.5mg q24) should be initiated as an anti-thrombotic. Due to the bitter taste of this medication, it may be best to place it in an empty gelatin capsule or use products such as a Pill Pocket. Barring any setbacks or complications, a repeat echo/rads will be recommended in 3-6 months.

**Anesthesia considerations:**

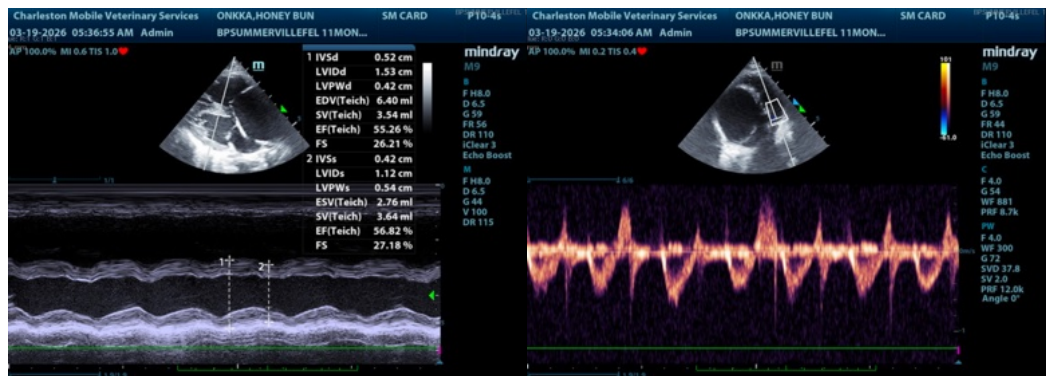
Anesthesia should be avoided until signs of congestion have resolved. If anesthesia is necessary, then alpha-2 agonists, ketamine, high dose acepromazine, and Telazol should be avoided. If an ACE inhibitor (enalapril, benazepril) or spironolactone is being given, it should not be administered on the morning of general anesthesia. Other cardiac medications should be administered per the normal dosing schedule. Anesthetic IV fluid use should be limited to < 3 ml/kg/hr and, if IV fluid therapy is administered during the procedure, a 1 mg/kg dose of IM Lasix should be administered when the patient is awake and standing in recovery. A shorter anesthetic duration will reduce the risk of complications. Pre-oxygenation is advised. Premedication with an opioid (i.e., butorphanol, hydromorphone, oxymorphone) with or without a benzodiazepine is generally the safest protocol. An induction agent such as Propofol, alfaxalone, or diazepam/etomidate can be used to effect. Maintenance of anesthesia with isoflurane or sevoflurane is reasonable.

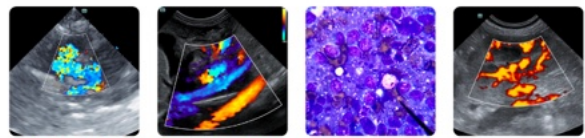
**Diet:**

A high-quality food from Hills, Royal Canin, Science Diet, Eukanuba, Iams, or Purina that is highly palatable with adequate protein and calories for maintaining optimal body condition with mild dietary sodium restriction (< 100 mg/100 kcal) is recommended. Consider omega-3 fatty acid supplementation.

**Activity:**

Avoid strenuous activity.





**PATIENT**

Honey Bun Onkka

**SPECIES**

Feline

**BREED**

Domestic Shorthair

**SEX**

Intact male

**AGE**

11 months

**WEIGHT**

4.7 kg

**INTERPRETED BY**

Bradley Harris, DVM,  
 DACVECC, DACVIM  
 (cardiology)

**IMAGING PERFORMED BY**

Andrea Nicastro, DVM,  
 DACVIM

**HOSPITAL NAME**

Blue Pearl Summerville

**REFERRING VET**

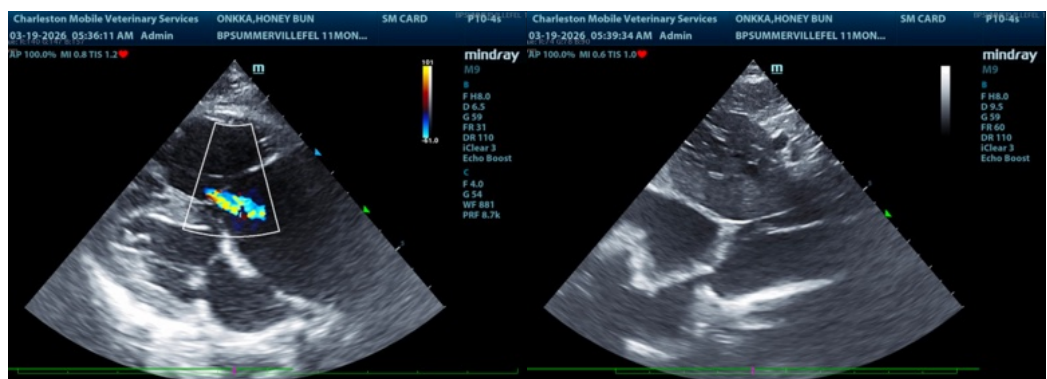
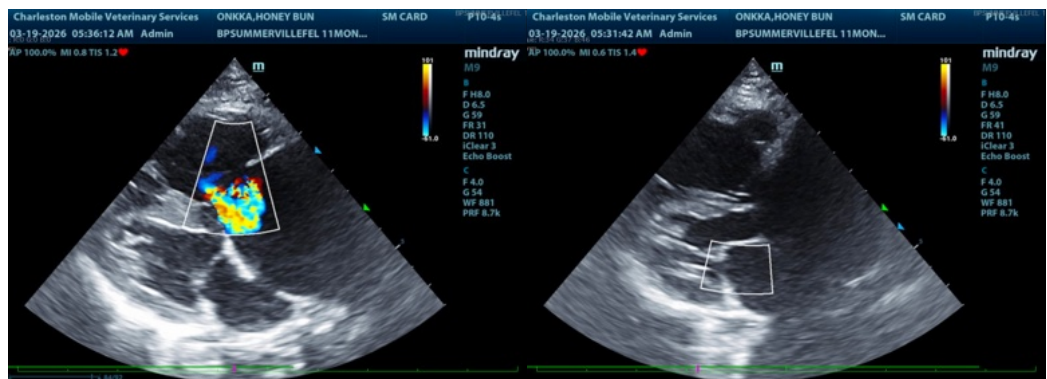
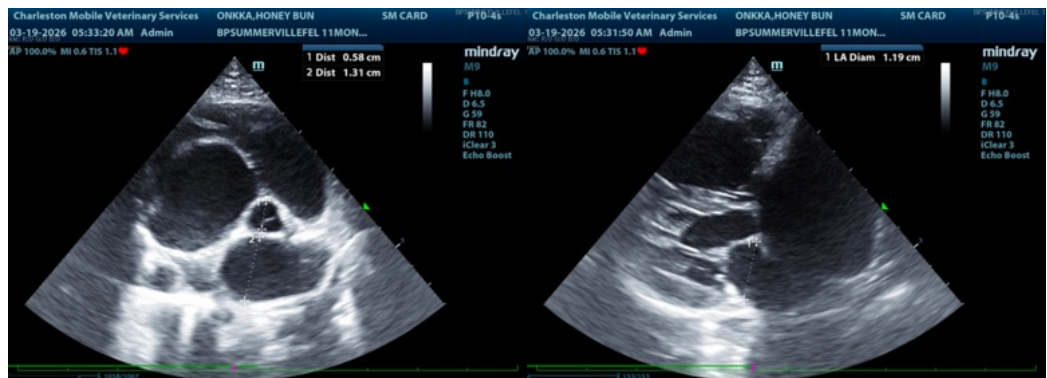
Dr. Wasiak

**INVOICE**

73546

**DATE**

3/18/26



The information and recommendations provided are based on the images presented by the referring veterinarian/sonographer. No evaluation can be communicated regarding pathology that was not visible in the image/video clips provided.

Thank you for this referral. If the clinical or image interpretation does not parallel your findings or if I can be of any further assistance please contact me.

Bradley Harris, DVM, DACVECC, DACVIM (cardiology)

[info@SonoPath.com](mailto:info@SonoPath.com)