



PATIENT

Whitney Kiser

SPECIES

Feline

BREED

Feline

SEX

Neutered male

AGE

9 years

WEIGHT

4.2 kg

INTERPRETED BY

Bradley Harris, DVM,
 DACVECC, DACVIM
 (cardiology)

IMAGING PERFORMED BY

Andrea Nicastro, DVM,
 DACVIM

HOSPITAL NAME

Lowcountry Veterinary
 Neurology and Surgery

REFERRING VET

Dr. Freeman

INVOICE

69043

DATE

11/26/25

PRESENTING CLINICAL SIGNS

History: P presents to the Neurology/Neurosurgery service on the 25th for evaluation of abnormal behavior. Whitney was seen by his veterinarian on the 18th of November for a several week history of reduced appetite and an episode of collapse and open mouth breathing. Complete bloodwork showed low platelets and lymphocytes and elevated glucose. Thoracic radiographs were also performed. He was treated with depomedrol and mirtazapine. Since then, he has been circling. He represented to the veterinarian on the 24th for after another episode. He cried out and was found limp. He was open mouth breathing on presentation but settled in oxygen. His first bowel movement since the 18th was today. He is otherwise healthy and has been with this family for 5 years. Whitney is currently on the following medications: Mirtazapine PRN Mentation: quiet, alert, responsive Gait: ambulatory without assistance, circles to the right, drifts to the left Postural reactions: delayed right TL and PL Reflexes: normal Cranial nerves: normal Sensory: nonpainful Neuroanatomic localization: intracranial III/VI systolic murmur

ULTRASONOGRAPHIC EXAMINATION OF THE HEART

The left atrium is normal in dimension. There are no distinct left atrial thrombi/clots or spontaneous echo contrast appreciated. The left ventricle is normal in dimension as well as wall thickness, and no evidence of restriction. Left ventricular systolic function is normal, with adequate contractility. The right atrium and ventricle are subjectively normal in dimension and systolic function. The anterior and posterior mitral and tricuspid valve leaflets presented normal linear structure, extension in systole, and union in diastole without regurgitation. There is no evidence of systolic anterior mitral valve motion documented. The left ventricular outflow tract demonstrated normal laminar flow and subjective structural valvular integrity. The visible aorta is unremarkable. Pulmonary outflow tract assessment revealed normal valve structure, laminar flow, and appropriate diameter and distensibility. There is no evidence of pulmonary hypertension documented. There is no visible pericardial, pleural, or free peritoneal fluid noted.

FELINE CARDIAC PARAMETERS	BODY WEIGHT (kg)	HR (BPM)	IVSd (cm)	LVIDd (cm)	LVWd (cm)	FS (%)	EF (%)
NORMAL PARAMETER	-----	150-240	0.3-0.6	1.0-2.1	0.25-0.6	35-67	80-100
PATIENT	4.2 kg	NM	0.49	1.54	0.41	68	95
FELINE CARDIAC PARAMETERS	LA/AO (M-mode)	LA/AO HEART BASE (Sisson)	LAD LA MAX 4 Chamber		LVOT VEL. (m/s)	RVOT VEL. (m/s)	IVRT (m/)
NORMAL PARAMETER	<1.5	1.6	0.7-1.7		<1.6	<1.3	40-60
PATIENT	1.28	1.3	1.3		1.2	0.9	NM
Adapted from June Boon, Veterinary Echocardiography, 1998							
Sisson D et al. JVIM 1991; 5: 232, Jacobs et al. Am J Vet Res 1985; 46:1705							



PATIENT

Whitney Kiser

SPECIES

Feline

BREED

Feline

SEX

Neutered male

AGE

9 years

WEIGHT

4.2 kg

INTERPRETED BY

Bradley Harris, DVM,
 DACVECC, DACVIM
 (cardiology)

IMAGING PERFORMED BY

Andrea Nicastro, DVM,
 DACVIM

HOSPITAL NAME

Lowcountry Veterinary
 Neurology and Surgery

REFERRING VET

Dr. Freeman

INVOICE

69043

DATE

11/26/25

ULTRASONOGRAPHIC FINDINGS

These findings are consistent with an essentially normal echocardiogram. Any murmur auscultated will be considered functional in origin. There is no cardiac cause of the episodes identified.

INTERPRETATION OF THE FINDINGS & FURTHER RECOMMENDATIONS

Given these findings, no cardiac therapy is recommended. There are no cardiac contraindications to corticosteroids or fluid therapy as indicated for further treatment. No specific recheck echocardiogram is recommended.

Anesthesia considerations:

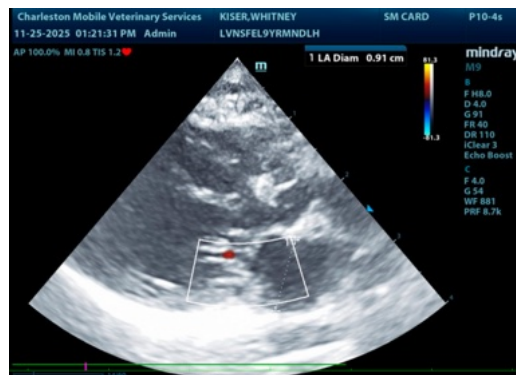
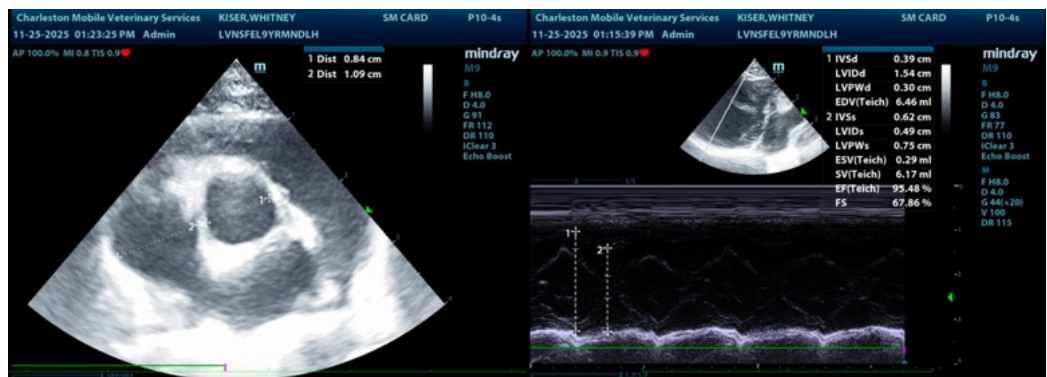
No special cardiac considerations are necessary

Diet:

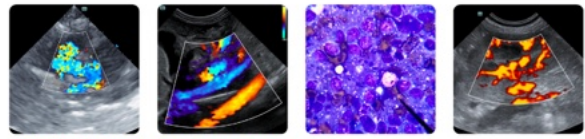
No special considerations are necessary. Any high-quality food from Hills, Royal Canin, Science Diet, Eukanuba, Iams, or Purina is reasonable.

Activity:

No special considerations are necessary.



The information and recommendations provided are based on the images presented by the referring veterinarian/sonographer. No evaluation can be communicated regarding pathology that was not visible in the image/video clips provided.



PATIENT

Whitney Kiser

SPECIES

Feline

BREED

Feline

SEX

Neutered male

AGE

9 years

WEIGHT

4.2 kg

INTERPRETED BY

Bradley Harris, DVM,
DACVECC, DACVIM
(cardiology)

**IMAGING
PERFORMED BY**

Andrea Nicastro, DVM,
DACVIM

HOSPITAL NAME

Lowcountry Veterinary
Neurology and Surgery

REFERRING VET

Dr. Freeman

INVOICE

69043

DATE

11/26/25

Thank you for this referral. If the clinical or image interpretation does not parallel your findings or if I can be of any further assistance please contact me.

Bradley Harris, DVM, DACVECC, DACVIM (cardiology)

info@SonoPath.com