

**PATIENT**

Tali Zorah Mann

**SPECIES**

Feline

**BREED**

Russian Blue Cross

**SEX**

Spayed female

**AGE**

14 years

**WEIGHT**

10.42 lbs

**INTERPRETED BY**

Bradley Harris, DVM,  
DACVECC, DACVIM  
(cardiology)

**IMAGING PERFORMED BY**

Sara Hansen

**HOSPITAL NAME**

Vetco Total Care  
Center St Salem

**REFERRING VET**

Dr. LaPoint

**INVOICE**

78784

**DATE**

6/17/26

**PRESENTING CLINICAL SIGNS**

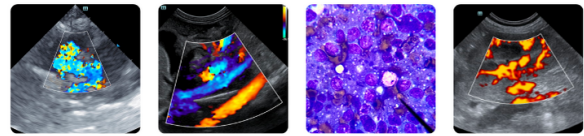
Presented for consult for a dental cleaning with extractions due to suspect tooth root abscess.  
Exam findings: Grade II/VI murmur  
2cm round black lobulated mass just inside of L pinna  
Grade 4/4 dental disease, loose teeth, severe gingival recession, increased upper airway noise, soft flocculent swelling over nasal bridge between eyes at 6/3/26 appointment, resolved with clavacillin at 6/17/26 appointment.  
IDEXX Services: Cardiopet® proBNP Add-on—Feline, Feline Senior Profile 3/19/2026  
Monocytes 0.891 (0.042 - 0.467 K/ $\mu$ L), Eosinophils 0.173 (0.209 - 1.214 K/ $\mu$ L), AST 89 (16 - 67 U/L)  
Cardiopet proBNP (Feline) 105 (0 - 100 pmol/L)  
For ECHO Only: Blood Pressure  
SIZE 3: (1) 211/87 - 129. (2) 208/73 - 119. (3) 235/213 - 220. (4) 208/106 - 140. (5) 195/160 - 172  
HR: 180 RR: 50  
Grade II/VI heart murmur  
Current Medications Clavacillin 62.5mg

**ULTRASONOGRAPHIC EXAMINATION OF THE HEART**

The left atrium is normal in dimension. There are no distinct left atrial thrombi/clots or spontaneous echo contrast appreciated. The left ventricle is normal in dimension as well as wall thickness, and no evidence of restriction. Left ventricular systolic function is normal, with adequate contractility. The right atrium and ventricle are subjectively normal in dimension and systolic function. The anterior and posterior mitral and tricuspid valve leaflets presented normal linear structure, extension in systole, and union in diastole without regurgitation. There is no evidence of systolic anterior mitral valve motion documented. The left ventricular outflow tract demonstrated normal laminar flow and subjective structural valvular integrity. The visible aorta is unremarkable. Pulmonary outflow tract assessment revealed normal valve structure, laminar flow, and appropriate diameter and distensibility. There is no evidence of pulmonary hypertension documented. There is no visible pericardial, pleural, or free peritoneal fluid noted.

FELINE CARDIAC PARAMETERS	BODY WEIGHT (kg)	HR (BPM)	IVSd (cm)	LVIDd (cm)	LVWd (cm)	FS (%)	EF (%)
NORMAL PARAMETER	-----	150-240	0.3-0.6	1.0-2.1	0.25-0.6	35-67	80-100
PATIENT	4.74 kg	NM	0.52	1.06	0.48	72	NM
FELINE CARDIAC PARAMETERS	LA/AO (M-mode)	LA/AO HEART BASE (Sisson)	LAD LA MAX 4 Chamber		LVOT VEL. (m/s)	RVOT VEL. (m/s)	IVRT (m/)
NORMAL PARAMETER	<1.5	1.6	0.7-1.7		<1.6	<1.3	40-60
PATIENT	1.05	1.05	1.14		1.0	0.9	NM

Adapted from June Boon, Veterinary Echocardiography, 1998  
Sisson D et al. JVIM 1991; 5: 232, Jacobs et al. Am J Vet Res 1985; 46:1705



**PATIENT**

Tali Zorah Mann

**SPECIES**

Feline

**BREED**

Russian Blue Cross

**SEX**

Spayed female

**AGE**

14 years

**WEIGHT**

10.42 lbs

**INTERPRETED BY**

Bradley Harris, DVM,  
 DACVECC, DACVIM  
 (cardiology)

**IMAGING PERFORMED BY**

Sara Hansen

**HOSPITAL NAME**

Vetco Total Care  
 Center St Salem

**REFERRING VET**

Dr. LaPoint

**INVOICE**

78784

**DATE**

6/17/26

**ULTRASONOGRAPHIC FINDINGS**

These findings are consistent with an essentially normal echocardiogram. Any murmur auscultated will be considered functional in origin.

**INTERPRETATION OF THE FINDINGS & FURTHER RECOMMENDATIONS**

Given these findings, no cardiac therapy is recommended. There are no cardiac contraindications to corticosteroids or fluid therapy as indicated for further treatment. No specific recheck echocardiogram is recommended.

Anesthesia considerations:

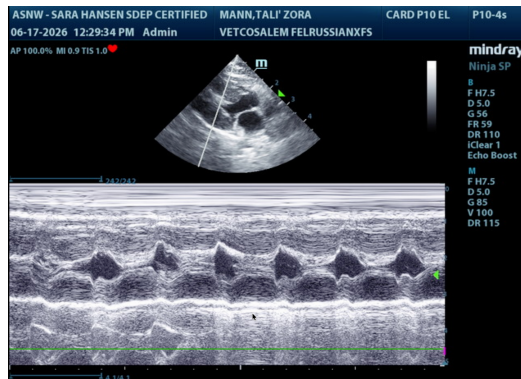
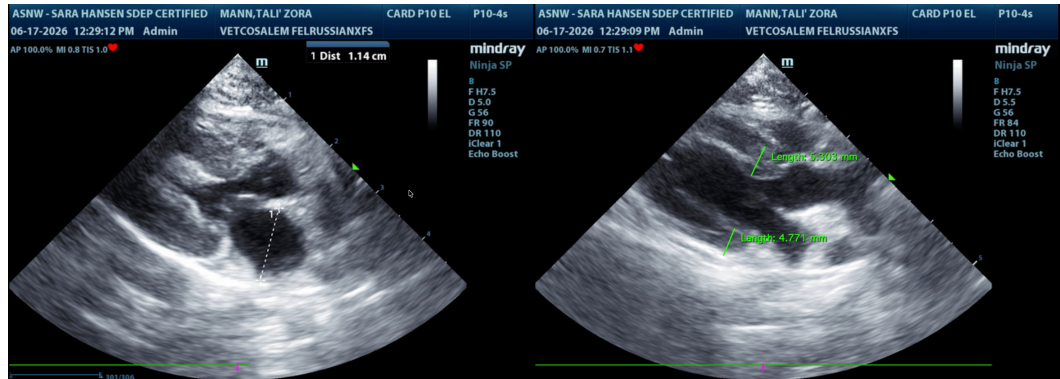
No special cardiac considerations are necessary

Diet:

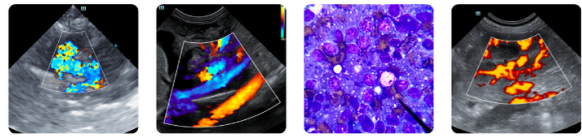
No special considerations are necessary. Any high-quality food from Hills, Royal Canin, Science Diet, Eukanuba, Iams, or Purina is reasonable.

Activity:

No special considerations are necessary.



The information and recommendations provided are based on the images presented by the referring veterinarian/sonographer. No evaluation can be communicated regarding pathology that was not visible in the image/video clips provided.



**PATIENT**

Tali Zorah Mann

**SPECIES**

Feline

**BREED**

Russian Blue Cross

**SEX**

Spayed female

**AGE**

14 years

**WEIGHT**

10.42 lbs

**INTERPRETED BY**

Bradley Harris, DVM,  
DACVECC, DACVIM  
(cardiology)

**IMAGING  
PERFORMED BY**

Sara Hansen

**HOSPITAL NAME**

Vetco Total Care  
Center St Salem

**REFERRING VET**

Dr. LaPoint

**INVOICE**

78784

**DATE**

6/17/26

Thank you for this referral. If the clinical or image interpretation does not parallel your findings or if I can be of any further assistance please contact me.

Bradley Harris, DVM, DACVECC, DACVIM (cardiology)

[info@SonoPath.com](mailto:info@SonoPath.com)