

**PATIENT**

Thor Hallstrom

**SPECIES**

Canine

**BREED**

Beagle Cross

**SEX**

Neutered male

**AGE**

14 years

**WEIGHT**

15 lbs

**INTERPRETED BY**

Bradley Harris, DVM,  
DACVECC, DACVIM  
(cardiology)

**IMAGING PERFORMED BY**

Sara Hansen

**HOSPITAL NAME**

Four Corners VC  
Eugene

**REFERRING VET**

Dr. Sinkowski

**INVOICE**

77827

**DATE**

5/21/26

**PRESENTING CLINICAL SIGNS**

Worsening heart murmur now IV/VI  
LABNORMAL Labwork Values: Albumin 4.1, ALT 241, all else wnl  
For ECHO Only: Blood Pressure 141/86 MAP 103  
HR/RR/BP: HR 150 RR 50

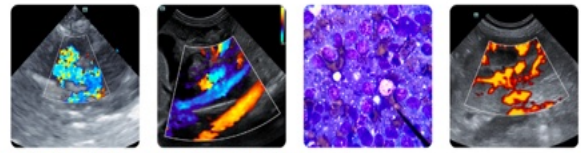
**ULTRASONOGRAPHIC EXAMINATION OF THE HEART**

The left atrium is moderate to severely enlarged. The left ventricle is severely enlarged, with marginal systolic function. The right atrium and ventricle are normal in dimension, with normal systolic function. The anterior and posterior mitral valve leaflets are thickened and redundant consistent with myxomatous changes, and there is moderate prolapse. There is mild to moderate mitral regurgitation identified. The tricuspid valve leaflets are thickened and redundant, with trivial tricuspid regurgitation and evidence of mild pulmonary hypertension. The left ventricular outflow tract demonstrated normal laminar flow and the visible aorta is unremarkable. The right ventricular outflow tract assessment revealed normal laminar flow, with appropriate main pulmonary artery diameter and right pulmonary artery distensibility. There is no pulmonic and no aortic valve insufficiency identified. There is no visible pericardial, pleural, or free peritoneal fluid documented. No evidence of hepatic venous congestion is noted. The cardiac chambers, pericardial and visible extra-cardiac regions were free of masses, spontaneous echo contrast, or thrombi.

CANINE CARDIAC PARAMETERS	Body Weight kg	HR BPM	LAD 4 ch Long	RAD 4 ch Long	La/Ao Heart Base	LVIDd	LVIDs
NORMAL PARAMETER		50-100			<1.6		
PATIENT	6.82 kg	NM	3.96	NM	1.58	4.14	2.29
CANINE CARDIAC PARAMETERS	FS	EPSS	PV V MAX (m/s)	AV V Max (m/sec)	MR Vmax	TR Vmax	RPA distensibility (normal >30%)
NORMAL PARAMETER	28-40	<0.6	0.7-1.6	0.7-1.7	4.5-5.5	< 2.7	
PATIENT	45	0.1	1.2	2.5	6.3	3.6	NM

**ECG:**

A six-lead ECG at a paper speed of 25mm/s is available for review. The average heart rate is approximately 130bpm, with a normal mean electrical axis. The QRS complexes are sinus in origin, with appropriate P-Q intervals. There are episodic irregular R-R intervals, consistent with respiratory variation. There is no evidence of atrial or ventricular ectopy, nor any atrioventricular block. The underlying rhythm is most consistent with a respiratory sinus arrhythmia (normal physiologic change).



**PATIENT**

Thor Hallstrom

**SPECIES**

Canine

**BREED**

Beagle Cross

**SEX**

Neutered male

**AGE**

14 years

**WEIGHT**

15 lbs

**INTERPRETED BY**

Bradley Harris, DVM,  
 DACVECC, DACVIM  
 (cardiology)

**IMAGING PERFORMED BY**

Sara Hansen

**HOSPITAL NAME**

Four Corners VC  
 Eugene

**REFERRING VET**

Dr. Sinkowski

**INVOICE**

77827

**DATE**

5/21/26

**ULTRASONOGRAPHIC FINDINGS**

These findings are consistent with degenerative/myxomatous mitral valve disease with moderate hemodynamic effects consistent with ACVIM Stage B2.

**INTERPRETATION OF THE FINDINGS & FURTHER RECOMMENDATIONS**

Given the degree of chamber dilation, cardiac therapy with enalapril (0.5 mg/kg BID assuming normotension and lack of renal insult) and Vetmedin (0.25-0.35 mg/kg BID) is recommended. While there is an increased risk of IV fluids, corticosteroids, or anesthesia, there is no overt objection, as the need likely outweighs the risks. A repeat chest X-rays, BP, and chemistry should be performed again in 1-2 weeks. A repeat echo is indicated in 6 months. Consideration could be given to mitral valve repair (open heart surgery or transcatheter edge to edge repair). Owners should monitor resting respiratory rate at home. Values above 30 breaths/minute or an increase in respiratory rate 10% above baseline should prompt veterinary re-evaluation.

Anesthesia considerations:

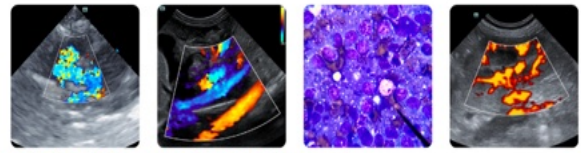
While there is no CHF present, there is likely an increased anesthetic risk which must be considered prior to any anesthetic procedure. If anesthesia is necessary, then alpha-2 agonists, ketamine, high dose acepromazine, and Telazol should be avoided. If an ACE inhibitor (enalapril, benazepril) or spironolactone is being given, it should not be administered on the morning of general anesthesia. Other cardiac medications should be administered per the normal dosing schedule. Fluid therapy during anesthesia should be considered at a reduced rate (e.g., 5 ml/kg/hour) if possible. A shorter anesthetic duration will reduce the risk of complications. Pre-oxygenation is advised. Premedication with an opioid (i.e., butorphanol, hydromorphone, oxymorphone) with or without a benzodiazepine is generally the safest protocol. An induction agent such as Propofol, alfaxalone, or diazepam/etomidate can be used to effect. Maintenance of anesthesia with isoflurane or sevoflurane is reasonable. Dobutamine (2.5-10 µg/kg/min as a CRI, starting at 2.5 µg/kg/min and increasing the dosage incrementally) may be used in lieu of fluid boluses to augment systemic blood pressure.

Diet:

A high-quality food from Hills, Royal Canin, Science Diet, Eukanuba, Iams, or Purina that is highly palatable with adequate protein and calories for maintaining an optimal body condition is recommended. Consider omega-3 fatty acid supplementation. Avoid any boutique, exotic, or grain-free diets.

Activity:

Moderate physical activity (meandering walks, exploring the backyard, playing with toys inside, getting excited when family gets home, etc.) is encouraged, but periods of strenuous aerobic activity (jogging, strenuous outdoor ball play, prolonged play at the dog park, etc.) should be avoided, especially during periods of high heat (> 80 F) and humidity. Dogs with heart disease tend to tolerate cool and cold temperatures much better than high temperatures. Avoid sudden increases in activity (e.g. 2 block walks during the week but 2 mile walks followed by 30 minutes at the dog park on the weekends) as this may be difficult for the cardiovascular system to deal with.



**PATIENT**

Thor Hallstrom

**SPECIES**

Canine

**BREED**

Beagle Cross

**SEX**

Neutered male

**AGE**

14 years

**WEIGHT**

15 lbs

**INTERPRETED BY**

Bradley Harris, DVM,  
 DACVECC, DACVIM  
 (cardiology)

**IMAGING PERFORMED BY**

Sara Hansen

**HOSPITAL NAME**

Four Corners VC  
 Eugene

**REFERRING VET**

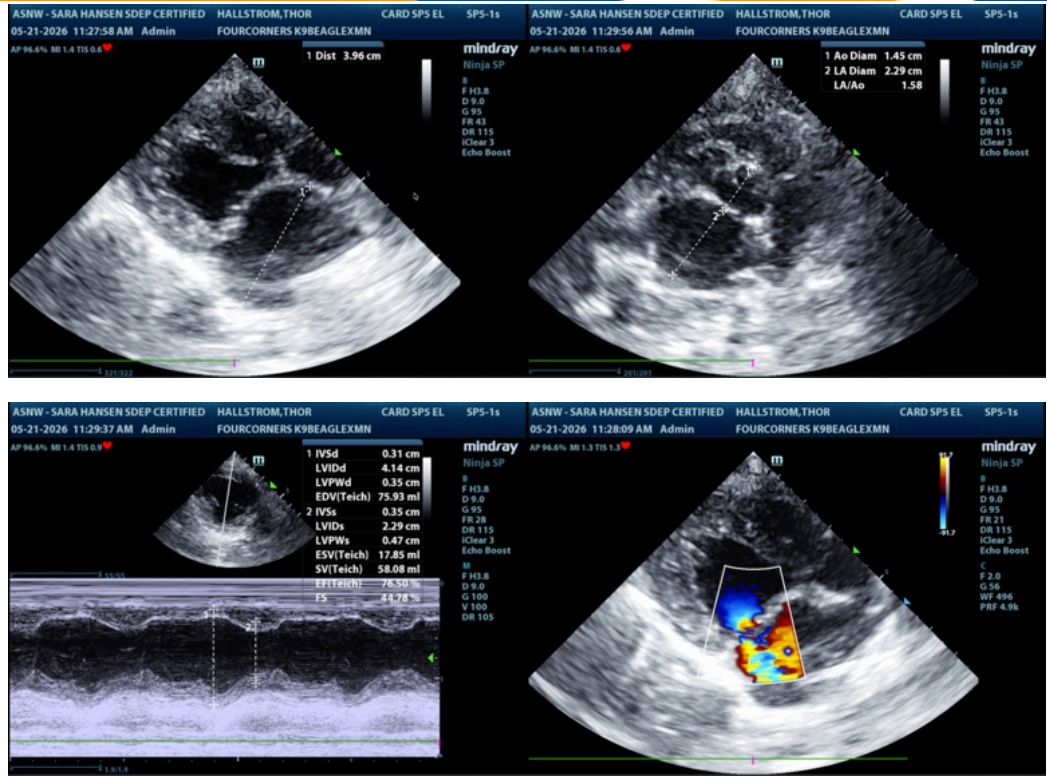
Dr. Sinkowski

**INVOICE**

77827

**DATE**

5/21/26



The information and recommendations provided are based on the images presented by the referring veterinarian/sonographer. No evaluation can be communicated regarding pathology that was not visible in the image/video clips provided.

Thank you for this referral. If the clinical or image interpretation does not parallel your findings or if I can be of any further assistance please contact me.

Bradley Harris, DVM, DACVECC, DACVIM (cardiology)

[info@SonoPath.com](mailto:info@SonoPath.com)