

PATIENT

James Bell

SPECIES

Canine

BREED

Vizsla

SEX

Neutered male

AGE

12 years

WEIGHT

69 lbs

INTERPRETED BY

Bradley Harris, DVM,
DACVECC, DACVIM
(cardiology)

IMAGING PERFORMED BY

Sara Hansen

HOSPITAL NAME

Animal Care Center

REFERRING VET

Dr. Rigling

INVOICE

PRESENTING CLINICAL SIGNS

Clinical Exam Findings: (3/6) L systolic Heart murmur and arrhythmia - (multiple VPCs seen on ECG 4/24/26). Heart failure/congestion, neoplasia (primary vs metastatic), old dog liver/hepatitis, secondary to NSAID use, copper storage disease, open.
4/17/26 Senior profile - mild elevations in ALKP (166) and ALT (164) along with cholesterol (404, no change in the past year).
Grade 3/6 L systolic murmur
Current Medications Galliprant 60mg: 1 tablet Q24 PRN for pain

ULTRASONOGRAPHIC EXAMINATION OF THE HEART

The left atrium is upper limits of normal in dimension. The left ventricle is also upper limits of normal, with normal systolic function. The right atrium and ventricle are normal in dimension, with normal systolic function. The anterior and posterior mitral valve leaflets are thickened and redundant consistent with myxomatous changes, and there is minimal prolapse. There is mild mitral regurgitation identified. The tricuspid valve leaflets are appropriately thin with adequate apposition, intact chordae, no significant tricuspid regurgitation and no evidence of pulmonary hypertension. The left ventricular outflow tract demonstrated normal laminar flow and the visible aorta is unremarkable. The right ventricular outflow tract assessment revealed normal laminar flow, with appropriate main pulmonary artery diameter and right pulmonary artery distensibility. There is no pulmonic and no aortic valve insufficiency identified. There is no visible pericardial, pleural, or free peritoneal fluid documented. No evidence of hepatic venous congestion is noted. The cardiac chambers, pericardial and visible extra-cardiac regions were free of masses, spontaneous echo contrast, or thrombi.

CANINE CARDIAC PARAMETERS	Body Weight kg	HR BPM	LAD 4 ch Long	RAD 4 ch Long	La/Ao Heart Base	LVIDd	LVIDs
NORMAL PARAMETER		50-100			<1.6		
PATIENT	31.36	180	4.74	2.6	1.22	4.81	2.36
CANINE CARDIAC PARAMETERS	FS	EPSS	PV V MAX (m/s)	AV V Max (m/sec)	MR Vmax	TR Vmax	RPA distensibility (normal >30%)
NORMAL PARAMETER	28-40	<0.6	0.7-1.6	0.7-1.7	4.5-5.5	< 2.7	
PATIENT	51	NM	1.3	1.9	6.6	Not present	25

ECG:

The underlying rhythm is sinus in origin with a regular R-R interval and average heart rate of 180bpm. The majority of the QRS complexes are supraventricular in origin with consistent P-Q intervals. There are rare QRS complexes that are prolonged in duration (>70ms), suggesting a ventricular origin. There is no evidence of atrioventricular block or atrial ectopy identified. This is most consistent with a normal sinus tachycardia with rare ventricular ectopy.

DATE

4/30/26



PATIENT

James Bell

SPECIES

Canine

BREED

Vizsla

SEX

Neutered male

AGE

12 years

WEIGHT

69 lbs

INTERPRETED BY

Bradley Harris, DVM,
DACVECC, DACVIM
(cardiology)

IMAGING PERFORMED BY

Sara Hansen

HOSPITAL NAME

Animal Care Center

REFERRING VET

Dr. Rigling

INVOICE

DATE

4/30/26

ULTRASONOGRAPHIC FINDINGS

These findings are consistent with degenerative/myxomatous mitral valve disease with minimal to mild hemodynamic effects consistent with ACVIM Stage B1 disease. Ventricular arrhythmias occur in many clinical settings, generally divided into cardiac and non-cardiac causes. Cardiac conditions include structural heart disease, pericardial effusion/cardiac neoplasia, and rarely myocarditis. Non-cardiac causes are common and include splenic disease, metabolic disease, electrolyte disturbances, tick-borne disease, fever, anemia, trauma, GDV, hepatic disease, GI disease, pancreatitis, DIC, and sepsis.

INTERPRETATION OF THE FINDINGS & FURTHER RECOMMENDATIONS

Given these findings, no cardiac therapy is recommended. There are no cardiac contraindications to anesthesia, fluid therapy, vasopressor therapy, or corticosteroids as indicated for further assessment and treatment. If not already performed, baseline thoracic radiographs and blood pressure are recommended. A recheck echocardiogram is recommended in 6 months. While therapy for the dysrhythmia is not specifically indicated based on these findings, further diagnostics might help tailor therapeutic recommendations. Consider the following:

- Abdominal ultrasound to look for abdominal causes of VPCs (e.g., splenic/adrenal changes)
- Consider 24-48 hour ambulatory ECG (Holter) monitor to assess significance of arrhythmia

Anesthesia considerations:

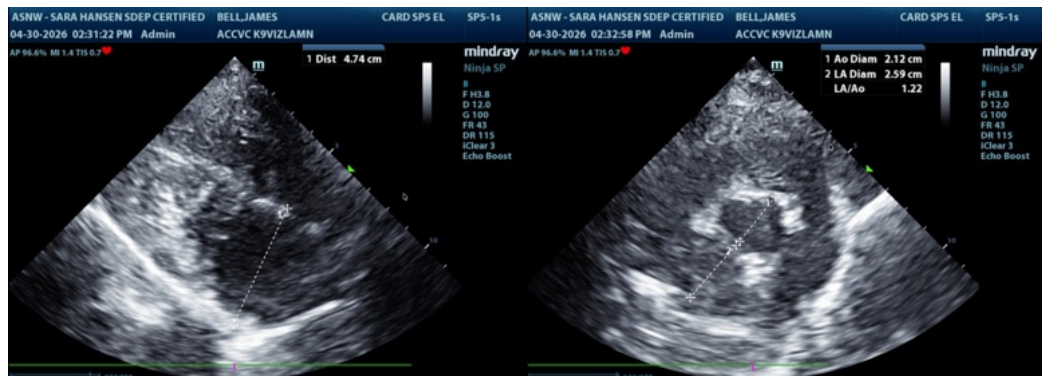
If anesthesia is necessary, alpha-2 agonists, ketamine, high dose acepromazine, and Telazol should be avoided. Fluid therapy during anesthesia should be considered at a conservative rate (e.g., 5 ml/kg/hour) if possible.

Diet:

A high-quality food from Hills, Royal Canin, Science Diet, Eukanuba, Iams, or Purina that is highly palatable with adequate protein and calories for maintaining optimal body condition is reasonable.

Activity:

No special considerations are necessary.





PATIENT

James Bell

SPECIES

Canine

BREED

Vizsla

SEX

Neutered male

AGE

12 years

WEIGHT

69 lbs

INTERPRETED BY

Bradley Harris, DVM,
 DACVECC, DACVIM
 (cardiology)

IMAGING PERFORMED BY

Sara Hansen

HOSPITAL NAME

Animal Care Center

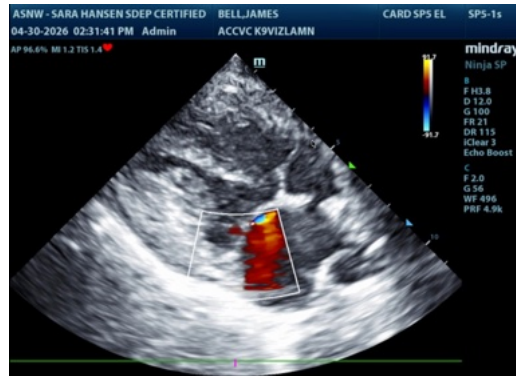
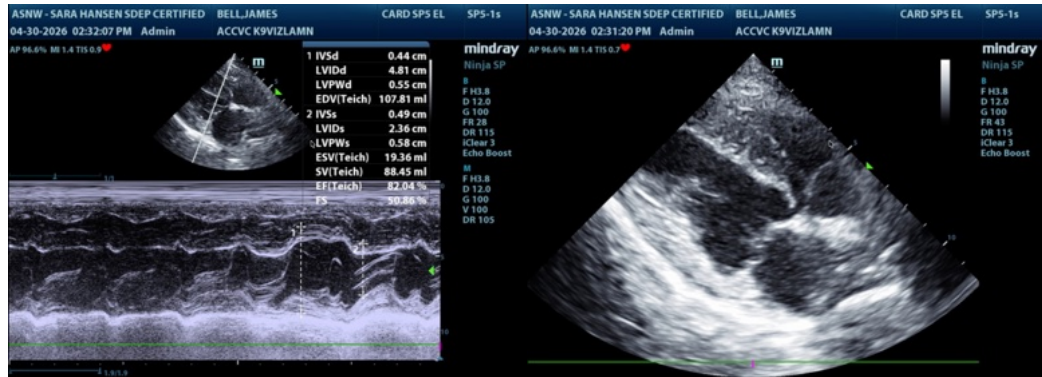
REFERRING VET

Dr. Rigling

INVOICE

DATE

4/30/26



The information and recommendations provided are based on the images presented by the referring veterinarian/sonographer. No evaluation can be communicated regarding pathology that was not visible in the image/video clips provided.

Thank you for this referral. If the clinical or image interpretation does not parallel your findings or if I can be of any further assistance please contact me.

Bradley Harris, DVM, DACVECC, DACVIM (cardiology)

info@SonoPath.com