



**PATIENT**

Morley Mickelson

**SPECIES**

Canine

**BREED**

Standard Poodle

**SEX**

Neutered male

**AGE**

10 years

**WEIGHT**

52.4 lbs

**INTERPRETED BY**

Bradley Harris, DVM,  
DACVECC, DACVIM  
(cardiology)

**IMAGING PERFORMED BY**

Sara Hansen

**HOSPITAL NAME**

West Hills AH

**REFERRING VET**

Dr. Cole

**INVOICE**

73839

**DATE**

3/27/26

**PRESENTING CLINICAL SIGNS**

Clinical Exam Findings: Persistent cough, elevated probnp 10/25. Radiographically normal chest rads 10/25  
 ABNORMAL Labwork Values Probnp 1019  
 Current Medications Heartguard and Nexguard Monthly  
 Radiographic Findings 1. The thorax is normal. There is no radiographic evidence of cardiac disease. However, this does not exclude the possibility of underlying pathology in this organ. The patient is not in heart failure.2. The abdomen is normal.3. The pelvis and visible portions of the pelvic limbs are also normal.

**ULTRASONOGRAPHIC EXAMINATION OF THE HEART**

The left atrium is normal in dimension. The left ventricle is normal in dimension with normal systolic function. The right atrium and ventricle are normal in dimension with normal systolic function. The anterior and posterior mitral valve leaflets are thickened and redundant consistent with myxomatous changes, and there is no significant prolapse. There is trivial mitral regurgitation identified. The tricuspid valve leaflets are appropriately thin with adequate apposition and intact chordae, with no significant tricuspid regurgitation and no evidence of pulmonary hypertension. The left ventricular outflow tract demonstrated normal laminar flow and the visible aorta is unremarkable. The right ventricular outflow tract assessment revealed normal laminar flow with appropriate main pulmonary artery diameter and right pulmonary artery distensibility. There is no pulmonic and no aortic valve insufficiency identified. There is no visible pericardial, pleural, or free peritoneal fluid documented. No evidence of hepatic venous congestion is noted. The cardiac chambers, pericardial, and visible extra-cardiac regions were free of masses, spontaneous echo contrast, or thrombi.

CANINE CARDIAC PARAMETERS	Body Weight kg	HR BPM	LAD 4 ch Long	RAD 4 ch Long	La/Ao Heart Base	LVIDd	LVIDs
NORMAL PARAMETER		50-100			<1.6		
PATIENT	23.82 kg	NM	4.3	3.11	1.02	4.4	2.92
CANINE CARDIAC PARAMETERS	FS	EPSS	PV V MAX (m/s)	AV V Max (m/sec)	MR Vmax	TR Vmax	RPA distensibility (normal >30%)
NORMAL PARAMETER	28-40	<0.6	0.7-1.6	0.7-1.7	4.5-5.5	< 2.7	
PATIENT	34	0.3	0.9	1.3	6.0	NM	NM

**ECG:**

There is a six-lead ECG with severe baseline artifact available for review. The underlying rhythm appears regular with narrow QRS complexes. There is no overt atrial or ventricular ectopy and no conduction delay or block identified. This is most consistent with a normal sinus rhythm.



**PATIENT**

Morley Mickelson

**SPECIES**

Canine

**BREED**

Standard Poodle

**SEX**

Neutered male

**AGE**

10 years

**WEIGHT**

52.4 lbs

**INTERPRETED BY**

Bradley Harris, DVM,  
DACVECC, DACVIM  
(cardiology)

**IMAGING PERFORMED BY**

Sara Hansen

**HOSPITAL NAME**

West Hills AH

**REFERRING VET**

Dr. Cole

**INVOICE**

73839

**DATE**

3/27/26

**ULTRASONOGRAPHIC FINDINGS**

These findings are consistent with degenerative/myxomatous mitral valve disease with minimal to mild hemodynamic effects consistent with ACVIM Stage B1 disease. It is unlikely that any current morbidity is of cardiac origin.

**INTERPRETATION OF THE FINDINGS & FURTHER RECOMMENDATIONS**

Given these findings, no cardiac therapy is recommended. There are no cardiac contraindications to anesthesia, fluid therapy, vasopressor therapy, or corticosteroids as indicated for further assessment and treatment. If not already performed, baseline thoracic radiographs and blood pressure are recommended. A recheck echocardiogram is recommended in 6 months.

Anesthesia considerations:

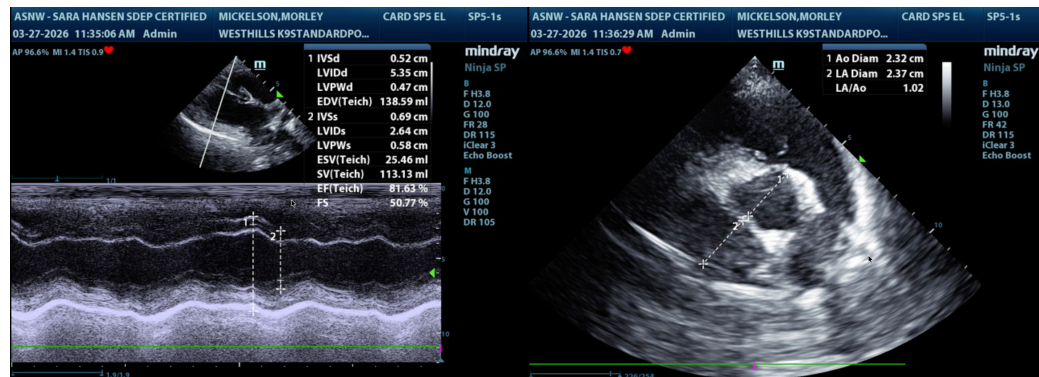
If anesthesia is necessary, alpha-2 agonists, ketamine, high dose acepromazine, and Telazol should be avoided. Fluid therapy during anesthesia should be considered at a conservative rate (e.g., 5 ml/kg/hour) if possible.

Diet:

A high-quality food from Hills, Royal Canin, Science Diet, Eukanuba, Iams, or Purina that is highly palatable with adequate protein and calories for maintaining optimal body condition is reasonable.

Activity:

No special considerations are necessary.





**PATIENT**

Morley Mickelson

**SPECIES**

Canine

**BREED**

Standard Poodle

**SEX**

Neutered male

**AGE**

10 years

**WEIGHT**

52.4 lbs

**INTERPRETED BY**

Bradley Harris, DVM,  
 DACVECC, DACVIM  
 (cardiology)

**IMAGING PERFORMED BY**

Sara Hansen

**HOSPITAL NAME**

West Hills AH

**REFERRING VET**

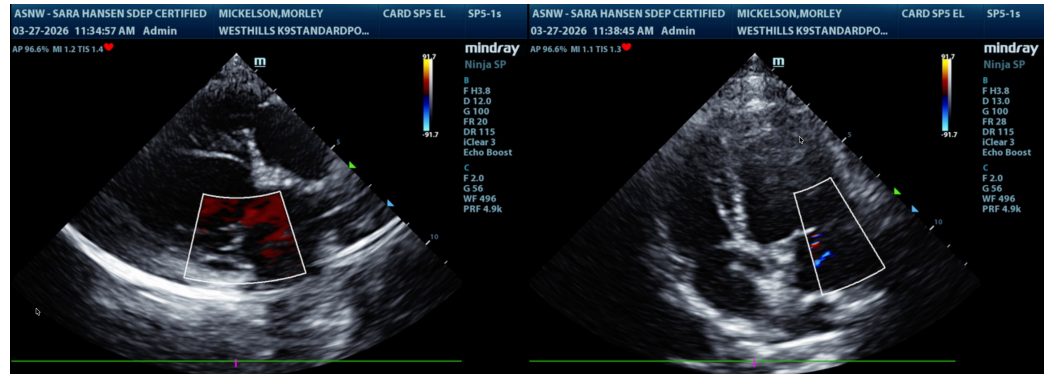
Dr. Cole

**INVOICE**

73839

**DATE**

3/27/26



The information and recommendations provided are based on the images presented by the referring veterinarian/sonographer. No evaluation can be communicated regarding pathology that was not visible in the image/video clips provided.

Thank you for this referral. If the clinical or image interpretation does not parallel your findings or if I can be of any further assistance please contact me.

Bradley Harris, DVM, DACVECC, DACVIM (cardiology)

[info@SonoPath.com](mailto:info@SonoPath.com)