

PATIENT

Hypfee Johnson

SPECIES

Feline

BREED

Domestic Longhair

SEX

Spayed female

AGE

19 year

WEIGHT

7.4 lbs

INTERPRETED BY

Bradley Harris, DVM,
 DACVECC, DACVIM
 (cardiology)

IMAGING PERFORMED BY

Rebecca Hamilton

HOSPITAL NAME

Edgewood Animal
 Clinic Oregon

REFERRING VET

Dr. Leduc

INVOICE

73445

DATE

3/12/26

PRESENTING CLINICAL SIGNS

- Auscultation of heart very arrhythmic. historical abnormal BNP and gallop rhythm
- Meds: Gabapentin 10 mg q 12 hours
- HR 180, RR 60, no current labwork

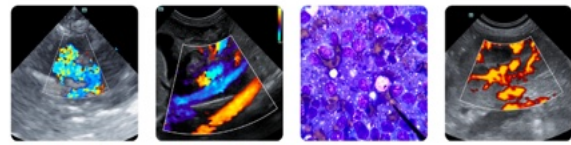
ULTRASONOGRAPHIC EXAMINATION OF THE HEART

The left atrium is severely enlarged. There are no distinct left atrial thrombi/clots or spontaneous echo contrast appreciated. The left ventricle is normal in dimension, with concentric hypertrophy, and no evidence of restriction. Left ventricular systolic function is reduced, with decreased contractility. The right atrium and ventricle are subjectively normal in dimension and systolic function. The anterior and posterior mitral and tricuspid valve leaflets presented normal linear structure, extension in systole, and there is mild central mitral regurgitation. There is no evidence of systolic anterior mitral motion documented. The left ventricular outflow tract demonstrated normal laminar flow and subjective structural valvular integrity. The visible aorta is unremarkable. Pulmonary outflow tract assessment revealed normal valve structure, laminar flow, and appropriate diameter and distensibility. There is no evidence of semilunar valve insufficiency or pulmonary hypertension documented. There is no pericardial or pleural, but mild free peritoneal fluid is noted.

FELINE CARDIAC PARAMETERS	BODY WEIGHT (kg)	HR (BPM)	IVSd (cm)	LVIDd (cm)	LVWd (cm)	FS (%)	EF (%)
NORMAL PARAMETER	-----	150-240	0.3-0.6	1.0-2.1	0.25-0.6	35-67	80-100
PATIENT	3.36	210	0.67	1.5	0.61	12	NM
FELINE CARDIAC PARAMETERS	LA/AO (M-mode)	LA/AO HEART BASE (Sisson)	LAD LA MAX 4 Chamber		LVOT VEL. (m/s)	RVOT VEL. (m/s)	IVRT (m/)
NORMAL PARAMETER	<1.5	1.6	0.7-1.7		<1.6	<1.3	40-60
PATIENT	1.89	2.8	2.21		0.8	0.6	NM
Adapted from June Boon, Veterinary Echocardiography, 1998							
Sisson D et al. JVIM 1991; 5: 232, Jacobs et al. Am J Vet Res 1985; 46:1705							

ECG:

There is a six-lead ECG available for review. The underlying rhythm is regular at an average rate of 210bpm. There is a mean electrical axis deviation consistent with left ventricular hypertrophy. The rhythm appears to be sinus in origin with narrow QRS complexes. There is no atrial or ventricular ectopy and no conduction delay or block identified. This is most consistent with a normal sinus tachycardia.



PATIENT

Hypfee Johnson

SPECIES

Feline

BREED

Domestic Longhair

SEX

Spayed female

AGE

19 year

WEIGHT

7.4 lbs

INTERPRETED BY

Bradley Harris, DVM,
 DACVECC, DACVIM
 (cardiology)

IMAGING PERFORMED BY

Rebecca Hamilton

HOSPITAL NAME

Edgewood Animal
 Clinic Oregon

REFERRING VET

Dr. Leduc

INVOICE

73445

DATE

3/12/26

ULTRASONOGRAPHIC FINDINGS

These findings identify LV hypertrophy, in the absence of an outflow tract obstruction, consistent with hypertrophic cardiomyopathy (HCM). The presence of significant left atrial dilation makes CHF a likely explanation for the clinical/radiographic signs.

INTERPRETATION OF THE FINDINGS & FURTHER RECOMMENDATIONS

Therapy for CHF is indicated, to include Lasix (2mg/kg BID), Vetmedin (0.25-0.35mg/kg BID), and enalapril (0.5mg/kg q24, assuming normal blood pressure and kidney function). A systemic blood pressure and thyroid panel (to include a total T4 and free T4 by ED) are recommended to rule out systemic hypertension and hyperthyroidism as a cause for the left ventricular hypertrophy, respectively. If normal, then the left ventricular hypertrophy is secondary to primary hypertrophic cardiomyopathy. A repeat evaluation is recommended in 1-2 weeks, at which time the blood pressure, chemistry, thoracic radiographs should be repeated. At that time, the addition of Plavix (18.75mg q24) +/- rivaroxaban (2.5mg q24) is recommended. Due to the bitter taste of this medication, it may be best to place it in an empty gelatin capsule or use products such as a Pill Pocket. A repeat echocardiogram, blood pressure, chemistry, and thoracic radiographs are indicated in another 3-6 months, or sooner if the condition worsens.

Anesthesia considerations:

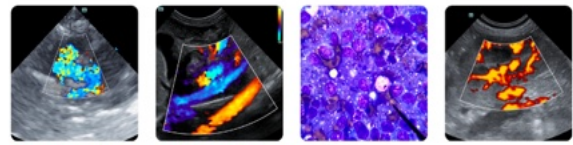
Anesthesia should be avoided until signs of congestion have resolved. If anesthesia is necessary, then alpha-2 agonists, ketamine, high dose acepromazine, and Telazol should be avoided. If an ACE inhibitor (enalapril, benazepril) or spironolactone is being given, it should not be administered on the morning of general anesthesia. Other cardiac medications should be administered per the normal dosing schedule. Anesthetic IV fluid use should be limited to < 3 ml/kg/hr and, if IV fluid therapy is administered during the procedure, a 1 mg/kg dose of IM Lasix should be administered when the patient is awake and standing in recovery. A shorter anesthetic duration will reduce the risk of complications. Pre-oxygenation is advised. Premedication with an opioid (i.e., butorphanol, hydromorphone, oxymorphone) with or without a benzodiazepine is generally the safest protocol. An induction agent such as Propofol, alfaxalone, or diazepam/etomidate can be used to effect. Maintenance of anesthesia with isoflurane or sevoflurane is reasonable.

Diet:

A high-quality food from Hills, Royal Canin, Science Diet, Eukanuba, Iams, or Purina that is highly palatable with adequate protein and calories for maintaining optimal body condition with mild dietary sodium restriction (<100 mg/100 kcal) is recommended. Consider omega-3 fatty acid supplementation.

Activity:

Avoid strenuous activity



PATIENT

Hypfee Johnson

SPECIES

Feline

BREED

Domestic Longhair

SEX

Spayed female

AGE

19 year

WEIGHT

7.4 lbs

INTERPRETED BY

Bradley Harris, DVM,
 DACVECC, DACVIM
 (cardiology)

IMAGING PERFORMED BY

Rebecca Hamilton

HOSPITAL NAME

Edgewood Animal
 Clinic Oregon

REFERRING VET

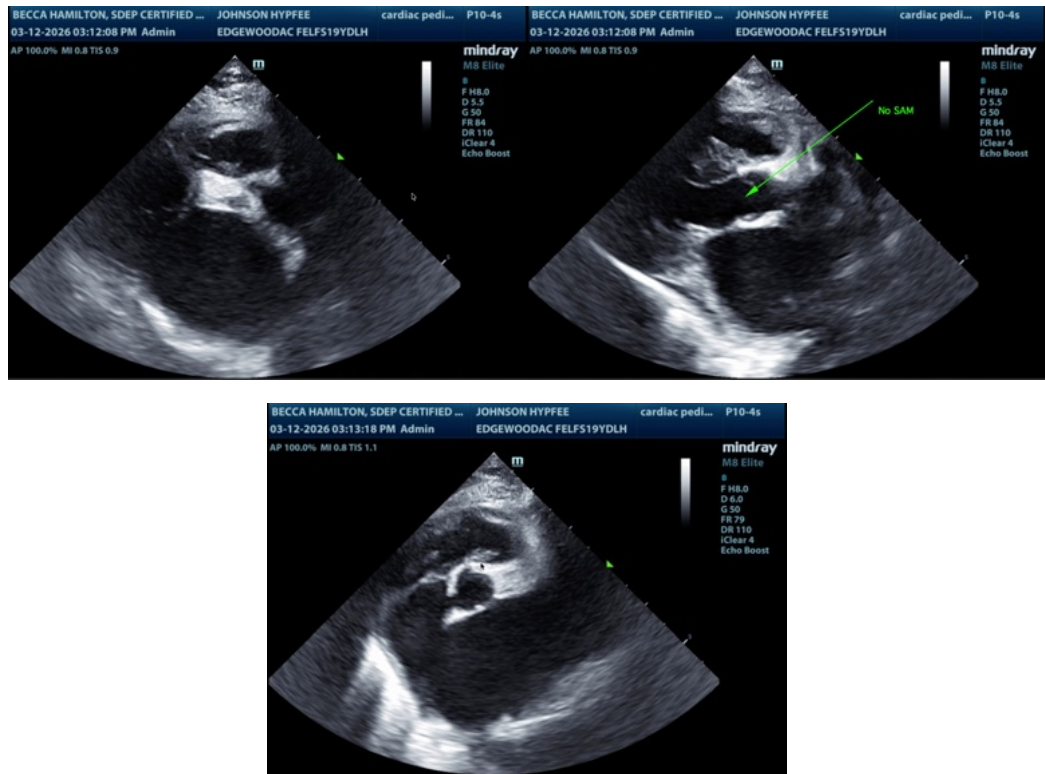
Dr. Leduc

INVOICE

73445

DATE

3/12/26



The information and recommendations provided are based on the images presented by the referring veterinarian/sonographer. No evaluation can be communicated regarding pathology that was not visible in the image/video clips provided.

Thank you for this referral. If the clinical or image interpretation does not parallel your findings or if I can be of any further assistance please contact me.

Bradley Harris, DVM, DACVECC, DACVIM (cardiology)

info@SonoPath.com