



PATIENT

Drogo Johnson

SPECIES

Canine

BREED

Irish Wolfhound

SEX

Intact male

AGE

10 years

WEIGHT

120 lbs

INTERPRETED BY

Bradley Harris, DVM,
 DACVECC, DACVIM
 (cardiology)

IMAGING PERFORMED BY

Yvonna Aranda

HOSPITAL NAME

The Veterinary Hospital

REFERRING VET

Dr. Johnson

INVOICE

68385

DATE

11/6/25

PRESENTING CLINICAL SIGNS

History: Clinical Exam Findings: abnormal testicle -presumed neoplasia. surgery scheduled for 11/7
 QOL is good and general physical is otherwise normal, some hind end weakness clinically he seems
 cardiac normal, runs about 3 miles twice a week
 ABNORMAL Labwork Values cardio BNP elevated at 995 CBC/Chem. UA otherwise WNL For ECHO
 Only: Blood Pressure 147/94 (and anxious) HR/RR/BP: HR 96. BP 147/94 Is there a Heart Murmur? If
 so, please grade. no Current Medications Chinies herbal mobility support (hind quarter weakness and
 body sore), occasional Rimadyl

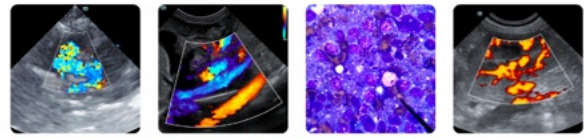
ULTRASONOGRAPHIC EXAMINATION OF THE HEART

The left atrium is upper limits of normal in dimension. The left ventricle is normal in dimension with normal systolic function. The right atrium and ventricle are subjectively normal in dimension and systolic function. The mitral valve is thickened and redundant consistent with myxomatous changes, and there is no significant prolapse. There is evidence of moderate mitral regurgitation. The tricuspid valve leaflets are subjectively normal with no tricuspid regurgitation and no evidence of pulmonary hypertension. The left ventricular outflow tract demonstrated normal laminar flow and the visible aorta is unremarkable. The right ventricular outflow tract assessment revealed normal laminar flow, and appropriate diameter and distensibility. There is no evidence of semilunar valve insufficiency. There is no visible pericardial, pleural, or free peritoneal fluid noted. The cardiac chambers, pericardial and visible extra-cardiac regions were free of masses, spontaneous echo contrast, or thrombi.

CANINE CARDIAC PARAMETERS	Body Weight kg	HR BPM	LAD 4 ch Long	RAD 4 ch Long	La/Ao Heart Base	LVIDd	LVIDs
NORMAL PARAMETER		50-100			<1.6		
PATIENT	54.55	150	5.8	3.56	1.38	4.76	3.78
CANINE CARDIAC PARAMETERS	FS	EPSS	PV V MAX (m/s)	AV V Max (m/sec)	MR Vmax	TR Vmax	RPA distensibility (normal >30%)
NORMAL PARAMETER	28-40	<0.6	0.7-1.6	0.7-1.7	4.5-5.5	< 2.7	
PATIENT	21	0.4	1.1	1.2	5.8	NM	32

ULTRASONOGRAPHIC FINDINGS

These findings are consistent with degenerative/myxomatous mitral valve disease with minimal to mild hemodynamic effects consistent with ACVIM Stage B1 disease. It is unlikely that any current morbidity is of cardiac origin.



PATIENT

Drogo Johnson

SPECIES

Canine

BREED

Irish Wolfhound

SEX

Intact male

AGE

10 years

WEIGHT

120 lbs

INTERPRETED BY

Bradley Harris, DVM,
 DACVECC, DACVIM
 (cardiology)

IMAGING PERFORMED BY

Yvonna Aranda

HOSPITAL NAME

The Veterinary
 Hospital

REFERRING VET

Dr. Johnson

INVOICE

68385

DATE

11/6/25

INTERPRETATION OF THE FINDINGS & FURTHER RECOMMENDATIONS

Given these findings, no cardiac therapy is recommended. There are no cardiac contraindications to anesthesia, fluid therapy, vasopressor therapy, or corticosteroids as indicated for further assessment and treatment. If not already performed, baseline thoracic radiographs and blood pressure are recommended. A recheck echocardiogram is recommended in 6 months.

Anesthesia considerations:

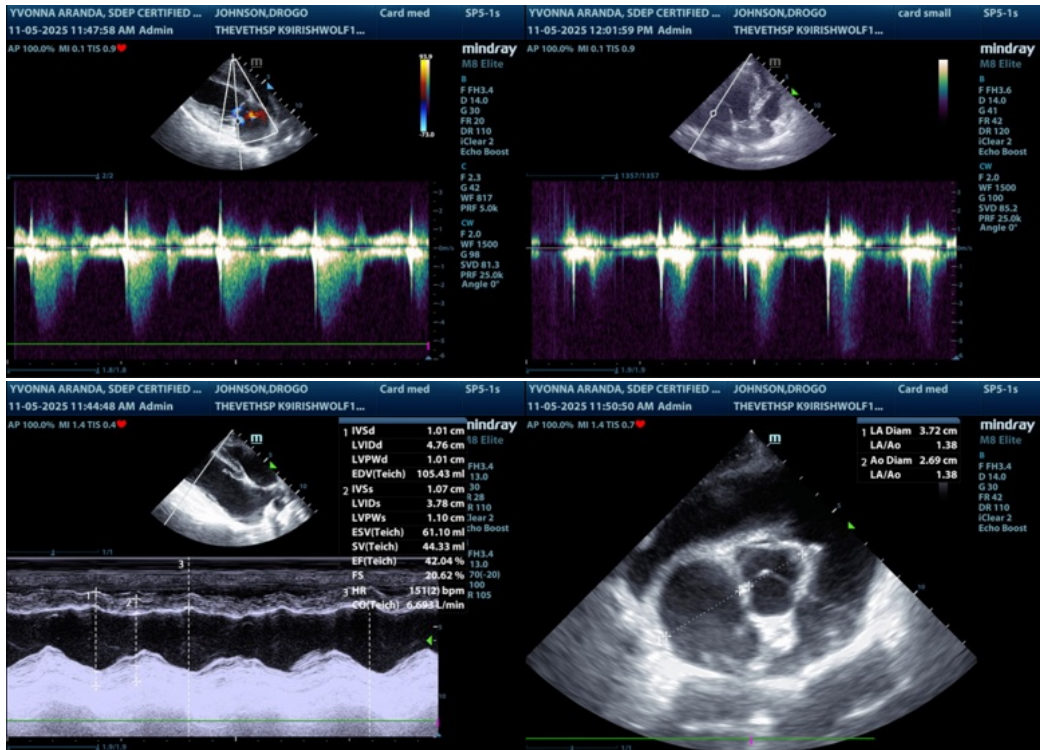
If anesthesia is necessary, alpha-2 agonists, ketamine, high dose acepromazine, and Telazol should be avoided. Fluid therapy during anesthesia should be considered at a conservative rate (e.g., 5 ml/kg/hour) if possible.

Diet:

A high-quality food from Hills, Royal Canin, Science Diet, Eukanuba, Iams, or Purina that is highly palatable with adequate protein and calories for maintaining optimal body condition is reasonable.

Activity:

No special considerations are necessary





PATIENT

Drogo Johnson

SPECIES

Canine

BREED

Irish Wolfhound

SEX

Intact male

AGE

10 years

WEIGHT

120 lbs

INTERPRETED BY

Bradley Harris, DVM,
 DACVECC, DACVIM
 (cardiology)

IMAGING PERFORMED BY

Yvonna Aranda

HOSPITAL NAME

The Veterinary
 Hospital

REFERRING VET

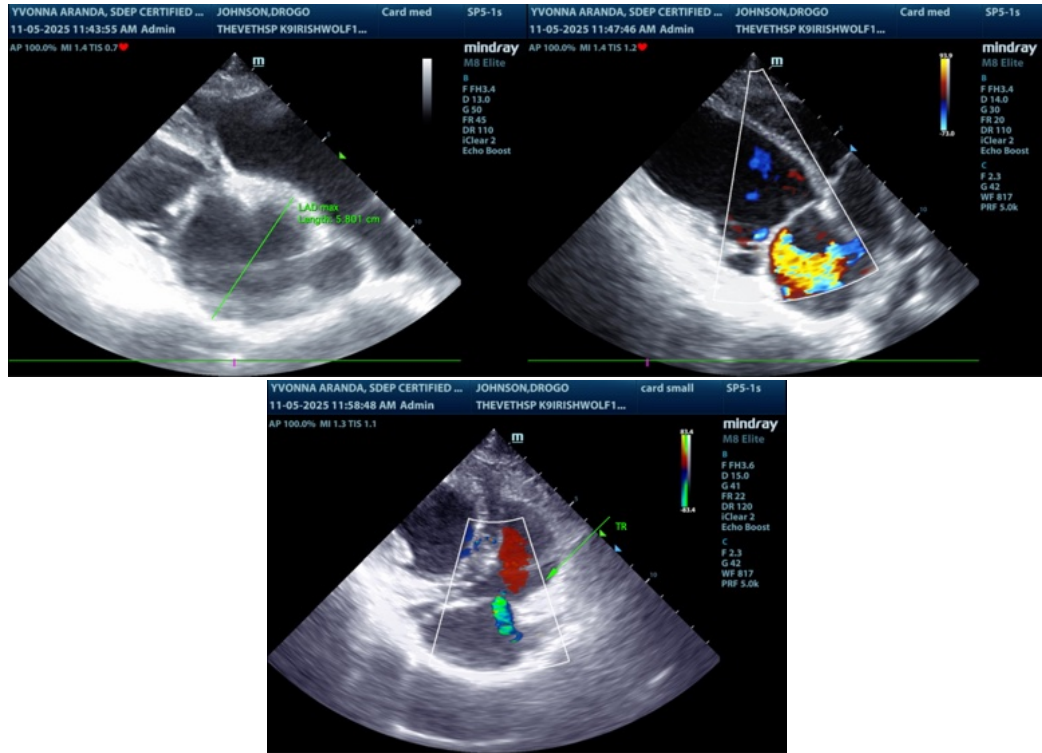
Dr. Johnson

INVOICE

68385

DATE

11/6/25



The information and recommendations provided are based on the images presented by the referring veterinarian/sonographer. No evaluation can be communicated regarding pathology that was not visible in the image/video clips provided.

Thank you for this referral. If the clinical or image interpretation does not parallel your findings or if I can be of any further assistance please contact me.

Bradley Harris, DVM, DACVECC, DACVIM (cardiology)

info@SonoPath.com