



PATIENT

Thor Knight

SPECIES

Canine

BREED

Cavapoo

SEX

Neutered male

AGE

12 ½ years

WEIGHT

40 lbs

INTERPRETED BY

Bradley Harris, DVM,
DACVECC, DACVIM
(cardiology)

IMAGING PERFORMED BY

Dr. Sorbo

HOSPITAL NAME

JMPet Resort and Vet
Clinic

REFERRING VET

Dr. Sorbo

INVOICE

78406

DATE

6/8/26

PRESENTING CLINICAL SIGNS

History: Historical murmur since puppyhood. Had AUS last week - see report by MD:

ULTRASONOGRAPHIC FINDINGS

- Non-homogeneous subtle nodular liver
- Mild gallbladder debris (non-mucocele)
- Mild age-related kidneys
- Bilateral mild enlarged nonhomogeneous adrenal glands – subjective benign
- Sonographically normal area of pancreas
- Gastrointestinal ingesta – consistent with food echogenicity

Came in today for US-guided FNA - five samples taken. Persistent murmur investigation added on today, but also to investigate possible cardiovascular component to LFT elevation.

Abnormal PE/Chem/CBC/UA Results: Grade V/VI early systolic to diastolic murmur PMI LHB. BP 146mmHg - performed under butorphanol sedation on top of trazodone and gabapentin PVP.

ULTRASONOGRAPHIC EXAMINATION OF THE HEART

The left atrium is normal in dimension. The left ventricle is normal in dimension, with normal systolic function. The right atrium and ventricle are normal in dimension, with normal systolic function. The anterior and posterior mitral valve leaflets are thickened and redundant consistent with myxomatous changes, and minimal prolapse. There is mild mitral regurgitation identified. The tricuspid valve leaflets are minimally thickened, with trivial tricuspid regurgitation and no evidence of pulmonary hypertension. The left ventricular outflow tract demonstrated normal laminar flow and the visible aorta is unremarkable. The right ventricular outflow tract assessment revealed normal laminar flow, with appropriate main pulmonary artery diameter and right pulmonary artery distensibility. There is no pulmonic and no aortic valve insufficiency identified. There is no visible pericardial, pleural, or free peritoneal fluid documented. No evidence of hepatic venous congestion is noted. The cardiac chambers, pericardial and visible extra-cardiac regions were free of masses, spontaneous echo contrast, or thrombi.

CANINE CARDIAC PARAMETERS	Body Weight kg	HR BPM	LAD 4 ch Long	RAD 4 ch Long	La/Ao Heart Base	LVIDd	LVIDs
NORMAL PARAMETER		50-100			<1.6		
PATIENT	18.18 kg	NM	3.79	2.59	1.45	3.37	2.06
CANINE CARDIAC PARAMETERS	FS	EPSS	PV V MAX (m/s)	AV V Max (m/sec)	MR Vmax	TR Vmax	RPA distensibility (normal >30%)
NORMAL PARAMETER	28-40	<0.6	0.7-1.6	0.7-1.7	4.5-5.5	< 2.7	
PATIENT	39	NM	1.2	2.0	4.5	NM	NM

ULTRASONOGRAPHIC FINDINGS

These findings are consistent with degenerative/myxomatous mitral valve disease with minimal to mild hemodynamic effects consistent with ACVIM Stage B1 disease. It is unlikely that any current morbidity is of cardiac origin.



PATIENT

Thor Knight

SPECIES

Canine

BREED

Cavapoo

SEX

Neutered male

AGE

12 ½ years

WEIGHT

40 lbs

INTERPRETED BY

Bradley Harris, DVM,
DACVECC, DACVIM
(cardiology)

IMAGING PERFORMED BY

Dr. Sorbo

HOSPITAL NAME

JMPet Resort and Vet
Clinic

REFERRING VET

Dr. Sorbo

INVOICE

78406

DATE

6/8/26

INTERPRETATION OF THE FINDINGS & FURTHER RECOMMENDATIONS

Given these findings, no cardiac therapy is recommended. There are no cardiac contraindications to anesthesia, fluid therapy, vasopressor therapy, or corticosteroids as indicated for further assessment and treatment. If not already performed, baseline thoracic radiographs and blood pressure are recommended. A recheck echocardiogram is recommended in 6 months.

Anesthesia considerations:

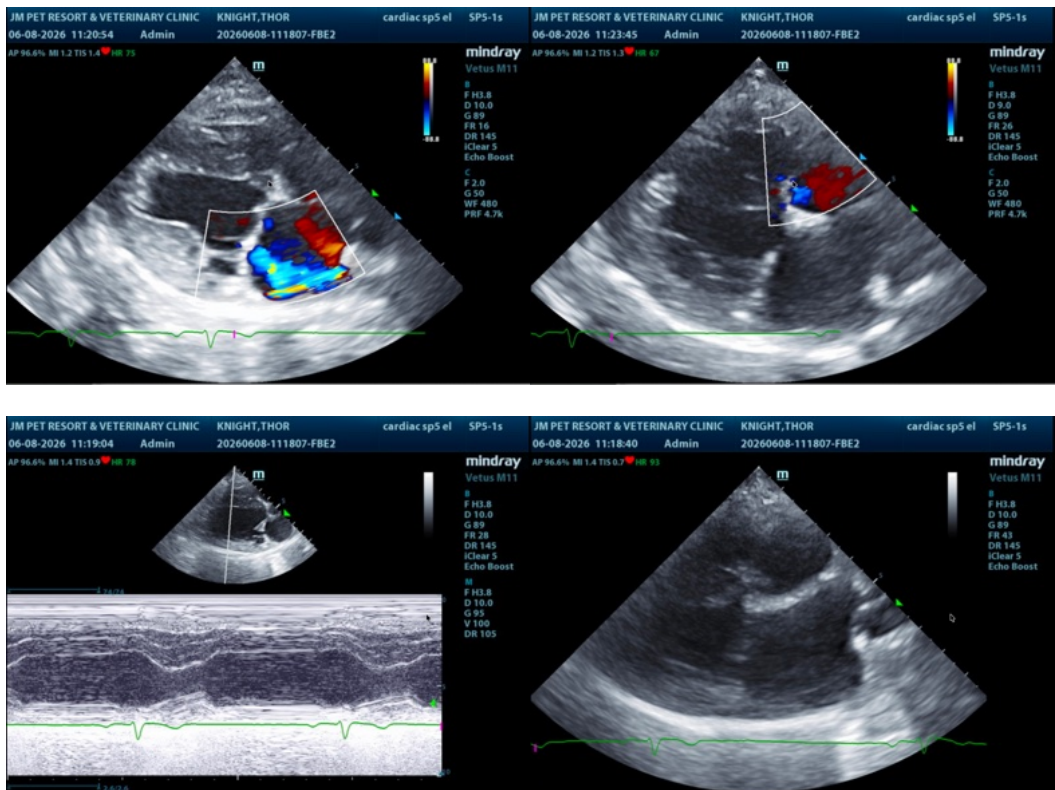
If anesthesia is necessary, alpha-2 agonists, ketamine, high dose acepromazine, and Telazol should be avoided. Fluid therapy during anesthesia should be considered at a conservative rate (e.g., 5 ml/kg/hour) if possible.

Diet:

A high-quality food from Hills, Royal Canin, Science Diet, Eukanuba, Iams, or Purina that is highly palatable with adequate protein and calories for maintaining optimal body condition is reasonable.

Activity:

No special considerations are necessary.





PATIENT

Thor Knight

SPECIES

Canine

BREED

Cavapoo

SEX

Neutered male

AGE

12 ½ years

WEIGHT

40 lbs

INTERPRETED BY

Bradley Harris, DVM,
DACVECC, DACVIM
(cardiology)

IMAGING PERFORMED BY

Dr. Sorbo

HOSPITAL NAME

JMPet Resort and Vet
Clinic

REFERRING VET

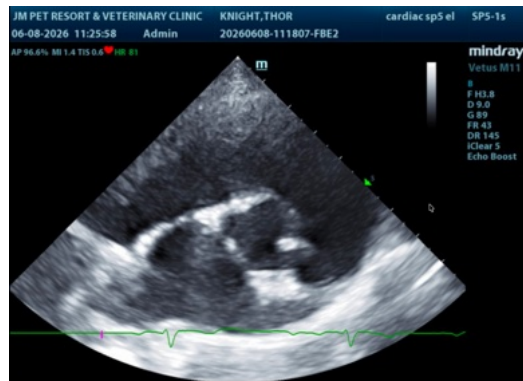
Dr. Sorbo

INVOICE

78406

DATE

6/8/26



The information and recommendations provided are based on the images presented by the referring veterinarian/sonographer. No evaluation can be communicated regarding pathology that was not visible in the image/video clips provided.

Thank you for this referral. If the clinical or image interpretation does not parallel your findings or if I can be of any further assistance please contact me.

Bradley Harris, DVM, DACVECC, DACVIM (cardiology)

info@SonoPath.com