

PATIENT

Rio Kew

SPECIES

Canine

BREED

Korean Village Dog

SEX

Neutered Male

AGE

11 Years

WEIGHT

7.5 kg

INTERPRETED BY

Bradley Harris, DVM,
 DACVECC, DACVIM
 (cardiology)

IMAGING PERFORMED BY

Crystal Hill

HOSPITAL NAME

East Credit Veterinary
 Hospital

REFERRING VET

Dr. Webster

INVOICE

16371

DATE

06/05/26

PRESENTING CLINICAL SIGNS

New grade 2/6 heart murmur heard in March 2026. Strong synchronous pulses, HR 120. April 2026 Rio came in for recheck and noted a grade 1-2/6 systolic heart murmur on the L cranial ventral valve area. Rhythm normal, murmur slightly quieter than previous exam but the HR was also lower today at 110bpm. Has been on Dasuquin, Omega 3 and Advantix.

ULTRASONOGRAPHIC EXAMINATION OF THE HEART

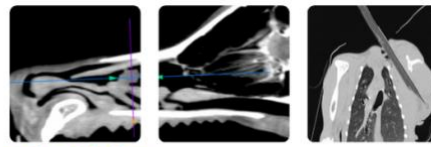
CANINE CARDIAC PARAMETERS	BW	HR BPM	LAD 4 ch Long	RAD 4 ch Long	La/Ao Heart Base	LVIDd	LVIDs
NORMAL PARAMETER		50-100			<1.6		
PATIENT	7.5	NM	2.81	2.02	1.12	2.54	1.74
CANINE CARDIAC PARAMETERS	FS	EPSS	PV V MAX (m/s)	AV V Max (m/sec)	MR Vmax	TR Vmax	RPA distensibility (normal >30%)
NORMAL PARAMETER	28-40	<0.6	0.7-1.6	0.7-1.7	4.5-5.5	< 2.7	
PATIENT	31	0.4	0.8	1.4	4.1	<2.0	NM

Cardiac Presentation

The left atrium is normal in dimension. The left ventricle is normal in dimension, with normal systolic function. The right atrium and ventricle are normal in dimension, with normal systolic function. The anterior and posterior mitral valve leaflets are thickened and redundant consistent with myxomatous changes, and there is minimal prolapse. There is no significant mitral regurgitation identified. The tricuspid valve leaflets are thickened and redundant, with trivial tricuspid regurgitation and no evidence of pulmonary hypertension. The left ventricular outflow tract demonstrated normal laminar flow and the visible aorta is unremarkable. The right ventricular outflow tract assessment revealed normal laminar flow, with appropriate main pulmonary artery diameter and right pulmonary artery distensibility. There is no pulmonic and no aortic valve insufficiency identified. There is no visible pericardial, pleural, or free peritoneal fluid documented. No evidence of hepatic venous congestion is noted. The cardiac chambers, pericardial and visible extra-cardiac regions were free of masses, spontaneous echo contrast, or thrombi.

ULTRASONOGRAPHIC FINDINGS

These findings are consistent with degenerative/myxomatous mitral valve disease with minimal to mild hemodynamic effects consistent with ACVIM Stage B1 disease. It is unlikely that any current morbidity is of cardiac origin.



PATIENT

Rio Kew

SPECIES

Canine

BREED

Korean Village Dog

SEX

Neutered Male

AGE

11 Years

WEIGHT

7.5 kg

INTERPRETED BY

Bradley Harris, DVM,
 DACVECC, DACVIM
 (cardiology)

IMAGING PERFORMED BY

Crystal Hill

HOSPITAL NAME

East Credit Veterinary
 Hospital

REFERRING VET

Dr. Webster

INVOICE

16371

DATE

06/05/26

INTERPRETATION OF THE FINDINGS & FURTHER RECOMMENDATIONS

Given these findings, no cardiac therapy is recommended. There are no cardiac contraindications to anesthesia, fluid therapy, vasopressor therapy, or corticosteroids as indicated for further assessment and treatment. If not already performed, baseline thoracic radiographs and blood pressure are recommended. A recheck echocardiogram is recommended in 6 months.

Anesthesia considerations:

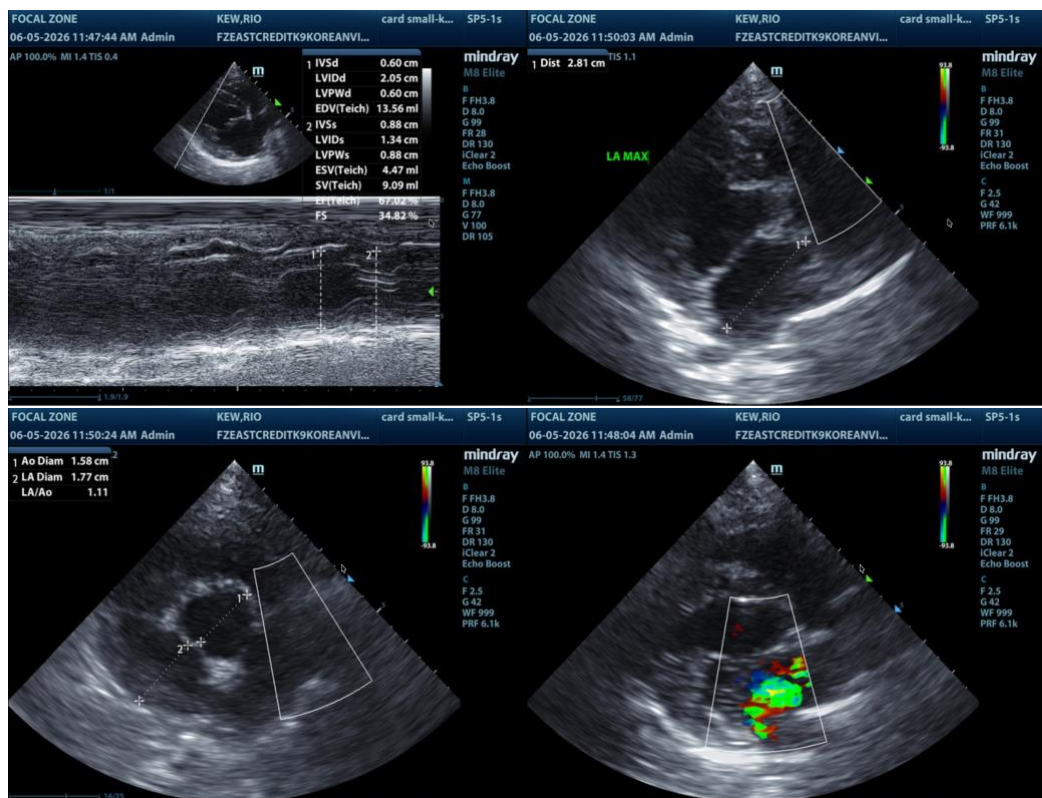
If anesthesia is necessary, alpha-2 agonists, ketamine, high dose acepromazine, and Telazol should be avoided. Fluid therapy during anesthesia should be considered at a conservative rate (e.g., 5 ml/kg/hour) if possible.

Diet:

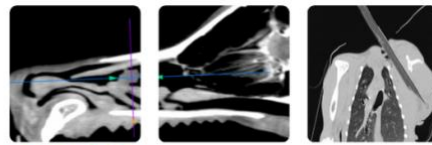
A high-quality food from Hills, Royal Canin, Science Diet, Eukanuba, Iams, or Purina that is highly palatable with adequate protein and calories for maintaining optimal body condition is reasonable.

Activity:

No special considerations are necessary.



The information and recommendations provided are based on the images presented by the referring



PATIENT

Rio Kew

SPECIES

Canine

BREED

Korean Village Dog

SEX

Neutered Male

AGE

11 Years

WEIGHT

7.5 kg

INTERPRETED BY

Bradley Harris, DVM,
DACVECC, DACVIM
(cardiology)

**IMAGING
PERFORMED BY**

Crystal Hill

HOSPITAL NAME

East Credit Veterinary
Hospital

REFERRING VET

Dr. Webster

INVOICE

16371

DATE

06/05/26

veterinarian/sonographer. No evaluation can be communicated regarding pathology that was not visible in the image/video clips provided.

Thank you for this referral. If the clinical or image interpretation does not parallel your findings or if I can be of any further assistance please contact me.

Bradley Harris, DVM, DACVECC, DACVIM (cardiology)

info@SonoPath.com