

PATIENT

Bubba Barnett

SPECIES

Canine

BREED

Yorkshire Terrier

SEX

Intact Male

AGE

7 years 8 months

WEIGHT

4.4 kg

INTERPRETED BY

Bradley Harris, DVM,
DACVECC, DACVIM
(cardiology)

IMAGING PERFORMED BY

Loetitia Saint-Jacques,
LVT

HOSPITAL NAME

Truckee Meadows
Veterinary Hospital

REFERRING VET

Dr. Rachel Kuester

INVOICE

12093

DATE

6/5/2026

PRESENTING CLINICAL SIGNS

Heart murmur (1/6) first ausculted 3/2026 and then noted again (1-2/6) 5/2026. Patient is currently asymptomatic.

MEDS-Simparica TRIO q30d.

Abnormal PE/Chem/CBC/UA Results: No recent labs. Last labs 12/2025. Adult wellness panel (Chem, CBC, Accuplex, Fecal PCR) WNL.

ULTRASONOGRAPHIC EXAMINATION OF THE HEART

CANINE CARDIAC PARAMETERS	BW	HR BPM	LAD 4 ch Long	RAD 4 ch Long	La/Ao Heart Base	LVIDd	LVIDs
NORMAL PARAMETER		50-100			<1.6		
PATIENT	4.4 kg	NM	2.01	1.46	1.17	1.63	0.50
CANINE CARDIAC PARAMETERS	FS	EPSS	PV V MAX (m/s)	AV V Max (m/sec)	MR Vmax	TR Vmax	RPA distensibility (normal >30%)
NORMAL PARAMETER	28-40	<0.6	0.7-1.6	0.7-1.7	4.5-5.5	< 2.7	
PATIENT	69	0.1	1.0	1.3	NM	NM	44

Cardiac Presentation

The left atrium is normal in dimension. The left ventricle is normal in dimension, with normal systolic function. The right atrium and ventricle are normal in dimension, with normal systolic function. The anterior and posterior mitral valve leaflets are minimally thickened with no significant prolapse. There is no significant mitral regurgitation identified. The tricuspid valve leaflets are appropriately thin with adequate apposition, intact chordae, no significant tricuspid regurgitation and no evidence of pulmonary hypertension. The left ventricular outflow tract demonstrated normal laminar flow and the visible aorta is unremarkable. The right ventricular outflow tract assessment revealed normal laminar flow, with appropriate main pulmonary artery diameter and right pulmonary artery distensibility. There is no pulmonic and no aortic valve insufficiency identified. There is no visible pericardial, pleural, or free peritoneal fluid documented. No evidence of hepatic venous congestion is noted. The cardiac chambers, pericardial and visible extra-cardiac regions were free of masses, spontaneous echo contrast, or thrombi.

ULTRASONOGRAPHIC FINDINGS

- These findings are consistent with an essentially normal echocardiogram. Any murmur will be considered functional in origin. No cardiac cause of the morbidity is identified.

INTERPRETATION OF THE FINDINGS & FURTHER RECOMMENDATIONS



PATIENT

Bubba Barnett

SPECIES

Canine

BREED

Yorkshire Terrier

SEX

Intact Male

AGE

7 years 8 months

WEIGHT

4.4 kg

INTERPRETED BY

Bradley Harris, DVM,
DACVECC, DACVIM
(cardiology)

**IMAGING
PERFORMED BY**

Loetitia Saint-Jacques,
LVT

HOSPITAL NAME

Truckee Meadows
Veterinary Hospital

REFERRING VET

Dr. Rachel Kuester

INVOICE

12093

DATE

6/5/2026

Given these findings, no cardiac therapy is recommended. There are no cardiac contraindications to fluid therapy or corticosteroid therapy, as indicated for further assessment and treatment. Given the minimally thickened mitral valve without regurgitation, a repeat echocardiogram is reasonable in 1 year.

Anesthesia considerations:

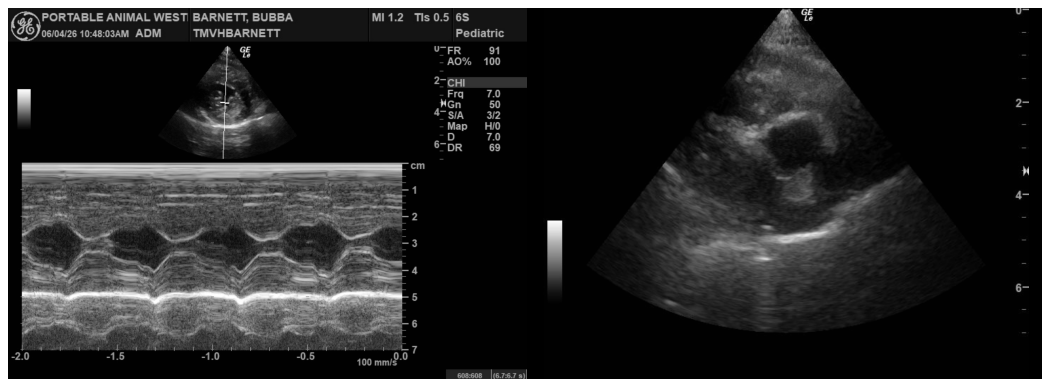
No special considerations are necessary.

Diet:

No special considerations are necessary. Any high-quality food from Hills, Royal Canin, Science Diet, Eukanuba, Iams, or Purina is reasonable.

Activity:

No special considerations are necessary.



The information and recommendations provided are based on the images presented by the referring veterinarian/sonographer. No evaluation can be communicated regarding pathology that was not visible in the image/video clips provided.

Thank you for this referral. If the clinical or image interpretation does not parallel your findings or if I can be of any further assistance please contact me.

Bradley Harris, DVM, DACVECC, DACVIM (cardiology)

info@SonoPath.com