



## PATIENT

Nicloe Dawson  
Dubaeu

## SPECIES

Canine

## BREED

OESD

## SEX

MN

## AGE

11 years

## WEIGHT

46.3 kg

## INTERPRETED BY

Bradley Harris, DVM,  
DACVECC, DACVIM  
(cardiology)

## IMAGING PERFORMED BY

Dr. Mark VanCampen

## HOSPITAL NAME

Renfrew Animal  
Hospital

## REFERRING VET

Dr. Mark VanCampen

## INVOICE

12080

## DATE

6/3/2026

## PRESENTING CLINICAL SIGNS

Re-check for monitoring stage B1. No clinical signs. Recent increase in ALP.

Abnormal PE/Chem/CBC/UA Results: ALP - 727(5-160).

## ULTRASONOGRAPHIC EXAMINATION OF THE HEART

CANINE CARDIAC PARAMETERS	BW	HR BPM	LAD 4 ch Long	RAD 4 ch Long	La/Ao Heart Base	LVIDd	LVIDs
NORMAL PARAMETER		50-100			<1.6		
PATIENT	46.3 kg	140	5.14	NM	1.01	4.9	2.7
CANINE CARDIAC PARAMETERS	FS	EPSS	PV V MAX (m/s)	AV V Max (m/sec)	MR Vmax	TR Vmax	RPA distensibility (normal >30%)
NORMAL PARAMETER	28-40	<0.6	0.7-1.6	0.7-1.7	4.5-5.5	< 2.7	
PATIENT	45	0.5	0.7	1.5	5.0	2.5	NM

## Cardiac Presentation

The left atrium is normal in dimension. The left ventricle is normal in dimension, with normal systolic function. The right atrium and ventricle are normal in dimension, with normal systolic function. The anterior and posterior mitral valve leaflets are thickened and redundant consistent with myxomatous changes, and there is no significant prolapse. There is mild mitral regurgitation identified. The tricuspid valve leaflets are minimally thickened, with trivial tricuspid regurgitation and no evidence of pulmonary hypertension. The left ventricular outflow tract demonstrated normal laminar flow and the visible aorta is unremarkable. The right ventricular outflow tract assessment revealed normal laminar flow, with appropriate main pulmonary artery diameter and right pulmonary artery distensibility. There is no pulmonic and no aortic valve insufficiency identified. There is no visible pericardial, pleural, or free peritoneal fluid documented. No evidence of hepatic venous congestion is noted. The cardiac chambers, pericardial and visible extra-cardiac regions were free of masses, spontaneous echo contrast, or thrombi.

## Cardiac

There is a single-lead ECG available for review. The underlying rhythm appears to be a normal sinus rhythm. There are intermittent ventricular premature contractions (VPCs).

## ULTRASONOGRAPHIC FINDINGS

- These findings are consistent with degenerative/myxomatous mitral valve disease with minimal to mild hemodynamic effects consistent with ACVIM Stage B1 disease. It is unlikely that any current morbidity is of cardiac origin.



## PATIENT

Nicloe Dawson  
Dubaeu

## SPECIES

Canine

## BREED

OESD

## SEX

MN

## AGE

11 years

## WEIGHT

46.3 kg

## INTERPRETED BY

Bradley Harris, DVM,  
DACVECC, DACVIM  
(cardiology)

## IMAGING PERFORMED BY

Dr. Mark VanCampen

## HOSPITAL NAME

Renfrew Animal  
Hospital

## REFERRING VET

Dr. Mark VanCampen

## INVOICE

12080

## DATE

6/3/2026

## INTERPRETATION OF THE FINDINGS & FURTHER RECOMMENDATIONS

Given these findings, no cardiac therapy is recommended. There are no cardiac contraindications to anesthesia, fluid therapy, vasopressor therapy, or corticosteroids as indicated for further assessment and treatment. If not already performed, baseline thoracic radiographs and blood pressure are recommended. A recheck echocardiogram is recommended in 6 months. While therapy is not specifically indicated based on these findings, further diagnostics might help tailor therapeutic recommendations. Consider the following:

- Abdominal ultrasound to look for abdominal causes of VPCs (e.g., splenic/adrenal changes)

- Consider 24-48 hour ambulatory ECG (Holter) monitor to assess significance of arrhythmia

### Anesthesia considerations:

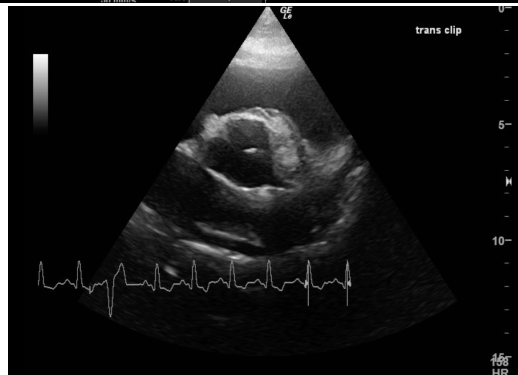
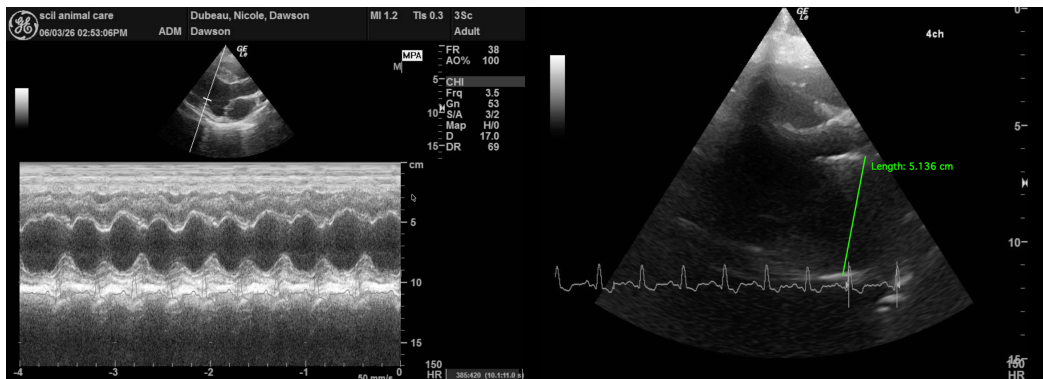
If anesthesia is necessary, alpha-2 agonists, ketamine, high dose acepromazine, and Telazol should be avoided. Fluid therapy during anesthesia should be considered at a conservative rate (e.g., 5 ml/kg/hour) if possible.

### Diet:

A high-quality food from Hills, Royal Canin, Science Diet, Eukanuba, Iams, or Purina that is highly palatable with adequate protein and calories for maintaining optimal body condition is reasonable.

### Activity:

No special considerations are necessary.



The information and recommendations provided are based on the images presented by the referring veterinarian/sonographer. No evaluation can be communicated regarding pathology that was not



## PATIENT

Nicloe Dawson  
Dubaeu

## SPECIES

Canine

## BREED

OESD

## SEX

MN

## AGE

11 years

## WEIGHT

46.3 kg

## INTERPRETED BY

Bradley Harris, DVM,  
DACVECC, DACVIM  
(cardiology)

## IMAGING PERFORMED BY

Dr. Mark VanCampen

## HOSPITAL NAME

Renfew Animal  
Hospital

## REFERRING VET

Dr. Mark VanCampen

## INVOICE

12080

## DATE

6/3/2026

visible in the image/video clips provided.

Thank you for this referral. If the clinical or image interpretation does not parallel your findings or if I can be of any further assistance please contact me.

**Bradley Harris, DVM, DACVECC, DACVIM (cardiology)**

[info@SonoPath.com](mailto:info@SonoPath.com)