



PATIENT

Loki Jones

SPECIES

Feline

BREED

DLH

SEX

Neutered Male

AGE

16 Years 2 Months

WEIGHT

8 lbs

PRESENTING CLINICAL SIGNS

*Just over a week noticed increased breathing effort. *BW is normal

ULTRASONOGRAPHIC EXAMINATION OF THE HEART

FELINE CARDIAC PARAMETERS	BODY WEIGHT (kg)	HR (BPM)	IVSd (cm)	LVIDd (cm)	LVWd (cm)	FS (%)	EF (%)
NORMAL PARAMETER	-----	150-240	0.3-0.6	1.0-2.1	0.25-0.6	35-67	80-100
PATIENT	3.64	NM	0.51	1.96	0.51	28	NM
FELINE CARDIAC PARAMETERS	LA/AO (M-mode)	LA/AO HEART BASE (Sisson)	LAD LA MAX 4 Chamber		LVOT VEL. (m/s)	RVOT VEL. (m/s)	IVRT (m/)
NORMAL PARAMETER	<1.5	1.6	0.7-1.7		<1.6	<1.3	40-60
PATIENT	NM	3.09	2.76		0.8	0.3	NM
Adapted from June Boon, Veterinary Echocardiography, 1998 Sisson D et al. JVIM 1991; 5: 232, Jacobs et al. Am J Vet Res 1985; 46:1705							

INTERPRETED BY

Bradley Harris, DVM,
DACVECC, DACVIM
(cardiology)

IMAGING PERFORMED BY

Dr. Melinda Persson

HOSPITAL NAME

At Home Veterinary

REFERRING VET

Dr. Melinda Persson

INVOICE

16271

DATE

06/03/26

Cardiac Presentation

The left atrium is severely enlarged. There are no distinct left atrial thrombi/clots or spontaneous echo contrast appreciated. The left ventricle is moderately enlarged with normal wall thickness, and no evidence of restriction. Left ventricular systolic function is reduced. The right atrium and ventricle are enlarged with reduced systolic function. The anterior and posterior mitral and tricuspid valve leaflets presented normal linear structure, extension in systole, and union in diastole with trace to mild regurgitation. There is no evidence of systolic anterior mitral motion documented. The left ventricular outflow tract demonstrated normal laminar flow and subjective structural valvular integrity. The visible aorta is unremarkable. Pulmonary outflow tract assessment revealed normal valve structure, laminar flow, and appropriate diameter and distensibility. There is no evidence of semilunar valve insufficiency or pulmonary hypertension documented. There is moderate pericardial, no overt pleural or free peritoneal fluid noted.

ULTRASONOGRAPHIC FINDINGS

These findings identify significant atrial dilation in the absence of any LV hypertrophy or outflow tract obstruction. In the absence of any iatrogenic (fluids/steroid) or intrinsic (hyperthyroidism or severe anemia) factors that could represent a volume load, the findings are consistent with the myocardial form of restrictive cardiomyopathy (RCM, previously considered UCM). The degree of atrial dilation makes CHF a likely explanation for the clinical/radiographic signs.

INTERPRETATION OF THE FINDINGS & FURTHER RECOMMENDATIONS



PATIENT

Loki Jones

SPECIES

Feline

BREED

DLH

SEX

Neutered Male

AGE

16 Years 2 Months

WEIGHT

8 lbs

INTERPRETED BY

Bradley Harris, DVM,
DACVECC, DACVIM
(cardiology)

IMAGING PERFORMED BY

Dr. Melinda Persson

HOSPITAL NAME

At Home Veterinary

REFERRING VET

Dr. Melinda Persson

INVOICE

16271

DATE

06/03/26

Treatment for CHF is recommended, to include Lasix (1-2mg/kg q24-BID), enalapril (0.5mg/kg q24, assuming normal BP and kidney function), and Vetmedin (0.25-0.35mg/kg BID). A repeat chest X-rays, chemistry, and BP is recommended prior to discharge, and again in 1-2 weeks. Additionally, Plavix/clopidogrel (1/4 of a 75 mg tablet, or 18.75 mg PO q 24 h) +/- rivaroxaban (2.5mg q24) should be initiated as an anti-thrombotic. Due to the bitter taste of this medication, it may be best to place it in an empty gelatin capsule or use products such as a Pill Pocket. Barring any setbacks or complications, a repeat echo/rads will be recommended in 3-6 months.

Anesthesia considerations:

Anesthesia should be avoided until signs of congestion have resolved. If anesthesia is necessary, then alpha-2 agonists, ketamine, high dose acepromazine, and Telazol should be avoided. If an ACE inhibitor (enalapril, benazepril) or spironolactone is being given, it should not be administered on the morning of general anesthesia. Other cardiac medications should be administered per the normal dosing schedule. Anesthetic IV fluid use should be limited to < 3 ml/kg/hr and, if IV fluid therapy is administered during the procedure, a 1 mg/kg dose of IM Lasix should be administered when the patient is awake and standing in recovery. A shorter anesthetic duration will reduce the risk of complications. Pre-oxygenation is advised. Premedication with an opioid (i.e., butorphanol, hydromorphone, oxymorphone) with or without a benzodiazepine is generally the safest protocol. An induction agent such as Propofol, alfaxalone, or diazepam/etomidate can be used to effect. Maintenance of anesthesia with isoflurane or sevoflurane is reasonable.

Diet:

A high-quality food from Hills, Royal Canin, Science Diet, Eukanuba, Iams, or Purina that is highly palatable with adequate protein and calories for maintaining optimal body condition with mild dietary sodium restriction (<100 mg/100 kcal) is recommended. Consider omega-3 fatty acid supplementation.

Activity:

Avoid strenuous activity.



PATIENT

Loki Jones

SPECIES

Feline

BREED

DLH

SEX

Neutered Male

AGE

16 Years 2 Months

WEIGHT

8 lbs

INTERPRETED BY

Bradley Harris, DVM,
DACVECC, DACVIM
(cardiology)

IMAGING PERFORMED BY

Dr. Melinda Persson

HOSPITAL NAME

At Home Veterinary

REFERRING VET

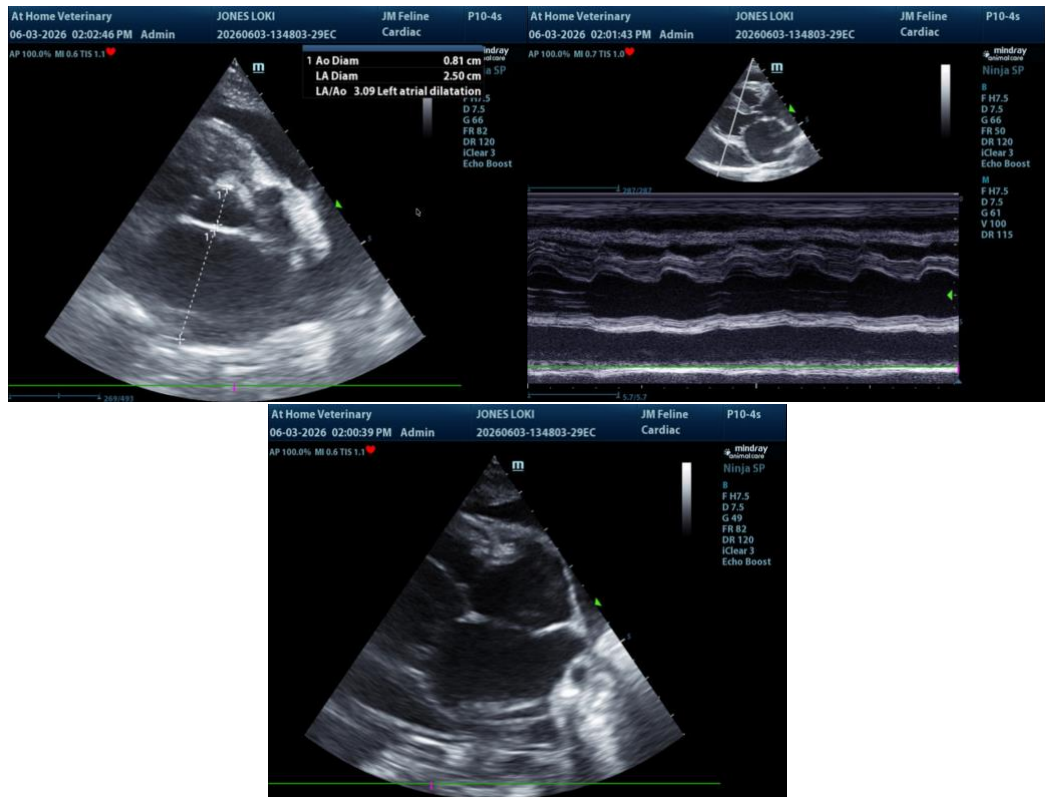
Dr. Melinda Persson

INVOICE

16271

DATE

06/03/26



The information and recommendations provided are based on the images presented by the referring veterinarian/sonographer. No evaluation can be communicated regarding pathology that was not visible in the image/video clips provided.

Thank you for this referral. If the clinical or image interpretation does not parallel your findings or if I can be of any further assistance please contact me.

Bradley Harris, DVM, DACVECC, DACVIM (cardiology)

info@SonoPath.com