

PATIENT

Lucky Baldwin

SPECIES

Feline

BREED

DLH

SEX

FS

AGE

11yr

WEIGHT

9.4lb

INTERPRETED BY

Bradley Harris, DVM,
DACVECC, DACVIM
(cardiology)

IMAGING PERFORMED BY

Sara Hansen

HOSPITAL NAME

Countryside Veterinary
Services - Canyonville

REFERRING VET

Dr Eichmann

INVOICE

24741

DATE

05/07/2026

PRESENTING CLINICAL SIGNS

Diagnosed with systolic murmur on 3/18/26 grade 2/6

Elevated pro bnp 111 on

Elevated BP but is now on Bp meds and well managed.

Current meds amlodipine 1.25 mg

ULTRASONOGRAPHIC EXAMINATION OF THE HEART

FELINE CARDIAC PARAMETERS	BODY WEIGHT	HR (BPM)	IVSd (cm)	LVIDd (cm)	LVWd (cm)	FS (%)	EF (%)
NORMAL PARAMETER	-----	150-240	0.3-0.6	1.0-2.1	0.25-0.6	35-67	80-100
PATIENT	4.27	NM	0.52	1.46	0.47	62	99
FELINE CARDIAC PARAMETERS	LA/AO M-Mode	LA/AO HEART BASE (Sisson)	LAD LA MAX 4 Chamber		LVOT VEL. (m/s)	RVOT VEL. (m/s)	IVRT (m/)
NORMAL PARAMETER	<1.5	1.6	0.7-1.7		<1.6	<1.3	40-60
PATIENT	1.15	1.32	1.65		--	1.3	NM

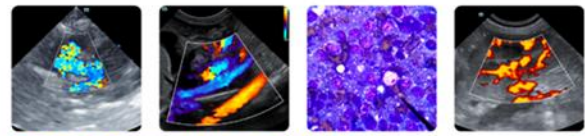
Sisson D et al. JVIM 1991; 5: 232, Jacobs et al. Am J Vet Res 1985; 46:1705

Cardiac Presentation

The left atrium is normal in dimension. There are no distinct left atrial thrombi/clots or spontaneous echo contrast appreciated. The left ventricle is normal in dimension as well as wall thickness, and no evidence of restriction. Left ventricular systolic function is normal, with adequate contractility. The right atrium and ventricle are subjectively normal in dimension and systolic function. The anterior and posterior mitral and tricuspid valve leaflets presented normal linear structure, extension in systole, and union in diastole without regurgitation. There is no evidence of systolic anterior mitral valve motion documented. The left ventricular outflow tract demonstrated normal laminar flow and subjective structural valvular integrity. The visible aorta is unremarkable. Pulmonary outflow tract assessment revealed normal valve structure, laminar flow, and appropriate diameter and distensibility. There is no evidence of pulmonary hypertension documented. There is no visible pericardial, pleural, or free peritoneal fluid noted.

ULTRASONOGRAPHIC FINDINGS

- These findings are consistent with an essentially normal echocardiogram. Any murmur auscultated will be considered functional in origin.



PATIENT

Lucky Baldwin

SPECIES

Feline

BREED

DLH

SEX

FS

AGE

11yr

WEIGHT

9.4lb

INTERPRETED BY

Bradley Harris, DVM,
 DACVECC, DACVIM
 (cardiology)

IMAGING PERFORMED BY

Sara Hansen

HOSPITAL NAME

Countryside Veterinary
 Services - Canyonville

REFERRING VET

Dr Eichmann

INVOICE

24741

DATE

05/07/2026

INTERPRETATION OF THE FINDINGS & FURTHER RECOMMENDATIONS

Given these findings, no cardiac therapy is recommended. There are no cardiac contraindications to corticosteroids or fluid therapy as indicated for further treatment. No specific recheck echocardiogram is recommended.

Anesthesia considerations:

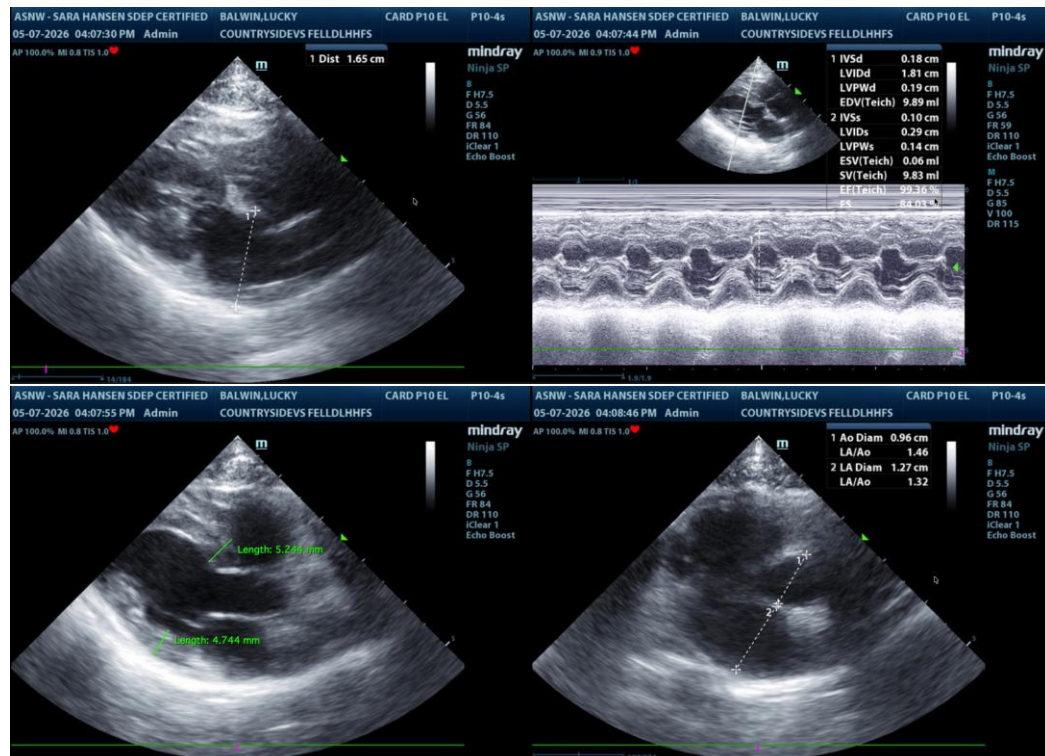
No special cardiac considerations are necessary

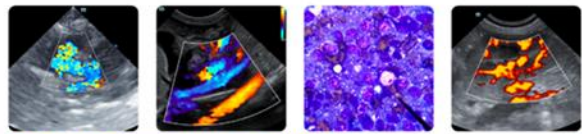
Diet:

No special considerations are necessary. Any high-quality food from Hills, Royal Canin, Science Diet, Eukanuba, Iams, or Purina is reasonable.

Activity:

No special considerations are necessary.





PATIENT

Lucky Baldwin

The information and recommendations provided are based on the images presented by the referring veterinarian/sonographer. No evaluation can be communicated regarding pathology that was not visible in the image/video clips provided.

SPECIES

Feline

Thank you for this referral. If the clinical or image interpretation does not parallel your findings or if I can be of any further assistance please contact me.

Bradley Harris, DVM, DACVECC, DACVIM (cardiology)

BREED

info@SonoPath.com

DLH

SEX

FS

AGE

11yr

WEIGHT

9.4lb

INTERPRETED BY

Bradley Harris, DVM,
DACVECC, DACVIM
(cardiology)

IMAGING PERFORMED BY

Sara Hansen

HOSPITAL NAME

Countryside Veterinary
Services - Canyonville

REFERRING VET

Dr Eichmann

INVOICE

24741

DATE

05/07/2026