

PATIENT

Bruno Backus

SPECIES

Feline

BREED

DSH

SEX

Neutered Male

AGE

7 Months

WEIGHT

7.5 lbs

INTERPRETED BY

Bradley Harris, DVM,
DACVECC, DACVIM
(Cardiology)

IMAGING PERFORMED BY

Dr. Brandon Holmes

HOSPITAL NAME

Barnes Lake Veterinary
Center

REFERRING VET

Dr. Ashleigh Fowkes

INVOICE

15899

DATE

05/07/26

PRESENTING CLINICAL SIGNS

Abnormal ECG during neuter. Specialist review: There are no pathologic arrhythmias noted on this ECG tracing. Wide QRS complexes are noted. Wide QRS complexes are consistent with, but not diagnostic for, ventricular enlargement. Right axis deviation is noted. This could represent normal patient variation or indicate myocardial disease.

Abnormal PE/Chem/CBC/UA Results: Potassium: 5.3, ALP = 93

ULTRASONOGRAPHIC EXAMINATION OF THE HEART

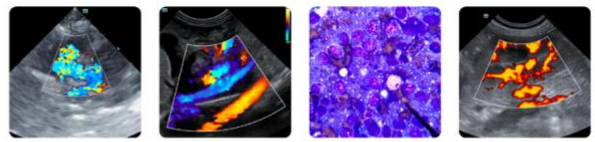
FELINE CARDIAC PARAMETERS	BODY WEIGHT (kg)	HR (BPM)	IVSd (cm)	LVIDd (cm)	LVWd (cm)	FS (%)	EF (%)
NORMAL PARAMETER	-----	150-240	0.3-0.6	1.0-2.1	0.25-0.6	35-67	80-100
PATIENT	3.41	NM	0.57	1.44	0.56	64	NM
FELINE CARDIAC PARAMETERS	LA/AO (M-mode)	LA/AO HEART BASE (Sisson)	LAD LA MAX 4 Chamber	LVOT VEL (m/s)	RVOT VEL (m/s)	IVRT (m/)	
NORMAL PARAMETER	<1.5	1.6	0.7-1.7	<1.6	<1.3	40-60	
PATIENT	NM	1.1	1.32	NM	0.8	NM	
Adapted from June Boon, Veterinary Echocardiography, 1998 Sisson D et al. JVIM 1991; 5: 232, Jacobs et al. Am J Vet Res 1985; 46:1705							

Cardiac Presentation

The left atrium is normal in dimension. There are no distinct left atrial thrombi/clots or spontaneous echo contrast appreciated. The left ventricle is normal in dimension as well as wall thickness, and no evidence of restriction. Left ventricular systolic function is normal, with adequate contractility. The right atrium and ventricle are subjectively normal in dimension and systolic function. The anterior and posterior mitral and tricuspid valve leaflets presented normal linear structure, extension in systole, and union in diastole without regurgitation. There is no evidence of systolic anterior mitral valve motion documented. The left ventricular outflow tract demonstrated normal laminar flow and subjective structural valvular integrity. The visible aorta is unremarkable. Pulmonary outflow tract assessment revealed normal valve structure, laminar flow, and appropriate diameter and distensibility. There is no evidence of pulmonary hypertension documented. There is no visible pericardial, pleural, or free peritoneal fluid noted.

ULTRASONOGRAPHIC FINDINGS

- These findings are consistent with an essentially normal echocardiogram. Any murmur auscultated will be considered functional in origin.



PATIENT

Bruno Backus

SPECIES

Feline

BREED

DSH

SEX

Neutered Male

AGE

7 Months

WEIGHT

7.5 lbs

INTERPRETED BY

Bradley Harris, DVM,
DACVECC, DACVIM
(Cardiology)

IMAGING PERFORMED BY

Dr. Brandon Holmes

HOSPITAL NAME

Barnes Lake Veterinary
Center

REFERRING VET

Dr. Ashleigh Fowkes

INVOICE

15899

DATE

05/07/26

INTERPRETATION OF THE FINDINGS & FURTHER RECOMMENDATIONS

Given these findings, no cardiac therapy is recommended. There are no cardiac contraindications to corticosteroids or fluid therapy as indicated for further treatment. No specific recheck echocardiogram is recommended.

Anesthesia considerations:

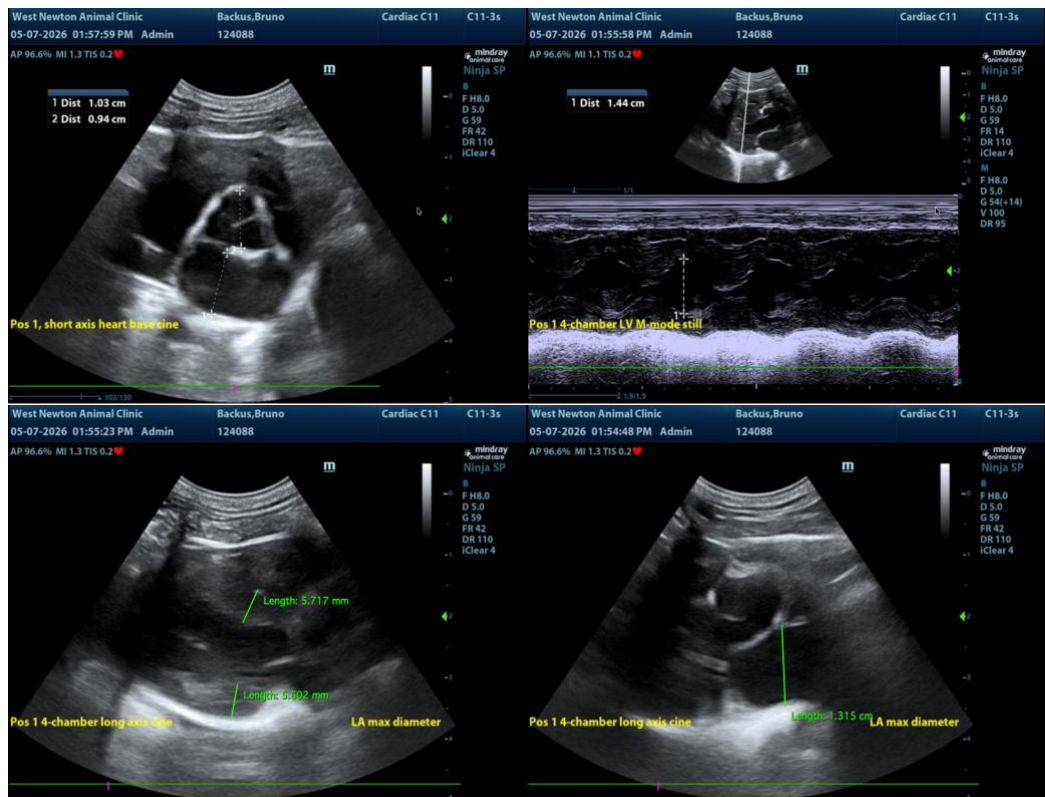
No special cardiac considerations are necessary

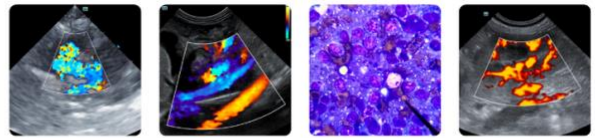
Diet:

No special considerations are necessary. Any high-quality food from Hills, Royal Canin, Science Diet, Eukanuba, Iams, or Purina is reasonable.

Activity:

No special considerations are necessary.





PATIENT

Bruno Backus

SPECIES

Feline

BREED

DSH

SEX

Neutered Male

AGE

7 Months

WEIGHT

7.5 lbs

INTERPRETED BY

Bradley Harris, DVM,
DACVECC, DACVIM
(Cardiology)

IMAGING PERFORMED BY

Dr. Brandon Holmes

HOSPITAL NAME

Barnes Lake Veterinary
Center

REFERRING VET

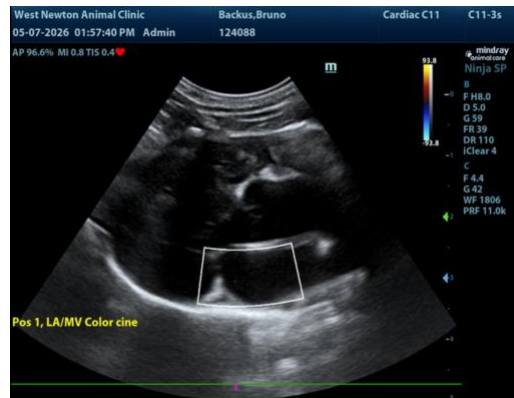
Dr. Ashleigh Fowkes

INVOICE

15899

DATE

05/07/26



The information and recommendations provided are based on the images presented by the referring veterinarian/sonographer. No evaluation can be communicated regarding pathology that was not visible in the image/video clips provided.

Thank you for this referral. If the clinical or image interpretation does not parallel your findings or if I can be of any further assistance please contact me.

Bradley Harris, DVM, DACVECC, DACVIM (Cardiology)

info@SonoPath.com