



PATIENT

Peyton Levensgood

SPECIES

Canine

BREED

Dalmatian

SEX

Neutered male

AGE

10 ½ year

WEIGHT

73.2 lbs

INTERPRETED BY

Bradley Harris, DVM,
DACVECC, DACVIM
(cardiology)

IMAGING PERFORMED BY

Amy Alvernini, VMD

HOSPITAL NAME

Gilbertsville VH

REFERRING VET

Dr. Reist

INVOICE

78098

DATE

5/29/26

PRESENTING CLINICAL SIGNS

History: Cardiomegaly on CXR 3/25 - started pimobendan 7.5mg bid. Recent increase in cough improving on doxycycline.

Abnormal PE/Chem/CBC/UA Results: Grade 4/6 L basilar systolic murmur, 3/6 R syst murmur femoral pulses strong/synch but occasional premature beats BP 150mmHg (prior to sedation) chem/cbc/T4/A4/UA - all normal 3/2025

ULTRASONOGRAPHIC EXAMINATION OF THE HEART

The left atrium is severely enlarged. The left ventricle is severely enlarged, with severely reduced systolic function. The right atrium and ventricle are normal in dimension, with normal systolic function. The anterior and posterior mitral valve leaflets are appropriately thin, but do not completely appose during systole due to the annular dilation, and there is no significant prolapse. There is mild mitral regurgitation identified. The tricuspid valve leaflets are appropriately thin with adequate apposition, intact chordae, no significant tricuspid regurgitation and no evidence of pulmonary hypertension. The left ventricular outflow tract demonstrated normal laminar flow and the visible aorta is unremarkable. The right ventricular outflow tract assessment revealed normal laminar flow, with appropriate main pulmonary artery diameter and right pulmonary artery distensibility. There is no pulmonic and moderate aortic valve insufficiency identified. There is no visible pericardial, pleural, or free peritoneal fluid documented. No evidence of hepatic venous congestion is noted. The cardiac chambers, pericardial and visible extra-cardiac regions were free of masses, spontaneous echo contrast, or thrombi.

CANINE CARDIAC PARAMETERS	Body Weight kg	HR BPM	LAD 4 ch Long	RAD 4 ch Long	La/Ao Heart Base	LVIDd	LVIDs
NORMAL PARAMETER		50-100			<1.6		
PATIENT	33.27 kg	100	6.47	3.27	1.79	6.23	4.81
CANINE CARDIAC PARAMETERS	FS	EPSS	PV V MAX (m/s)	AV V Max (m/sec)	MR Vmax	TR Vmax	RPA distensibility (normal >30%)
NORMAL PARAMETER	28-40	<0.6	0.7-1.6	0.7-1.7	4.5-5.5	< 2.7	
PATIENT	23	0.8	0.8	1.1	5.0	NM	NM

ULTRASONOGRAPHIC FINDINGS

These findings identify reduced left ventricular function in the setting of an enlarged left ventricle. Intrinsic myocardial dysfunction (ie DCM) is a concern. Other possibilities, including primary valve disease with secondary ventricular changes or myocardial depressant effects of systemic disease must also be considered. It would also be important to verify that the owners are not feeding a grain-free, exotic, or boutique diet, as a secondary nutritional cardiomyopathy must also be considered.

INTERPRETATION OF THE FINDINGS & FURTHER RECOMMENDATIONS

At this time, therapy for the myocardial dysfunction can be considered, to include Vetmedin (0.25-0.35 mg/kg BID) and enalapril (0.5 mg/kg BID, assuming normotension and lack of renal insult). If the owners



PATIENT

Peyton Levensgood

SPECIES

Canine

BREED

Dalmatian

SEX

Neutered male

AGE

10 ½ year

WEIGHT

73.2 lbs

INTERPRETED BY

Bradley Harris, DVM,
DACVECC, DACVIM
(cardiology)

IMAGING PERFORMED BY

Amy Alvernini, VMD

HOSPITAL NAME

Gilbertsville VH

REFERRING VET

Dr. Reist

INVOICE

78098

DATE

5/29/26

are feeding a grain free diet, an immediate diet change would be necessary, and the addition of taurine (50 mg/kg BID) would be appropriate. If there is any concern for metabolic/systemic disease, additional testing (complete bloodwork including T4 and resting cortisol, abdominal ultrasound) should be considered. Otherwise, thoracic radiographs, blood pressure, and chemistry panel should be performed now for a baseline, and again in 1-2 weeks. A follow-up echocardiogram, thoracic radiographs, blood pressure, and chemistry panel is recommended in 3 months to assess for either static, improved, or progressive changes. Owners should monitor resting respiratory rate at home. Values above 30 breaths/minute or an increase in respiratory rate 10% above baseline should prompt veterinary re-evaluation.

The following sources for supplemental taurine are recommended:

Mega taurine caps by Twinlab (1000mg capsule)

Taurine by Swanson Health Products (500mg capsule)

Taurine by NOW foods (500mg capsule)

Taurine 500 by GNC (500mg tablet)

Anesthesia considerations:

Anesthesia should be avoided if possible. If anesthesia is necessary, then alpha-2 agonists, ketamine, high dose acepromazine, and Telazol should be avoided. If an ACE inhibitor (enalapril, benazepril) or spironolactone is being given, it should not be administered on the morning of general anesthesia. Other cardiac medications should be administered per the normal dosing schedule. Fluid therapy during anesthesia should be considered at a reduced rate (e.g., 5 ml/kg/hour) if possible (i.e., if not hypotensive). A shorter anesthetic duration will reduce the risk of complications. Pre-oxygenation is advised. Premedication with an opioid (i.e., butorphanol, hydromorphone, oxymorphone) with or without a benzodiazepine is generally the safest protocol. An induction agent such as Propofol, alfaxalone, or diazepam/etomidate can be used to effect. Maintenance of anesthesia with isoflurane or sevoflurane is reasonable. Dobutamine (2.5-10 µg/kg/min as a CRI, starting at 2.5 µg/kg/min and increasing the dosage incrementally) may be used in lieu of fluid boluses to augment systemic blood pressure.

Diet:

A high-quality food from Hills, Royal Canin, Science Diet, Eukanuba, Iams, or Purina that is highly palatable with adequate protein and calories for maintaining optimal body condition. Consider omega-3 fatty acid supplementation. Ensure the patient is not currently receiving a boutique, exotic, or grain-free diet.

Activity:

Moderate physical activity (meandering walks, exploring the backyard, playing with toys inside, getting excited when family gets home, etc.) is encouraged, but periods of strenuous aerobic activity (jogging, strenuous outdoor ball play, prolonged play at the dog park, etc.) should be avoided, especially during periods of high heat (> 80 F) and humidity. Dogs with heart disease tend to tolerate cool and cold temperatures much better than high temperatures. Avoid sudden increases in activity (e.g. 2 block walks during the week but 2 mile walks followed by 30 minutes at the dog park on the weekends) as this may be difficult for the cardiovascular system to deal with.



PATIENT

Peyton Levensgood

SPECIES

Canine

BREED

Dalmatian

SEX

Neutered male

AGE

10 ½ year

WEIGHT

73.2 lbs

INTERPRETED BY

Bradley Harris, DVM,
DACVECC, DACVIM
(cardiology)

IMAGING PERFORMED BY

Amy Alvernini, VMD

HOSPITAL NAME

Gilbertsville VH

REFERRING VET

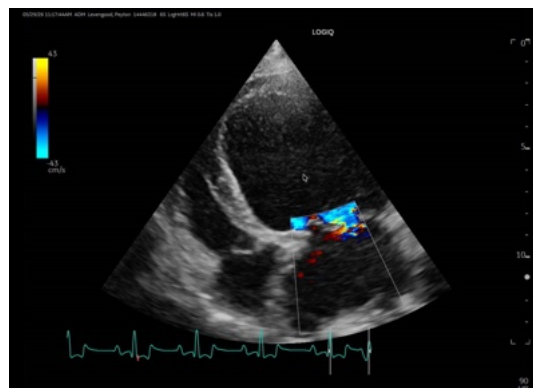
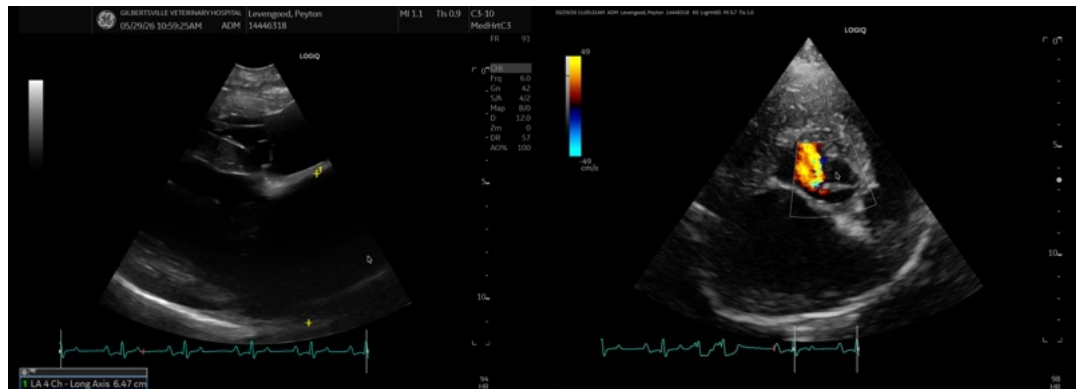
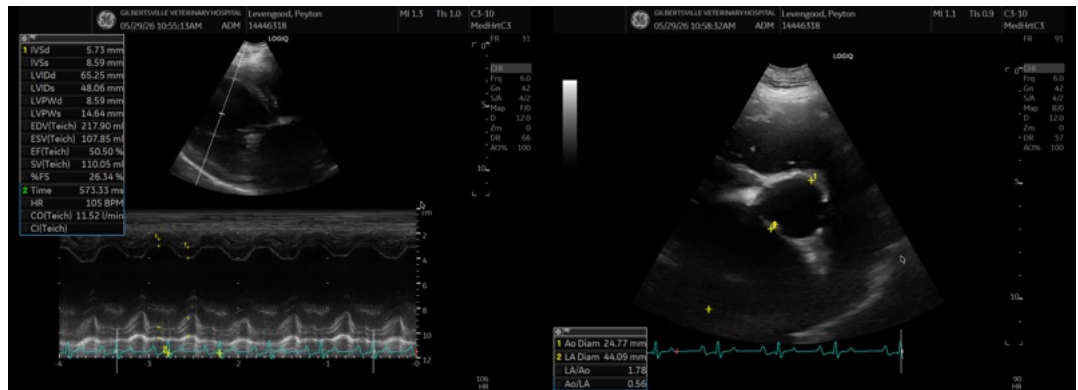
Dr. Reist

INVOICE

78098

DATE

5/29/26



The information and recommendations provided are based on the images presented by the referring veterinarian/sonographer. No evaluation can be communicated regarding pathology that was not visible in the image/video clips provided.

Thank you for this referral. If the clinical or image interpretation does not parallel your findings or if I can be of any further assistance please contact me.

Bradley Harris, DVM, DACVECC, DACVIM (cardiology)

info@SonoPath.com