



PATIENT

Doug Schuh

SPECIES

Feline

BREED

Maine Coon

SEX

Neutered male

AGE

1 years

WEIGHT

16.12 lbs

INTERPRETED BY

Bradley Harris, DVM,
DACVECC, DACVIM
(cardiology)

IMAGING PERFORMED BY

Dr. Goodman

HOSPITAL NAME

Evendale Blue Ash Pet
Hospital

REFERRING VET

Dr. DeNuzio

INVOICE

78091

DATE

5/29/26

PRESENTING CLINICAL SIGNS

History: Referral from rDVM at Kings Veterinary Hospital.
Baseline echo - no current history of heart murmur noted. Owner wanted to be proactive since he is a Maine Coon.
Received 100mg of Gabapentin the night of 5/28 and the morning of 5/29. Butorphanol 0.3mg/kg administered mid echo due to patient compliance
Blood pressure and EKG performed prior to Butorphanol being administered.
Abnormal PE/Chem/CBC/UA Results: Blood Pressure Readings - patient in right lateral with the #3 cuff on his left rear leg above the hock 1) 136/92 (117) 2) 132/86 (98) 3) 127/93 (111) EKG attached

ULTRASONOGRAPHIC EXAMINATION OF THE HEART

The left atrium is normal in dimension. There are no distinct left atrial thrombi/clots or spontaneous echo contrast appreciated. The left ventricle is normal in dimension as well as wall thickness, and no evidence of restriction. Left ventricular systolic function is normal, with adequate contractility. The right atrium and ventricle are subjectively normal in dimension and systolic function. The anterior and posterior mitral and tricuspid valve leaflets presented normal linear structure, extension in systole, and union in diastole without regurgitation. There is no evidence of systolic anterior mitral valve motion documented. The left ventricular outflow tract demonstrated normal laminar flow and subjective structural valvular integrity. The visible aorta is unremarkable. Pulmonary outflow tract assessment revealed normal valve structure, laminar flow, and appropriate diameter and distensibility. There is no evidence of pulmonary hypertension documented. There is no visible pericardial, pleural, or free peritoneal fluid noted.

FELINE CARDIAC PARAMETERS	BODY WEIGHT (kg)	HR (BPM)	IVSd (cm)	LVIDd (cm)	LVWd (cm)	FS (%)	EF (%)
NORMAL PARAMETER	-----	150-240	0.3-0.6	1.0-2.1	0.25-0.6	35-67	80-100
PATIENT	7.33	NM	0.47	1.49	0.44	77	98
FELINE CARDIAC PARAMETERS	LA/AO (M-mode)	LA/AO HEART BASE (Sisson)	LAD LA MAX 4 Chamber		LVOT VEL. (m/s)	RVOT VEL. (m/s)	IVRT (m/)
NORMAL PARAMETER	<1.5	1.6	0.7-1.7		<1.6	<1.3	40-60
PATIENT	NM	1.34	1.5		1.2	0.8	NM
Adapted from June Boon, Veterinary Echocardiography, 1998 Sisson D et al. JVIM 1991; 5: 232, Jacobs et al. Am J Vet Res 1985; 46:1705							

EKG:

A single lead rhythm strip is available for review. The underlying rhythm is sinus in origin. The R-R intervals are regular, with a uniform P-R interval that is within normal limits. There are several possible premature complexes with a wide QRS (>40ms) morphology, that may be consistent with a ventricular



PATIENT

Doug Schuh

SPECIES

Feline

BREED

Maine Coon

SEX

Neutered male

AGE

1 years

WEIGHT

16.12 lbs

INTERPRETED BY

Bradley Harris, DVM,
DACVECC, DACVIM
(cardiology)

IMAGING PERFORMED BY

Dr. Goodman

HOSPITAL NAME

Evendale Blue Ash Pet Hospital

REFERRING VET

Dr. DeNuzio

INVOICE

78091

DATE

5/29/26

origin. There are no ventricular couplets or runs of tachycardia documented. There is no evidence of atrioventricular block or atrial ectopy documented.

ULTRASONOGRAPHIC FINDINGS

These findings are consistent with an essentially normal echocardiogram. Any murmur auscultated will be considered functional in origin. A possible ventricular arrhythmia is noted. In cats, ventricular arrhythmias are usually secondary to underlying structural heart disease. Causes include cardiomyopathy (e.g., hypertrophic, restrictive, arrhythmogenic, dilated) or secondary myocardial disease (e.g., hyperthyroidism, hypertension). Rarely, ventricular arrhythmias develop secondary to extracardiac conditions (e.g., neurologic disease, metabolic disease, fever, anemia, trauma, GI disease, DIC and sepsis).

INTERPRETATION OF THE FINDINGS & FURTHER RECOMMENDATIONS

Given these findings, no cardiac therapy is recommended. A diagnostic high fidelity 6 lead ECG at paper speeds of 25 and 50mm/s is recommended to further evaluate the possible ventricular ectopy. There are no cardiac contraindications to corticosteroids or fluid therapy as indicated for further treatment. A recheck echocardiogram is recommended in 6-12 months.

Anesthesia considerations:

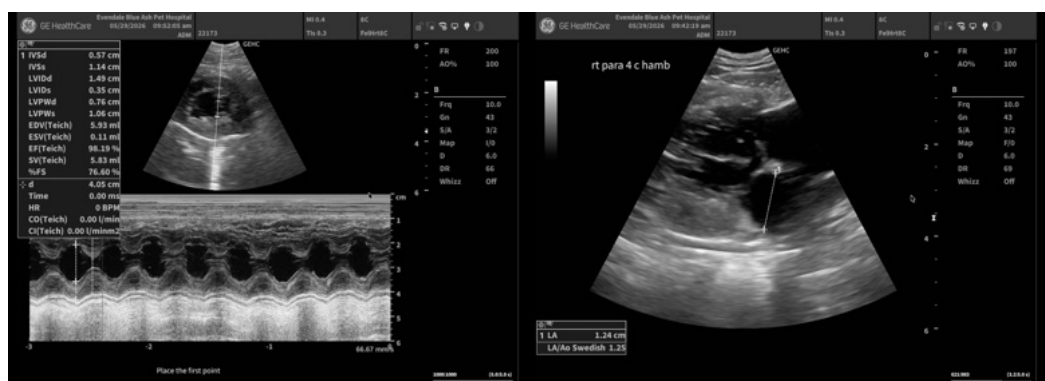
No special cardiac considerations are necessary

Diet:

No special considerations are necessary. Any high-quality food from Hills, Royal Canin, Science Diet, Eukanuba, Iams, or Purina is reasonable.

Activity:

No special considerations are necessary.





PATIENT

Doug Schuh

SPECIES

Feline

BREED

Maine Coon

SEX

Neutered male

AGE

1 years

WEIGHT

16.12 lbs

INTERPRETED BY

Bradley Harris, DVM,
DACVECC, DACVIM
(cardiology)

IMAGING PERFORMED BY

Dr. Goodman

HOSPITAL NAME

Evendale Blue Ash Pet
Hospital

REFERRING VET

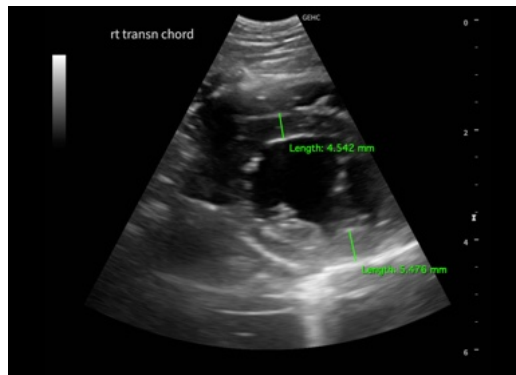
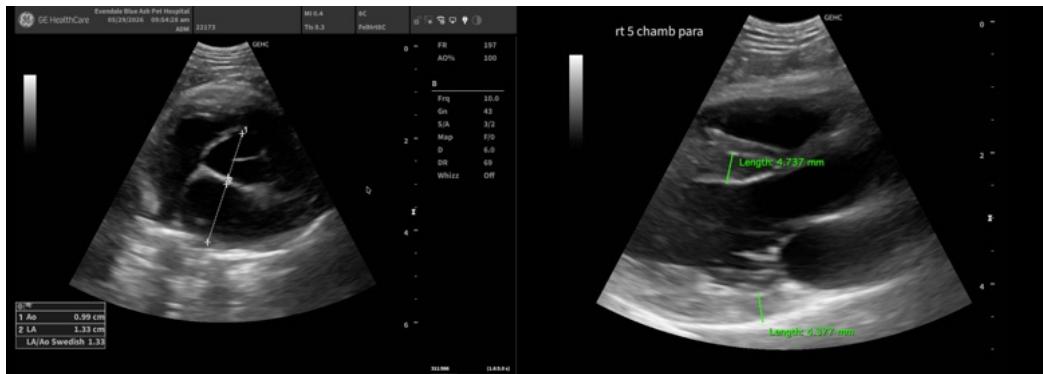
Dr. DeNuzio

INVOICE

78091

DATE

5/29/26



The information and recommendations provided are based on the images presented by the referring veterinarian/sonographer. No evaluation can be communicated regarding pathology that was not visible in the image/video clips provided.

Thank you for this referral. If the clinical or image interpretation does not parallel your findings or if I can be of any further assistance please contact me.

Bradley Harris, DVM, DACVECC, DACVIM (cardiology)

info@SonoPath.com