

PATIENT

Kika Shannon

SPECIES

Canine

BREED

Pomsky

SEX

Spayed Female

AGE

8 Years

WEIGHT

6.44 kg

INTERPRETED BY

Bradley Harris, DVM,
 DACVECC, DACVIM
 (Cardiology)

IMAGING PERFORMED BY

Crystal Hill

HOSPITAL NAME

East Credit VH

REFERRING VET

Dr. Webster

INVOICE

37265

DATE

5/28/26

PRESENTING CLINICAL SIGNS

History: Acute presentation of cough progressive over the last week. On PE noted grade 3/6 heart murmur, RR 80, HR 145. Rads showed increased opacity perihilar area and VHS 14.6. Has not been seen by a veterinarian in over 3 years and is new to us. Unsure when heart murmur developed. Increased lung sounds bilaterally and cough when exercise or excitement. Normal E/D. No meds. Abnormal PE/Chem/CBC/UA Results: Please see attached radiographs.

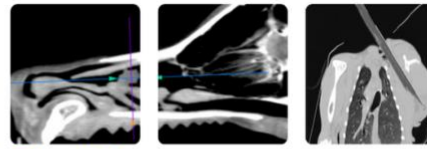
ULTRASONOGRAPHIC EXAMINATION OF THE HEART

CANINE CARDIAC PARAMETERS	BW	HR BPM	LAD 4 ch Long	RAD 4 ch Long	La/Ao Heart Base	LVIDd	LVIDs
NORMAL PARAMETER		50-100			<1.6		
PATIENT	6.44	150	3.67	1.63	2.09	4.08	2.33
CANINE CARDIAC PARAMETERS	FS	EPSS	PV V MAX (m/s)	AV V Max (m/sec)	MR Vmax	TR Vmax	RPA distensibility (normal >30%)
NORMAL PARAMETER	28-40	<0.6	0.7-1.6	0.7-1.7	4.5-5.5	< 2.7	
PATIENT	43	0.5	0.7	1.3	3.9	1.8	NM

Cardiac Presentation

The left atrium is severely enlarged. The left ventricle is severely enlarged, with marginal systolic function. The right atrium and ventricle are normal in dimension, with normal systolic function. The anterior and posterior mitral valve leaflets are thickened and redundant consistent with myxomatous changes, and there is mild prolapse. There is moderate mitral regurgitation identified. The tricuspid valve leaflets are minimally thickened, with trivial tricuspid regurgitation and no evidence of pulmonary hypertension. The left ventricular outflow tract demonstrated normal laminar flow and the visible aorta is unremarkable. The right ventricular outflow tract assessment revealed normal laminar flow, with appropriate main pulmonary artery diameter and right pulmonary artery distensibility. There is no pulmonary and no aortic valve insufficiency identified. There is no visible pericardial, pleural, or free peritoneal fluid documented. No evidence of hepatic venous congestion is noted. The cardiac chambers, pericardial and visible extra-cardiac regions were free of masses, spontaneous echo contrast, or thrombi.

ULTRASONOGRAPHIC FINDINGS



PATIENT

Kika Shannon

SPECIES

Canine

BREED

Pomsky

SEX

Spayed Female

AGE

8 Years

WEIGHT

6.44 kg

INTERPRETED BY

Bradley Harris, DVM,
 DACVECC, DACVIM
 (Cardiology)

IMAGING PERFORMED BY

Crystal Hill

HOSPITAL NAME

East Credit VH

REFERRING VET

Dr. Webster

INVOICE

37265

DATE

5/28/26

- These findings are consistent with degenerative/myxomatous mitral valve disease with moderate hemodynamic effects consistent with ACVIM Stage B2.

INTERPRETATION OF THE FINDINGS & FURTHER RECOMMENDATIONS

Recommendations/Treatment:

Given the degree of chamber dilation, cardiac therapy with enalapril (0.5 mg/kg BID assuming normotension and lack of renal insult) and Vetmedin (0.25-0.35 mg/kg BID) is recommended. While there is an increased risk of IV fluids, corticosteroids, or anesthesia, there is no overt objection, as the need likely outweighs the risks. If not already performed, baseline thoracic radiographs and blood pressure are recommended. A repeat chest X-rays, BP, and chemistry should be performed again in 1-2 weeks. A repeat echo is indicated in 6 months. Consideration could be given to mitral valve repair (open heart surgery or transcatheter edge to edge repair). Owners should monitor resting respiratory rate at home. Values above 30 breaths/minute or an increase in respiratory rate 10% above baseline should prompt veterinary re-evaluation. There is significant left atrial enlargement but no gross pulmonary pathology noted on thoracic radiographs.

Anesthesia considerations:

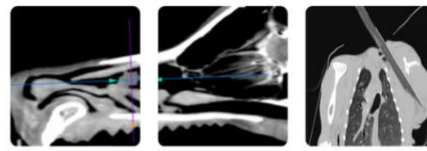
While there is no CHF present, there is likely an increased anesthetic risk which must be considered prior to any anesthetic procedure. If anesthesia is necessary, then alpha-2 agonists, ketamine, high dose acepromazine, and Telazol should be avoided. If an ACE inhibitor (enalapril, benazepril) or spironolactone is being given, it should not be administered on the morning of general anesthesia. Other cardiac medications should be administered per the normal dosing schedule. Fluid therapy during anesthesia should be considered at a reduced rate (e.g., 5 ml/kg/hour) if possible. A shorter anesthetic duration will reduce the risk of complications. Pre-oxygenation is advised. Premedication with an opioid (i.e., butorphanol, hydromorphone, oxymorphone) with or without a benzodiazepine is generally the safest protocol. An induction agent such as Propofol, alfaxalone, or diazepam/etomidate can be used to effect. Maintenance of anesthesia with isoflurane or sevoflurane is reasonable. Dobutamine (2.5-10 µg/kg/min as a CRI, starting at 2.5 µg/kg/min and increasing the dosage incrementally) may be used in lieu of fluid boluses to augment systemic blood pressure.

Diet:

A high-quality food from Hills, Royal Canin, Science Diet, Eukanuba, Iams, or Purina that is highly palatable with adequate protein and calories for maintaining an optimal body condition is recommended. Consider omega-3 fatty acid supplementation. Avoid any boutique, exotic, or grain-free diets.

Activity:

Moderate physical activity (meandering walks, exploring the backyard, playing with toys inside, getting excited when family gets home, etc.) is encouraged, but periods of strenuous aerobic activity (jogging, strenuous outdoor ball play, prolonged play at the dog park, etc.) should be avoided, especially during periods of high heat (> 80 F) and humidity. Dogs with heart disease tend to tolerate cool and cold temperatures much better than high temperatures. Avoid sudden increases in activity (e.g. 2 block walks during the week but 2 mile walks followed by 30 minutes at the dog park on the



PATIENT

weekends) as this may be difficult for the cardiovascular system to deal with.

Kika Shannon

SPECIES

Canine

BREED

Pomsky

SEX

Spayed Female

AGE

8 Years

WEIGHT

6.44 kg

INTERPRETED BY

Bradley Harris, DVM,
 DACVECC, DACVIM
 (Cardiology)

IMAGING PERFORMED BY

Crystal Hill

HOSPITAL NAME

East Credit VH

REFERRING VET

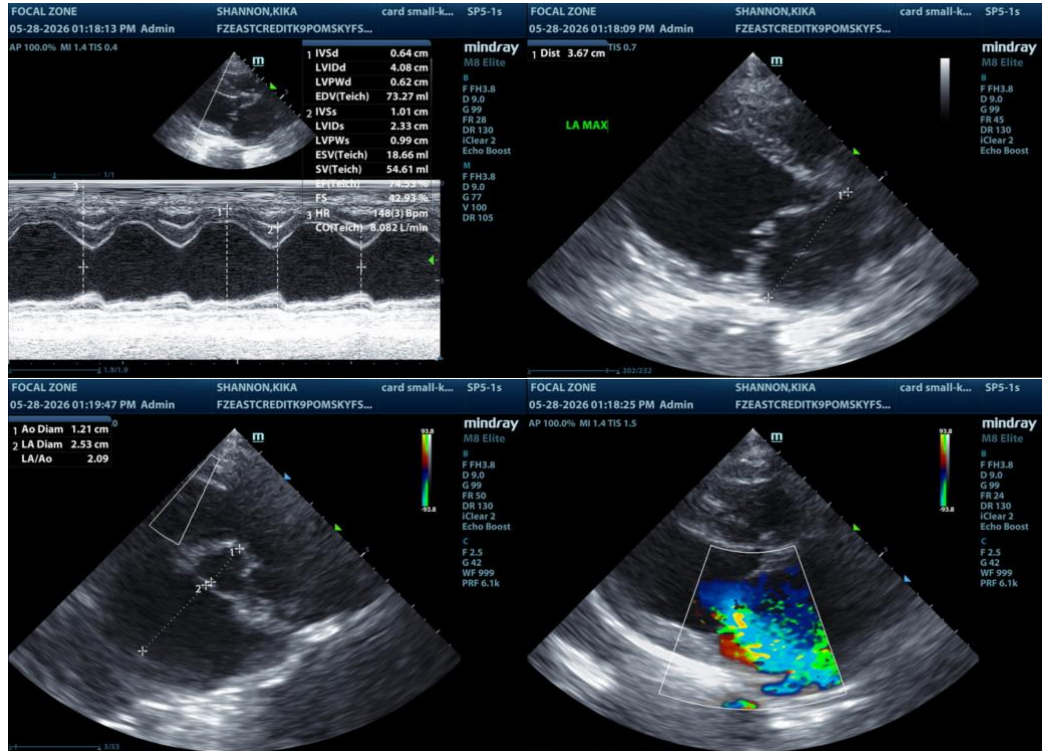
Dr. Webster

INVOICE

37265

DATE

5/28/26



The information and recommendations provided are based on the images presented by the referring veterinarian/sonographer. No evaluation can be communicated regarding pathology that was not visible in the image/video clips provided.

Thank you for this referral. If the clinical or image interpretation does not parallel your findings or if I can be of any further assistance please contact me.

Bradley Harris, DVM, DACVECC, DACVIM (cardiology)

info@SonoPath.com