

DATE PRESENTING CLINICAL SIGNS

5/28/26 CLINICAL BACKGROUND & STUDY DETAILS:

PATIENT History: Pre-surgical echo to assess GA risk. P has had murmur present since at least 2021. Stable, no CHF signs. Murmur grade: Gr 1/6 LS. Pertinent abnormal PE/Chem/CBC/UA Results: Labwork not attached.

Hope Couch

SPECIES Current medications: SUROLAN OTIC SUSPENSION 15ML BOTTLE 5/4/2026, GENONE TOPICAL SPRAY 60CC 5/4/2026, DOUXO PYO SHAMPOO 6.7OZ 5/4/2026, SIMPARICA TRIO 11.1-22LBS SINGLE DOSE 5/4/2026, FORTIFLORA CANINE BOX 2/25/2025, MOMETAMAX 15G BOTTLE 2/25/2025, CEFPODOXIME 100MG TABLET 2/25/2025

Canine

BREED

Blood Pressure: N/A.
Sedation used: Dexdomitor .004mg/kg- .07ml and .3mg/kg Torbugesic .2ml
Pertinent previous ultrasound results: No previous.

Bichon Frise

SEX

STAT: Not requested.
Imaging performed by: Stephanie Warga RDCS, RVT.

Intact Female

AGE

8/22/15

ULTRASONOGRAPHIC EXAMINATION OF THE HEART

WEIGHT

16 Pounds

INTERPRETED BY

Bradley Harris, DVM, DACVECC, DACVIM (cardiology)

HOSPITAL NAME

Everhart VH

REFERRING VET

Dr. Khan

CANINE CARDIAC PARAMETERS	BW	HR BPM	LAD 4 ch Long	RAD 4 ch Long	La/Ao Heart Base	LVIDd	LVIDs
NORMAL PARAMETER		50-100			<1.6		
PATIENT	7.27	40	2.48	2.58	1.41	2.43	1.87
CANINE CARDIAC PARAMETERS	FS	EPSS	PV V MAX (m/s)	AV V Max (m/sec)	MR Vmax	TR Vmax	RPA distensibility (normal >30%)
NORMAL PARAMETER	28-40	<0.6	0.7-1.6	0.7-1.7	4.5-5.5	< 2.7	
PATIENT	23	NM	0.9	1.3	4.6	3.1	24

Cardiac Presentation

INVOICE

37247

The left atrium is normal in dimension. The left ventricle is normal in dimension, with normal systolic function. The right atrium and ventricle are upper limits of normal to mildly enlarged, with normal systolic function. The anterior and posterior mitral valve leaflets are thickened and redundant consistent with myxomatous changes, and there is no significant prolapse. There is mild mitral regurgitation identified. The

tricuspid valve leaflets are thickened and redundant, with moderate tricuspid regurgitation and evidence of borderline pulmonary hypertension. The left ventricular outflow tract demonstrated normal laminar flow and the visible aorta is unremarkable. The right ventricular outflow tract assessment revealed normal laminar flow, with appropriate main pulmonary artery diameter and right pulmonary artery distensibility. There is no pulmonic and no aortic valve insufficiency identified. There is no visible pericardial, pleural, or free peritoneal fluid documented. No evidence of hepatic venous congestion is noted. The cardiac chambers, pericardial and visible extra-cardiac regions were free of masses, spontaneous echo contrast, or thrombi.

ULTRASONOGRAPHIC FINDINGS

- These findings identify significant pulmonary hypertension in conjunction with degenerative mitral disease. The lack of chamber enlargement is consistent with ACVIM stage B1, making the PH more likely related to primary respiratory disease or other etiology (non-type 2 PH). Pulmonary hypertension in dogs is most commonly secondary to primary respiratory disease (chronic bronchitis, pulmonary fibrosis, or other forms of pulmonary interstitial disease). Pulmonary hypertension can also develop in dogs with severe heartworm disease or secondary to pulmonary thromboembolism (PTE). Less commonly, pulmonary hypertension is identified in dogs as an idiopathic condition. Pulmonary hypertension commonly causes syncope, and a patient's signs may be attributable to this condition.

INTERPRETATION OF THE FINDINGS & FURTHER RECOMMENDATIONS

Sedation with dexdomitor precludes accurate chamber dimension and systolic function assessment/quantification. Interpretation is made based on the current study, but this may not reflect the natural status of the patient

Recommendations/Treatment:

Given the mild right sided cardiac enlargement, cardiac therapy is reasonable at this time. Treatment for the PH/presumed respiratory disease is also warranted, as clinical signs are present. Therapy should include Vetmedin (0.25-0.35 mg/kg BID), sildenafil (2 mg/kg BID), and enalapril (0.5 mg/kg BID assuming normotension and lack of renal insult). Baseline thoracic radiographs, blood pressure and chemistry panel should be performed now, and again in 1-2 weeks. A repeat echocardiogram, thoracic radiographs, blood pressure, and chemistry panel is indicated in another 3-6 months, or sooner if progression is suspected, clinical signs develop/worsen, or additional cardiac therapy is being contemplated.

Anesthesia considerations:

While there is no CHF present, there is likely an increased anesthetic risk which must be considered prior to any anesthetic procedure. If anesthesia is necessary, then alpha-2 agonists, ketamine, high dose acepromazine, and Telazol should be avoided. If an ACE inhibitor (enalapril, benazepril) or spironolactone is being given, it should not be administered on the morning of general anesthesia. Other cardiac medications should be administered per the normal dosing schedule. Fluid therapy during anesthesia should be considered at a reduced rate (e.g., 5 ml/kg/hour) if possible. A shorter anesthetic duration will reduce the risk of complications. Pre-oxygenation is advised. Premedication with an opioid (i.e., butorphanol, hydromorphone, oxymorphone) with or without a benzodiazepine is generally the safest

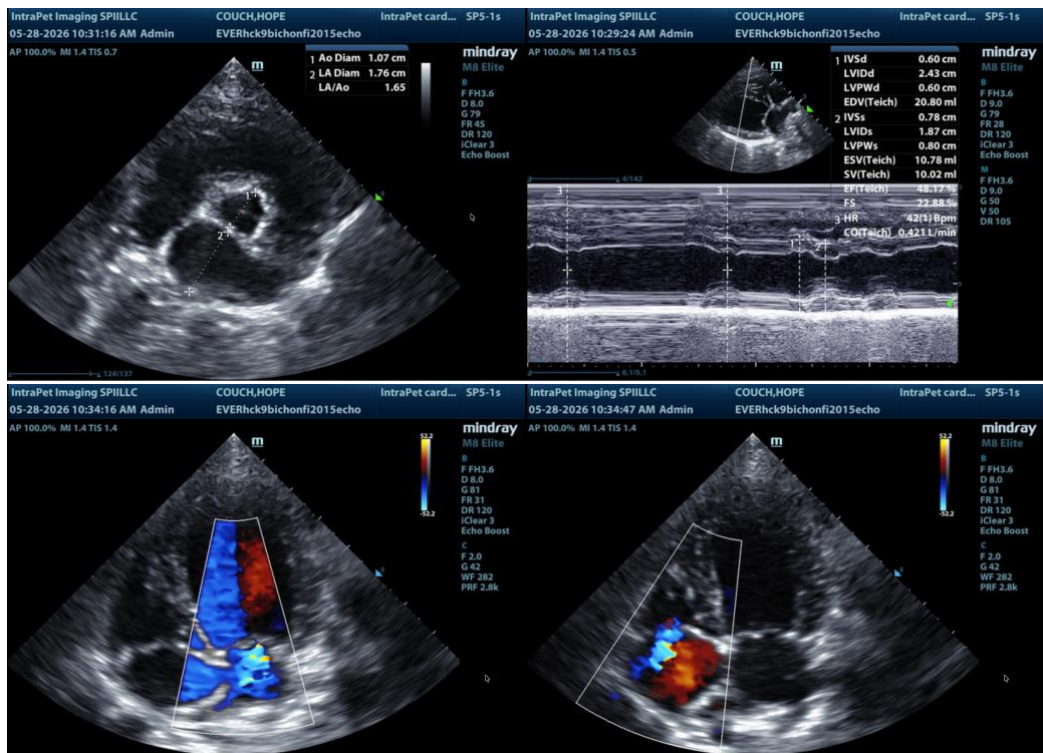
protocol. An induction agent such as Propofol, alfaxalone, or diazepam/etomidate can be used to effect. Maintenance of anesthesia with isoflurane or sevoflurane is reasonable.

Diet:

A high-quality food from Hills, Royal Canin, Science Diet, Eukanuba, Iams, or Purina that is highly palatable with adequate protein and calories for maintaining optimal body condition with mild dietary sodium restriction (<100 mg/100 kcal) is recommended. Consider omega-3 fatty acid supplementation. Ensure the patient is not currently receiving a boutique, exotic, or grain-free diet.

Activity:

Moderate physical activity (meandering walks, exploring the backyard, playing with toys inside, getting excited when family gets home, etc.) is encouraged, but periods of strenuous aerobic activity (jogging, strenuous outdoor ball play, prolonged play at the dog park, etc.) should be avoided, especially during periods of high heat (> 80 F) and humidity. Dogs with heart disease tend to tolerate cool and cold temperatures much better than high temperatures. Avoid sudden increases in activity (e.g. 2 block walks during the week but 2 mile walks followed by 30 minutes at the dog park on the weekends) as this may be difficult for the cardiovascular system to deal with.



The information and recommendations provided are based on the images presented by the referring veterinarian/sonographer. No evaluation can be communicated regarding pathology that was not visible in

the image/video clips provided.

Thank you for this referral. If the clinical or image interpretation does not parallel your findings or if I can be of any further assistance please contact me.

Bradley Harris, DVM, DACVECC, DACVIM (cardiology)

info@SonoPath.com