

**PATIENT**

Annie Marshall

**SPECIES**

Canine

**BREED**

Yorkie

**SEX**

Spayed Female

**AGE**

13 Years

**WEIGHT**

3 kg

**INTERPRETED BY**

Bradley Harris, DVM,  
 DACVECC, DACVIM  
 (cardiology)

**IMAGING PERFORMED BY**

Kelly Reschny

**HOSPITAL NAME**

Watzin VC

**REFERRING VET**

Dr. Beacock

**INVOICE**

37242

**DATE**

5/28/26

**PRESENTING CLINICAL SIGNS**

History: The Patient's heart is normal. The heart sounds are clear with no murmurs or arrhythmia heard. The pulses are normal. BUT, HEART IS FAST AND SHE IS ON GRAIN FREE FOOD

Current Medications: 50 mg metronidazole SID x 5 days & Fortiflora SA SID

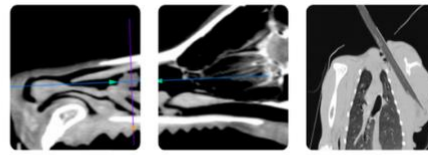
**ULTRASONOGRAPHIC EXAMINATION OF THE HEART**

CANINE CARDIAC PARAMETERS	BW	HR BPM	LAD 4 ch Long	RAD 4 ch Long	La/Ao Heart Base	LVIDd	LVIDs
<b>NORMAL PARAMETER</b>		50-100			<1.6		
<b>PATIENT</b>	3.0	240	2.0	NM	1.13	1.68	0.83
CANINE CARDIAC PARAMETERS	FS	EPSS	PV V MAX (m/s)	AV V Max (m/sec)	MR Vmax	TR Vmax	RPA distensibility (normal >30%)
<b>NORMAL PARAMETER</b>	28-40	<0.6	0.7-1.6	0.7-1.7	4.5-5.5	< 2.7	
<b>PATIENT</b>	51	0.2	1.3	1.0	NM	NM	NM

**Cardiac Presentation**

The left atrium is normal in dimension. The left ventricle is normal in dimension, with normal systolic function. The right atrium and ventricle are normal in dimension, with normal systolic function. The anterior and posterior mitral valve leaflets are appropriately thin with adequate apposition, intact chordae, and there is no significant prolapse. There is no significant mitral regurgitation identified. The tricuspid valve leaflets are appropriately thin with adequate apposition, intact chordae, with mild tricuspid regurgitation and no evidence of pulmonary hypertension. The left ventricular outflow tract demonstrated normal laminar flow and the visible aorta is unremarkable. The right ventricular outflow tract assessment revealed normal laminar flow, with appropriate main pulmonary artery diameter and right pulmonary artery distensibility. There is no pulmonic and no aortic valve insufficiency identified. There is no visible pericardial, pleural, or free peritoneal fluid documented. No evidence of hepatic venous congestion is noted. The cardiac chambers, pericardial and visible extra-cardiac regions were free of masses, spontaneous echo contrast, or thrombi.

**ULTRASONOGRAPHIC FINDINGS**



**PATIENT**

Annie Marshall

**SPECIES**

Canine

**BREED**

Yorkie

**SEX**

Spayed Female

**AGE**

13 Years

**WEIGHT**

3 kg

**INTERPRETED BY**

Bradley Harris, DVM,  
 DACVECC, DACVIM  
 (cardiology)

**IMAGING PERFORMED BY**

Kelly Reschny

**HOSPITAL NAME**

Watzin VC

**REFERRING VET**

Dr. Beacock

**INVOICE**

37242

**DATE**

5/28/26

- These findings are consistent with an essentially normal echocardiogram. Any murmur will be considered functional in origin. No cardiac cause of the morbidity is identified. The tachycardia may be secondary to dehydration/hypovolemia, pain, stress/anxiety, among other causes.

**INTERPRETATION OF THE FINDINGS & FURTHER RECOMMENDATIONS**

Recommendations:

Given these findings, no cardiac therapy is recommended. There are no cardiac contraindications to fluid therapy or corticosteroid therapy, as indicated for further assessment and treatment. Consider a high fidelity 6 lead diagnostic ECG at both 25 and 50mm/s paper speeds. No specific cardiac recheck is recommended unless a murmur or clinical signs of heart disease develop.

Anesthesia considerations:

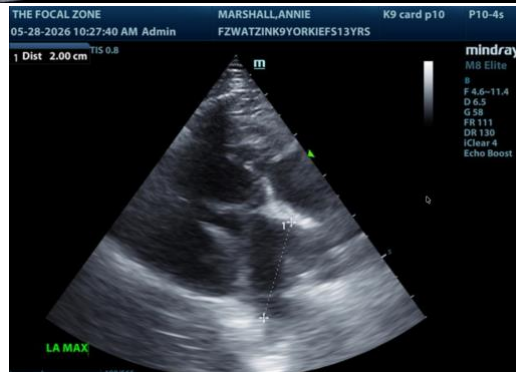
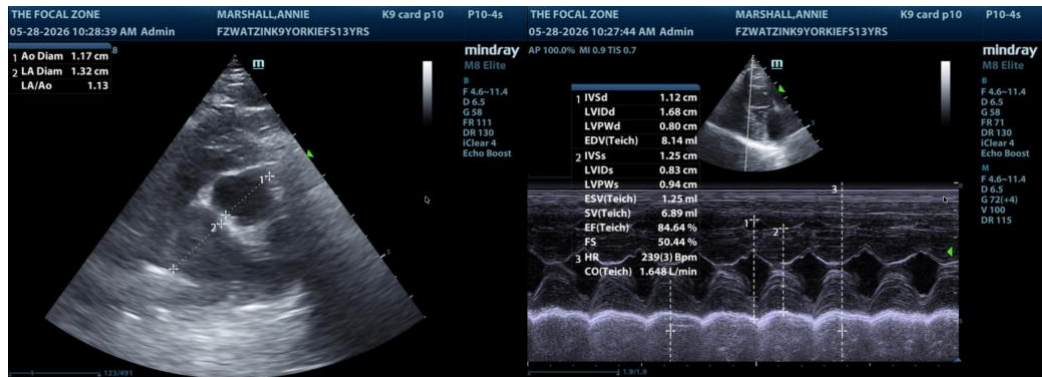
No special considerations are necessary.

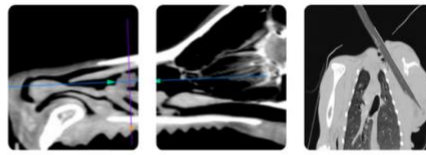
Diet:

No special considerations are necessary. Any high-quality food from Hills, Royal Canin, Science Diet, Eukanuba, Iams, or Purina is reasonable.

Activity:

No special considerations are necessary.





**PATIENT**

Annie Marshall

**SPECIES**

Canine

**BREED**

Yorkie

**SEX**

Spayed Female

**AGE**

13 Years

**WEIGHT**

3 kg

**INTERPRETED BY**

Bradley Harris, DVM,  
DACVECC, DACVIM  
(cardiology)

**IMAGING  
PERFORMED BY**

Kelly Reschny

**HOSPITAL NAME**

Watzin VC

**REFERRING VET**

Dr. Beacock

**INVOICE**

37242

**DATE**

5/28/26

The information and recommendations provided are based on the images presented by the referring veterinarian/sonographer. No evaluation can be communicated regarding pathology that was not visible in the image/video clips provided.

Thank you for this referral. If the clinical or image interpretation does not parallel your findings or if I can be of any further assistance please contact me.

**Bradley Harris, DVM, DACVECC, DACVIM (cardiology)**

[info@SonoPath.com](mailto:info@SonoPath.com)