



PATIENT

Zoey Remy

SPECIES

Canine

BREED

Chihuahua Mix

SEX

Spayed female

AGE

9 years

WEIGHT

11.8 lbs

INTERPRETED BY

Bradley Harris, DVM,
DACVECC, DACVIM
(cardiology)

IMAGING PERFORMED BY

Dr. Wasserman

HOSPITAL NAME

Insight Highlands AH

REFERRING VET

Dr. Wasserman

INVOICE

77921

DATE

5/21/26

PRESENTING CLINICAL SIGNS

History: Zoey has had a previously documented heart murmur of lower grade severity for several years. Over the past month, Zoey developed a persistent cough and has also had intermittent episodes of vomiting. Thoracic radiographs and a focused echocardiographic assessment were performed 5/23 by the referring veterinarian due to concern for progression of cardiac disease and possible congestive heart failure. Patient weighs 11.8 lb (5.35 kg). Pimobendan therapy was initiated yesterday at 2 mg PO in the morning and 1 mg PO in the evening (approximately 0.37 mg/kg PO qAM and 0.19 mg/kg PO qPM; total daily dose approximately 0.56 mg/kg/day), along with low-dose furosemide at 3.125 mg PO q12h (approximately 0.58 mg/kg PO q12h). According to the client, the cough resolved overnight following initiation of therapy and was absent today. CBC, chemistry panel, and electrolytes were submitted to an external reference laboratory and were pending at the time of examination. Thoracic radiographs are attached for supplemental CHF review. Sedated with butorphanol 0.2mg/kg IV once prior to sonogram.

Abnormal PE/Chem/CBC/UA Results: Physical examination yesterday (5/23) identified a grade 5/6 left-sided systolic heart murmur. Pulmonary auscultation revealed increased bronchointerstitial lung sounds diffusely throughout all lung fields. Doppler blood pressure obtained prior to sedation averaged approximately 120 mmHg systolic. Urine specific gravity measured 1.034. Thoracic radiographs demonstrated generalized cardiomegaly with a VHS of 12.5 and VLAS of 3.03. Brief echocardiographic assessment identified left atrial enlargement with an estimated LA:Ao ratio of approximately 1.4.

ULTRASONOGRAPHIC EXAMINATION OF THE HEART

The left atrium is normal in dimension. The left ventricle is normal in dimension, with normal systolic function. The right atrium and ventricle are normal in dimension, with normal systolic function. The anterior and posterior mitral valve leaflets are thickened and redundant consistent with myxomatous changes, and there is moderate prolapse. There is moderate mitral regurgitation identified. The tricuspid valve leaflets are minimally thickened, with trivial tricuspid regurgitation and no evidence of pulmonary hypertension. The left ventricular outflow tract demonstrated normal laminar flow and the visible aorta is unremarkable. The right ventricular outflow tract assessment revealed normal laminar flow, with appropriate main pulmonary artery diameter and right pulmonary artery distensibility. There is no pulmonic and no aortic valve insufficiency identified. There is no visible pericardial, pleural, or free peritoneal fluid documented. No evidence of hepatic venous congestion is noted. The cardiac chambers, pericardial and visible extra-cardiac regions were free of masses, spontaneous echo contrast, or thrombi. There is mild venous congestion, but no gross pulmonary pathology is identified on thoracic radiographs.

CANINE CARDIAC PARAMETERS	Body Weight kg	HR BPM	LAD 4 ch Long	RAD 4 ch Long	La/Ao Heart Base	LVIDd	LVIDs
NORMAL PARAMETER		50-100			<1.6		
PATIENT	5.36 kg	120	3.35	1.41	1.78	2.69	1.08
CANINE CARDIAC PARAMETERS	FS	EPSS	PV V MAX (m/s)	AV V Max (m/sec)	MR Vmax	TR Vmax	RPA distensibility (normal >30%)
NORMAL PARAMETER	28-40	<0.6	0.7-1.6	0.7-1.7	4.5-5.5	< 2.7	
PATIENT	60	0.1	0.9	1.1	NM	NM	NM



PATIENT

Zoey Remy

SPECIES

Canine

BREED

Chihuahua Mix

SEX

Spayed female

AGE

9 years

WEIGHT

11.8 lbs

INTERPRETED BY

Bradley Harris, DVM,
DACVECC, DACVIM
(cardiology)

IMAGING PERFORMED BY

Dr. Wasserman

HOSPITAL NAME

Insight Highlands AH

REFERRING VET

Dr. Wasserman

INVOICE

77921

DATE

5/21/26

ULTRASONOGRAPHIC FINDINGS

These findings are consistent with degenerative mitral valve disease with significant hemodynamic effects. Given the degree of chamber enlargement, recent thoracic radiographs, and response to therapy, congestive heart failure is a likely explanation for the clinical/radiographic signs, consistent with ACVIM Stage C.

INTERPRETATION OF THE FINDINGS & FURTHER RECOMMENDATIONS

Therapy for CHF is recommended, with Lasix (2mg/kg BID), enalapril (0.5mg/kg BID assuming normotension and lack of renal insult), and Vetmedin (.25-.35mg/kg BID). A repeat chest X-rays, BP, and chemistry should be performed now for a baseline, and again in 1-2 weeks. A repeat echo is indicated in 3 months. Owners should monitor resting respiratory rate at home. Values above 30 breaths/minute or an increase in respiratory rate 10% above baseline should prompt veterinary re-evaluation.

Anesthesia considerations:

Anesthesia should be avoided until manifestations of congestive heart failure (edema/effusion/respiratory distress) have resolved. Following that time, if anesthesia is necessary, then alpha-2 agonists, ketamine, high dose acepromazine, and Telazol should be avoided. If an ACE inhibitor (enalapril, benazepril) or spironolactone is being given, it should not be administered on the morning of general anesthesia. Other cardiac medications should be administered per the normal dosing schedule. Anesthetic IV fluid use should be limited to < 3 ml/kg/hr and, if IV fluid therapy is administered during the procedure, a 1 mg/kg dose of IM Lasix should be administered when the patient is awake and standing in recovery. A shorter anesthetic duration will reduce the risk of complications. Pre-oxygenation is advised. Premedication with an opioid (i.e., butorphanol, hydromorphone, oxymorphone) with or without a benzodiazepine is generally the safest protocol. An induction agent such as Propofol, alfaxalone, or diazepam/etomidate can be used to effect. Maintenance of anesthesia with isoflurane or sevoflurane is reasonable. Dobutamine (2.5-10 µg/kg/min as a CRI, starting at 2.5 µg/kg/min and increasing the dosage incrementally) may be used in lieu of fluid boluses to augment systemic blood pressure.

Diet:

A high-quality food from Hills, Royal Canin, Science Diet, Eukanuba, Iams, or Purina that is highly palatable with adequate protein and calories for maintaining optimal body condition with mild dietary sodium restriction (< 100 mg/100 kcal) is recommended. Consider omega-3 fatty acid supplementation. Avoid any boutique, exotic, or grain-free diets.

Activity:

Moderate physical activity (meandering walks, exploring the backyard, playing with toys inside, getting excited when family gets home, etc.) is encouraged, but periods of strenuous aerobic activity (jogging, strenuous outdoor ball play, prolonged play at the dog park, etc.) should be avoided, especially during periods of high heat (> 80 F) and humidity. Dogs with heart disease tend to tolerate cool and cold temperatures much better than high temperatures. Avoid sudden increases in activity (e.g. 2 block walks during the week but 2 mile walks followed by 30 minutes at the dog park on the weekends) as this may be difficult for the cardiovascular system to deal with.



PATIENT

Zoey Remy

SPECIES

Canine

BREED

Chihuahua Mix

SEX

Spayed female

AGE

9 years

WEIGHT

11.8 lbs

INTERPRETED BY

Bradley Harris, DVM,
DACVECC, DACVIM
(cardiology)

IMAGING PERFORMED BY

Dr. Wasserman

HOSPITAL NAME

Insight Highlands AH

REFERRING VET

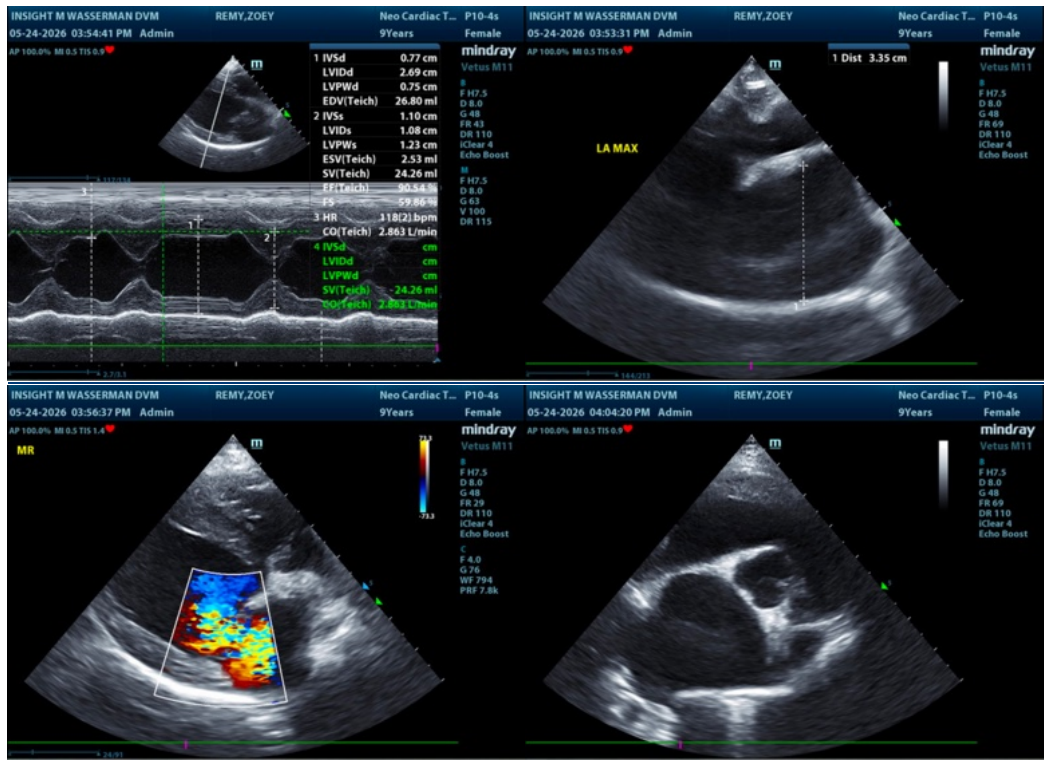
Dr. Wasserman

INVOICE

77921

DATE

5/21/26



The information and recommendations provided are based on the images presented by the referring veterinarian/sonographer. No evaluation can be communicated regarding pathology that was not visible in the image/video clips provided.

Thank you for this referral. If the clinical or image interpretation does not parallel your findings or if I can be of any further assistance please contact me.

Bradley Harris, DVM, DACVECC, DACVIM (cardiology)

info@SonoPath.com