

PATIENT PRESENTING CLINICAL SIGNS

Reign Roth New Grade 1-2 murmur found on routine exam in Feb 2026. Recheck May 2026 - Grade 3 systolic murmur PMI Left apex. Owner worried as noticing labored breathing after running, no coughing. Current Medications: Preventative (simparica trio) Cytopoint as needed

SPECIES

Canine Primary Question to Be Answered in This Exam What is causing the murmur? Prognosis? If needed a plan for treatment/monitoring

BREED

Doodle

SEX

Neutered Male

AGE

6 Years

WEIGHT

29.8 kg

INTERPRETED BY

Bradley Harris, DVM, DACVECC, DACVIM (cardiology)

ULTRASONOGRAPHIC EXAMINATION OF THE HEART

CANINE CARDIAC PARAMETERS	BW	HR BPM	LAD 4 ch Long	RAD 4 ch Long	La/Ao Heart Base	LVIDd	LVIDs
NORMAL PARAMETER		50-100			<1.6		
PATIENT	29.8	NM	4.29	2.65	1.15	4.16	3.13
CANINE CARDIAC PARAMETERS	FS	EPSS	PV V MAX (m/s)	AV V Max (m/sec)	MR Vmax	TR Vmax	RPA distensibility (normal >30%)
NORMAL PARAMETER	28-40	<0.6	0.7-1.6	0.7-1.7	4.5-5.5	< 2.7	
PATIENT	25	0.2	1.0	1.5	5.5	2.0	NM

IMAGING PERFORMED BY

Amanda Stewart

HOSPITAL NAME

New Hamburg Veterinary Clinic

REFERRING VET

Dr. Schroeder

INVOICE

16440

DATE

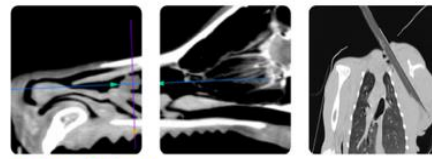
05/22/26

Cardiac Presentation

The left atrium is normal in dimension. The left ventricle is normal in dimension, with normal systolic function. The right atrium and ventricle are normal in dimension, with normal systolic function. The anterior and posterior mitral valve leaflets are thickened and redundant consistent with myxomatous changes, and there is minimal prolapse. There is mild mitral regurgitation identified. The tricuspid valve leaflets are minimally thickened, with trivial tricuspid regurgitation and no evidence of pulmonary hypertension. The left ventricular outflow tract demonstrated normal laminar flow and the visible aorta is unremarkable. The right ventricular outflow tract assessment revealed normal laminar flow, with appropriate main pulmonary artery diameter and right pulmonary artery distensibility. There is no pulmonic and no aortic valve insufficiency identified. There is no visible pericardial, pleural, or free peritoneal fluid documented. No evidence of hepatic venous congestion is noted. The cardiac chambers, pericardial and visible extra-cardiac regions were free of masses, spontaneous echo contrast, or thrombi.

ULTRASONOGRAPHIC FINDINGS

- These findings are consistent with degenerative/myxomatous mitral valve disease with minimal to mild hemodynamic effects consistent with ACVIM Stage B1 disease. It is unlikely that any current morbidity is of cardiac origin.



PATIENT

Reign Roth

SPECIES

Canine

BREED

Doodle

SEX

Neutered Male

AGE

6 Years

WEIGHT

29.8 kg

INTERPRETED BY

Bradley Harris, DVM,
 DACVECC, DACVIM
 (cardiology)

IMAGING PERFORMED BY

Amanda Stewart

HOSPITAL NAME

New Hamburg
 Veterinary Clinic

REFERRING VET

Dr. Schroeder

INVOICE

16440

DATE

05/22/26

INTERPRETATION OF THE FINDINGS & FURTHER RECOMMENDATIONS

Given these findings, no cardiac therapy is recommended. There are no cardiac contraindications to anesthesia, fluid therapy, vasopressor therapy, or corticosteroids as indicated for further assessment and treatment. If not already performed, baseline thoracic radiographs and blood pressure are recommended. A recheck echocardiogram is recommended in 6 months.

Anesthesia considerations:

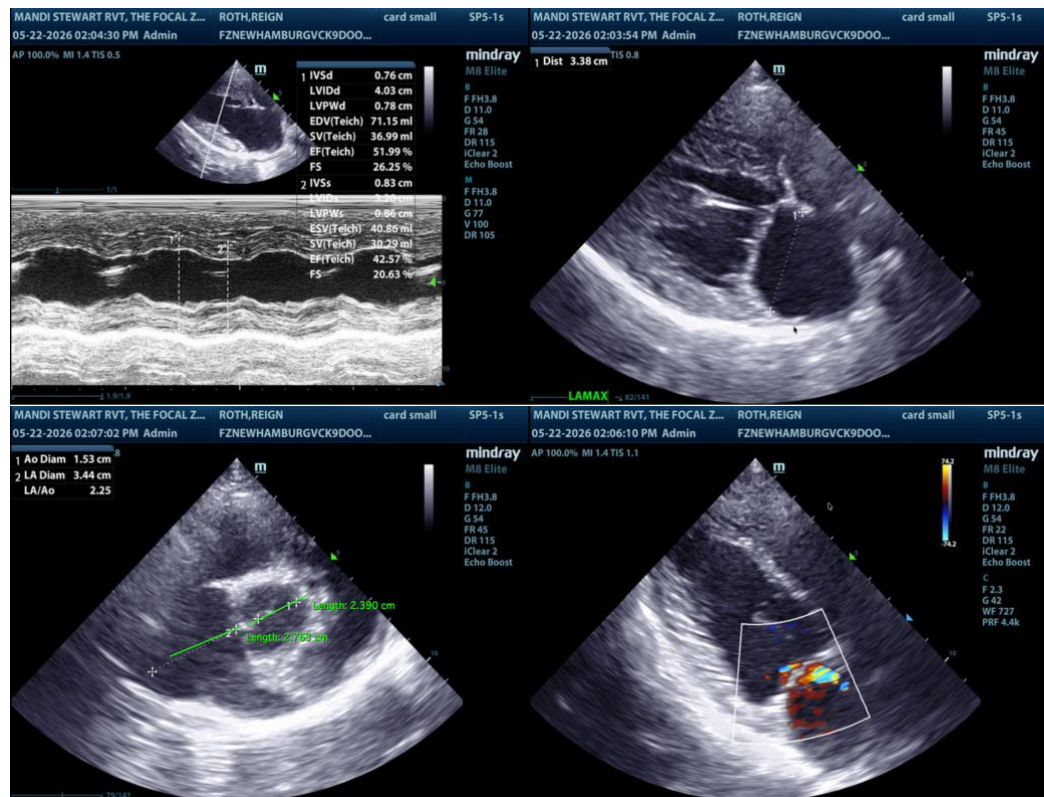
If anesthesia is necessary, alpha-2 agonists, ketamine, high dose acepromazine, and Telazol should be avoided. Fluid therapy during anesthesia should be considered at a conservative rate (e.g., 5 ml/kg/hour) if possible.

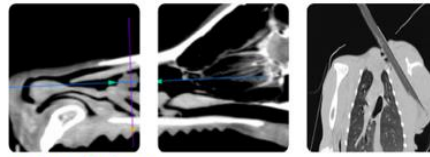
Diet:

A high-quality food from Hills, Royal Canin, Science Diet, Eukanuba, Iams, or Purina that is highly palatable with adequate protein and calories for maintaining optimal body condition is reasonable.

Activity:

No special considerations are necessary.





PATIENT

Reign Roth

The information and recommendations provided are based on the images presented by the referring veterinarian/sonographer. No evaluation can be communicated regarding pathology that was not visible in the image/video clips provided.

SPECIES

Canine

Thank you for this referral. If the clinical or image interpretation does not parallel your findings or if I can be of any further assistance please contact me.

Bradley Harris, DVM, DACVECC, DACVIM (cardiology)

BREED

Doodle

info@SonoPath.com

SEX

Neutered Male

AGE

6 Years

WEIGHT

29.8 kg

INTERPRETED BY

Bradley Harris, DVM,
DACVECC, DACVIM
(cardiology)

IMAGING PERFORMED BY

Amanda Stewart

HOSPITAL NAME

New Hamburg
Veterinary Clinic

REFERRING VET

Dr. Schroeder

INVOICE

16440

DATE

05/22/26