

**PATIENT**

Addie Honeychurch

**SPECIES**

Feline

**BREED**

Domestic Shorthair

**SEX**

Spayed female

**AGE**

12 years

**WEIGHT**

6.26 lbs

**INTERPRETED BY**

Bradley Harris, DVM,  
DACVECC, DACVIM  
(cardiology)

**IMAGING PERFORMED BY**

Loetitia Saint-Jacques,  
LVT

**HOSPITAL NAME**

Sierra Pet Clinic

**REFERRING VET**

Dr. Sperka

**INVOICE**

77920

**DATE**

3/19/26

**PRESENTING CLINICAL SIGNS**

History: Gabapentin/butorphanol- cat squirmy and moving during scan-

Presenting Complaint: Possible seizure

History: Two nights ago, pet had another "episode" that last about one minute. Her back legs seize up and she can't walk.

During these episodes, O reports she is still alert/with-it. O feels like it's intense pain in her HL as she gets very upset when

they happen, resulting in her being drained/panting afterwards. She's been more lethargic. Appetite is ok. History of

hyperthyroidism (hasn't received medication from Wedgewood yet to start it) and elevated liver enzymes for at least the past year.

O reports she still jumps up/down on things but is maybe more reluctant.

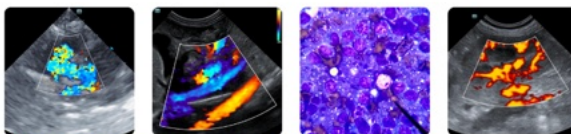
Appetite: Normal

Current Medications: Nothing at this time

**ULTRASONOGRAPHIC EXAMINATION OF THE HEART**

The left atrium is moderately enlarged. There are no distinct left atrial thrombi/clots or spontaneous echo contrast appreciated. The left ventricle is normal in dimension with normal wall thickness, and no evidence of restriction. Left ventricular systolic function is adequate. The right atrium and ventricle are mildly dilated with marginal systolic function. The anterior and posterior mitral and tricuspid valve leaflets presented normal linear structure, extension in systole, and union in diastole without regurgitation. There is no evidence of systolic anterior mitral motion documented. The left ventricular outflow tract demonstrated normal laminar flow and subjective structural valvular integrity. The visible aorta is unremarkable. Pulmonary outflow tract assessment revealed normal valve structure, laminar flow, and appropriate diameter and distensibility. There is no evidence of semilunar valve insufficiency or pulmonary hypertension documented. There is scant pericardial, no pleural, and mild free peritoneal fluid noted.

FELINE CARDIAC PARAMETERS	BODY WEIGHT (kg)	HR (BPM)	IVSd (cm)	LVIDd (cm)	LVWd (cm)	FS (%)	EF (%)
NORMAL PARAMETER	-----	150-240	0.3-0.6	1.0-2.1	0.25-0.6	35-67	80-100
PATIENT	6.26 kg	NM	0.51	1.56	0.48	47	82
FELINE CARDIAC PARAMETERS	LA/AO (M-mode)	LA/AO HEART BASE (Sisson)	LAD LA MAX 4 Chamber	LVOT VEL. (m/s)	RVOT VEL. (m/s)	IVRT (m/)	
NORMAL PARAMETER	<1.5	1.6	0.7-1.7	<1.6	<1.3	40-60	
PATIENT	NM	2.16	1.96	1.4	1.2	NM	
Adapted from June Boon, Veterinary Echocardiography, 1998 Sisson D et al. JVIM 1991; 5: 232, Jacobs et al. Am J Vet Res 1985; 46:1705							

**PATIENT**

Addie Honeychurch

**SPECIES**

Feline

**BREED**

Domestic Shorthair

**SEX**

Spayed female

**AGE**

12 years

**WEIGHT**

6.26 lbs

**INTERPRETED BY**Bradley Harris, DVM,  
DACVECC, DACVIM  
(cardiology)**IMAGING  
PERFORMED BY**Loetitia Saint-Jacques,  
LVT**HOSPITAL NAME**

Sierra Pet Clinic

**REFERRING VET**

Dr. Sperka

**INVOICE**

77920

**DATE**

3/19/26

**ULTRASONOGRAPHIC FINDINGS**

These findings identify significant atrial dilation in the absence of any LV hypertrophy or outflow tract obstruction. In the absence of any iatrogenic (fluids/steroid) or intrinsic (hyperthyroidism or severe anemia) factors that could represent a volume load, the findings are consistent with the myocardial form of restrictive cardiomyopathy (RCM, previously considered UCM). The degree of atrial dilation makes CHF a likely explanation for the clinical/radiographic signs.

**INTERPRETATION OF THE FINDINGS & FURTHER RECOMMENDATIONS**

Treatment for CHF is recommended, to include Lasix (1-2mg/kg q24-BID), enalapril (0.5mg/kg q24, assuming normal BP and kidney function), and Vetmedin (0.25-0.35mg/kg BID). A repeat chest X-rays, chemistry, and BP are recommended prior to discharge, and again in 1-2 weeks. Additionally, Plavix/clopidogrel (1/4 of a 75 mg tablet, or 18.75 mg PO q 24 h) +/- rivaroxaban (2.5mg q24) should be initiated as an anti-thrombotic. Due to the bitter taste of this medication, it may be best to place it in an empty gelatin capsule or use products such as a Pill Pocket. Barring any setbacks or complications, a repeat echo/rads will be recommended in 3-6 months.

Anesthesia considerations:

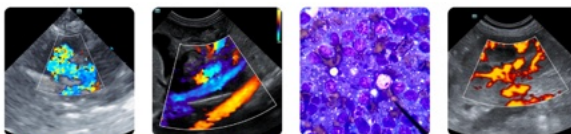
Anesthesia should be avoided until signs of congestion have resolved. If anesthesia is necessary, then alpha-2 agonists, ketamine, high dose acepromazine, and Telazol should be avoided. If an ACE inhibitor (enalapril, benazepril) or spironolactone is being given, it should not be administered on the morning of general anesthesia. Other cardiac medications should be administered per the normal dosing schedule. Anesthetic IV fluid use should be limited to < 3 ml/kg/hr and, if IV fluid therapy is administered during the procedure, a 1 mg/kg dose of IM Lasix should be administered when the patient is awake and standing in recovery. A shorter anesthetic duration will reduce the risk of complications. Pre-oxygenation is advised. Premedication with an opioid (i.e., butorphanol, hydromorphone, oxymorphone) with or without a benzodiazepine is generally the safest protocol. An induction agent such as Propofol, alfaxalone, or diazepam/etomidate can be used to effect. Maintenance of anesthesia with isoflurane or sevoflurane is reasonable.

Diet:

A high-quality food from Hills, Royal Canin, Science Diet, Eukanuba, Iams, or Purina that is highly palatable with adequate protein and calories for maintaining optimal body condition with mild dietary sodium restriction (< 100 mg/100 kcal) is recommended. Consider omega-3 fatty acid supplementation.

Activity:

Avoid strenuous activity.



**PATIENT**

Addie Honeychurch

**SPECIES**

Feline

**BREED**

Domestic Shorthair

**SEX**

Spayed female

**AGE**

12 years

**WEIGHT**

6.26 lbs

**INTERPRETED BY**

Bradley Harris, DVM,  
DACVECC, DACVIM  
(cardiology)

**IMAGING PERFORMED BY**

Loetitia Saint-Jacques,  
LVT

**HOSPITAL NAME**

Sierra Pet Clinic

**REFERRING VET**

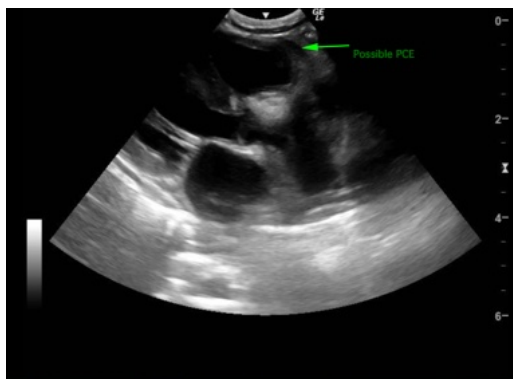
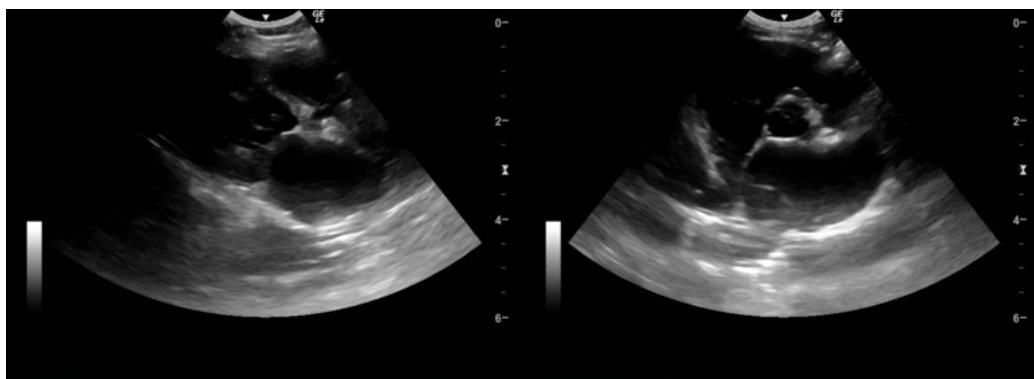
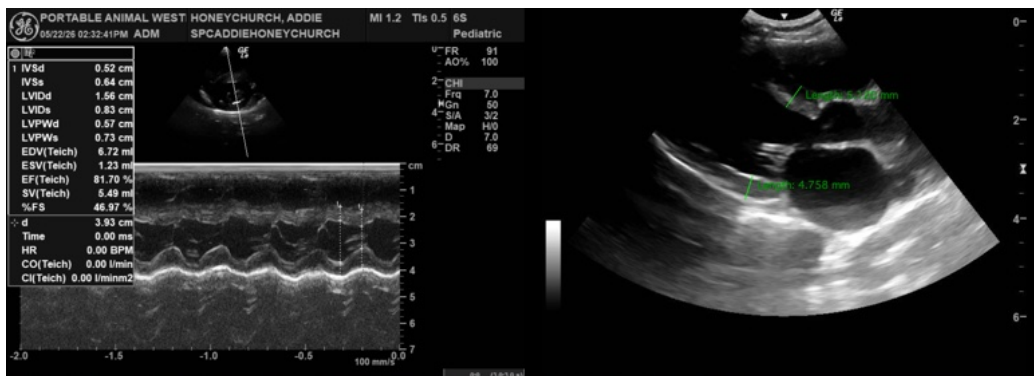
Dr. Sperka

**INVOICE**

77920

**DATE**

3/19/26



The information and recommendations provided are based on the images presented by the referring veterinarian/sonographer. No evaluation can be communicated regarding pathology that was not visible in the image/video clips provided.

Thank you for this referral. If the clinical or image interpretation does not parallel your findings or if I can be of any further assistance please contact me.

Bradley Harris, DVM, DACVECC, DACVIM (cardiology)

[info@SonoPath.com](mailto:info@SonoPath.com)