



PATIENT

Mojo Varrato

SPECIES

Canine

BREED

Shih Tzu Mix

SEX

Neutered male

AGE

11 years

WEIGHT

15 lbs

INTERPRETED BY

Bradley Harris, DVM,
DACVECC, DACVIM
(cardiology)

IMAGING PERFORMED BY

Julia Bakker, DVM

HOSPITAL NAME

Orange Blossom
Veterinary Imaging

REFERRING VET

Dr. Groves

PRESENTING CLINICAL SIGNS

History: Patient had an echocardiogram performed 5-6-26 and diagnosed with MVD stage B1. On 5/15 patient presented after a seizure type episode after which he had been having increased respiratory effort and heavily panting ever since. He also coughs up to 5 episodes a day but this hasn't changed in severity or frequency since his prior echo.
5/15 radiographs suspicious of CHF - moderate generalized cardiomegaly; mild to moderate generalized pulmonary interstitial pattern; moderates peri hilar interstitial pattern present
Patient was started on lasix and a recheck echo was scheduled.
Clinically pet is feeling better on lasix and has stopped historic cough.
Radiographs from 5/15 and from day of echo with improved symptoms both attached for comparison

ULTRASONOGRAPHIC EXAMINATION OF THE HEART

The left atrium is normal in dimension. The left ventricle is normal in dimension, with normal systolic function. The right atrium and ventricle are normal in dimension, with normal systolic function. The anterior and posterior mitral valve leaflets are thickened and redundant consistent with myxomatous changes, and there is moderate prolapse. There is moderate mitral regurgitation identified. The tricuspid valve leaflets are minimally thickened, with mild tricuspid regurgitation and no evidence of pulmonary hypertension. The left ventricular outflow tract demonstrated normal laminar flow and the visible aorta is unremarkable. The right ventricular outflow tract assessment revealed normal laminar flow, with appropriate main pulmonary artery diameter and right pulmonary artery distensibility. There is no pulmonic and no aortic valve insufficiency identified. There is no visible pericardial, pleural, or free peritoneal fluid documented. No evidence of hepatic venous congestion is noted. The cardiac chambers, pericardial and visible extra-cardiac regions were free of masses, spontaneous echo contrast, or thrombi.

CANINE CARDIAC PARAMETERS	Body Weight kg	HR BPM	LAD 4 ch Long	RAD 4 ch Long	La/Ao Heart Base	LVIDd	LVIDs
NORMAL PARAMETER		50-100			<1.6		
PATIENT	6.82 kg	NM	2.85	2.15	1.28	2.47	0.93
CANINE CARDIAC PARAMETERS	FS	EPSS	PV V MAX (m/s)	AV V Max (m/sec)	MR Vmax	TR Vmax	RPA distensibility (normal >30%)
NORMAL PARAMETER	28-40	<0.6	0.7-1.6	0.7-1.7	4.5-5.5	< 2.7	
PATIENT	62	0.1	0.6	1.1	5.4	NM	NM

INVOICE

77834

DATE

5/20/26

ULTRASONOGRAPHIC FINDINGS

These findings are consistent with degenerative/myxomatous mitral valve disease with minimal to mild hemodynamic effects consistent with ACVIM Stage B1 disease. It is unlikely that any current morbidity is of cardiac origin.



PATIENT

Mojo Varrato

SPECIES

Canine

BREED

Shih Tzu Mix

SEX

Neutered male

AGE

11 years

WEIGHT

15 lbs

INTERPRETED BY

Bradley Harris, DVM,
DACVECC, DACVIM
(cardiology)

IMAGING PERFORMED BY

Julia Bakker, DVM

HOSPITAL NAME

Orange Blossom
Veterinary Imaging

REFERRING VET

Dr. Groves

INVOICE

77834

DATE

5/20/26

INTERPRETATION OF THE FINDINGS & FURTHER RECOMMENDATIONS

Given these findings, no cardiac therapy is recommended. There are no cardiac contraindications to anesthesia, fluid therapy, vasopressor therapy, or corticosteroids as indicated for further assessment and treatment. If not already performed, baseline thoracic radiographs and blood pressure are recommended. A recheck echocardiogram is recommended in 6 months.

Anesthesia considerations:

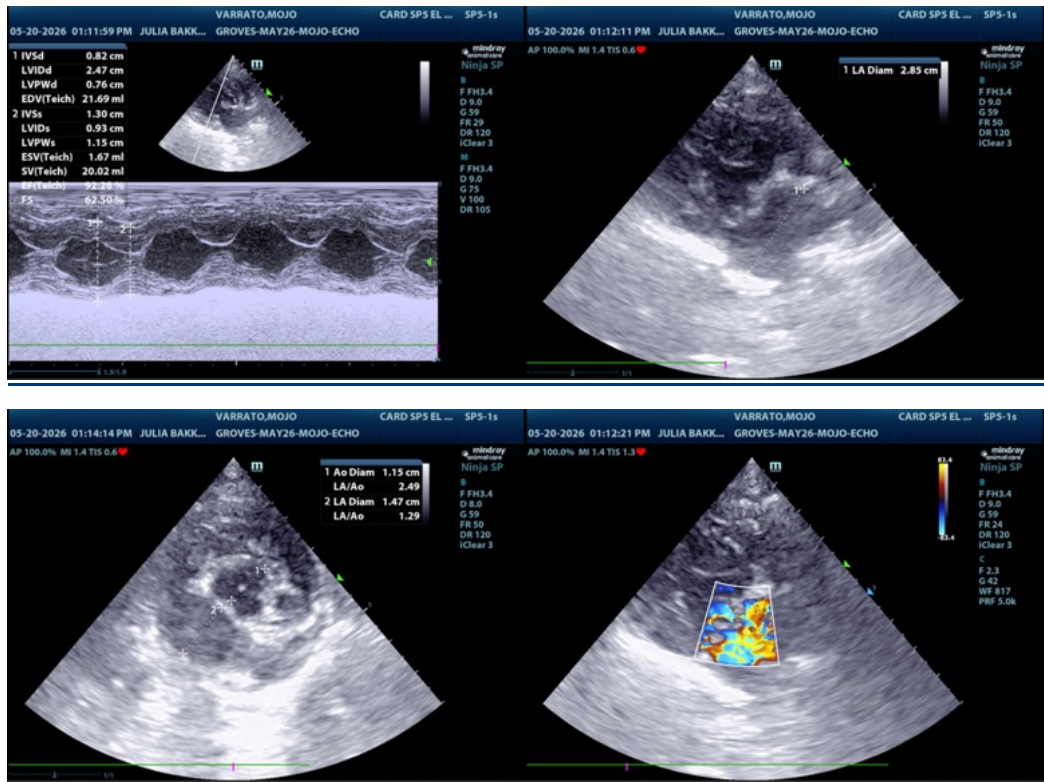
If anesthesia is necessary, alpha-2 agonists, ketamine, high dose acepromazine, and Telazol should be avoided. Fluid therapy during anesthesia should be considered at a conservative rate (e.g., 5 ml/kg/hour) if possible.

Diet:

A high-quality food from Hills, Royal Canin, Science Diet, Eukanuba, Iams, or Purina that is highly palatable with adequate protein and calories for maintaining optimal body condition is reasonable.

Activity:

No special considerations are necessary.



The information and recommendations provided are based on the images presented by the referring veterinarian/sonographer. No evaluation can be communicated regarding pathology that was not visible in the image/video clips provided.

Thank you for this referral. If the clinical or image interpretation does not parallel your findings or if I can be of any further assistance please contact me.



PATIENT

Bradley Harris, DVM, DACVECC, DACVIM (cardiology)

Mojo Varrato

info@SonoPath.com

SPECIES

Canine

BREED

Shih Tzu Mix

SEX

Neutered male

AGE

11 years

WEIGHT

15 lbs

INTERPRETED BY

Bradley Harris, DVM,
DACVECC, DACVIM
(cardiology)

IMAGING PERFORMED BY

Julia Bakker, DVM

HOSPITAL NAME

Orange Blossom
Veterinary Imaging

REFERRING VET

Dr. Groves

INVOICE

77834

DATE

5/20/26