



PATIENT

Sophie McLaughlin

SPECIES

Canine

BREED

French Bulldog

SEX

FS

AGE

9 years 2 months

WEIGHT

11.4 kgs

PRESENTING CLINICAL SIGNS

Syncope Episodes. Mild Heart Enlargements on Chest Rads. Sedated with Gabapentin/Torb.

ULTRASONOGRAPHIC EXAMINATION OF THE HEART

CANINE CARDIAC PARAMETERS	BW	HR BPM	LAD 4 ch Long	RAD 4 ch Long	La/Ao Heart Base	LVIDd	LVIDs
NORMAL PARAMETER		50-100			<1.6		
PATIENT	11.4 kgs	130	3.26	NM	NM	2.61	1.81
CANINE CARDIAC PARAMETERS	FS	EPSS	PV V MAX (m/s)	AV V Max (m/sec)	MR Vmax	TR Vmax	RPA distensibility (normal >30%)
NORMAL PARAMETER	28-40	<0.6	0.7-1.6	0.7-1.7	4.5-5.5	< 2.7	
PATIENT	31	0.2	1.0	NM	NM	3.0	NM

INTERPRETED BY

Bradley Harris, DVM,
DACVECC, DACVIM
(cardiology)

IMAGING PERFORMED BY

Vincent Ravancho,
CVT

HOSPITAL NAME

Bond Vet Mondclair

REFERRING VET

Dr. Sposato

INVOICE

11976

DATE

5/20/2026

Cardiac Presentation

The left atrium is normal in dimension. The left ventricle is normal in dimension, with normal systolic function. The right atrium and ventricle are normal in dimension, with normal systolic function. The anterior and posterior mitral valve leaflets are appropriately thin with adequate apposition, intact chordae, and there is no significant prolapse. There is no overt mitral regurgitation identified. The tricuspid valve leaflets are appropriately thin with adequate apposition, intact chordae, with mild to moderate tricuspid regurgitation and evidence of borderline pulmonary hypertension. The left ventricular outflow tract demonstrated normal laminar flow, and the visible aorta is unremarkable. The right ventricular outflow tract assessment revealed normal laminar flow, with a dilated main pulmonary artery diameter. There is mild pulmonic and no aortic valve insufficiency identified. There is no visible pericardial, pleural, or free peritoneal fluid documented. No evidence of hepatic venous congestion is noted. There is a large heart-based mass noted in the peri-aortic region that is inhibiting adequate evaluation of the left atrium.

ULTRASONOGRAPHIC FINDINGS

- These findings identify a sizable heart base tumor seen, which most likely represents a chemodectoma. In many cases, a chemodectoma is clinically silent, and any respiratory signs are more likely related to primary airway disease associated with the breed. However, in some cases they can grow large enough that they result in pulmonary artery compression and increased right sided pressures. While not documented, this cannot be excluded based on this study.

INTERPRETATION OF THE FINDINGS & FURTHER RECOMMENDATIONS

At this time there is no absolute indication for cardiac therapy. In addition, there is no definitive treatment for a chemodectoma, as these masses are generally not resectable. There may be



PATIENT

Sophie McLaughlin

chemotherapeutic or radiation options available, but serial monitoring of the mass is also reasonable given their typically slow growth. Surgical intervention may be warranted if/when pericardial effusion is present (which is not in this case).

SPECIES

Canine

Anesthesia considerations:
 No special considerations are necessary.

BREED

French Bulldog

Diet:
 No special considerations are necessary. Any high-quality food from Hills, Royal Canin, Science Diet, Eukanuba, Iams, or Purina is reasonable.

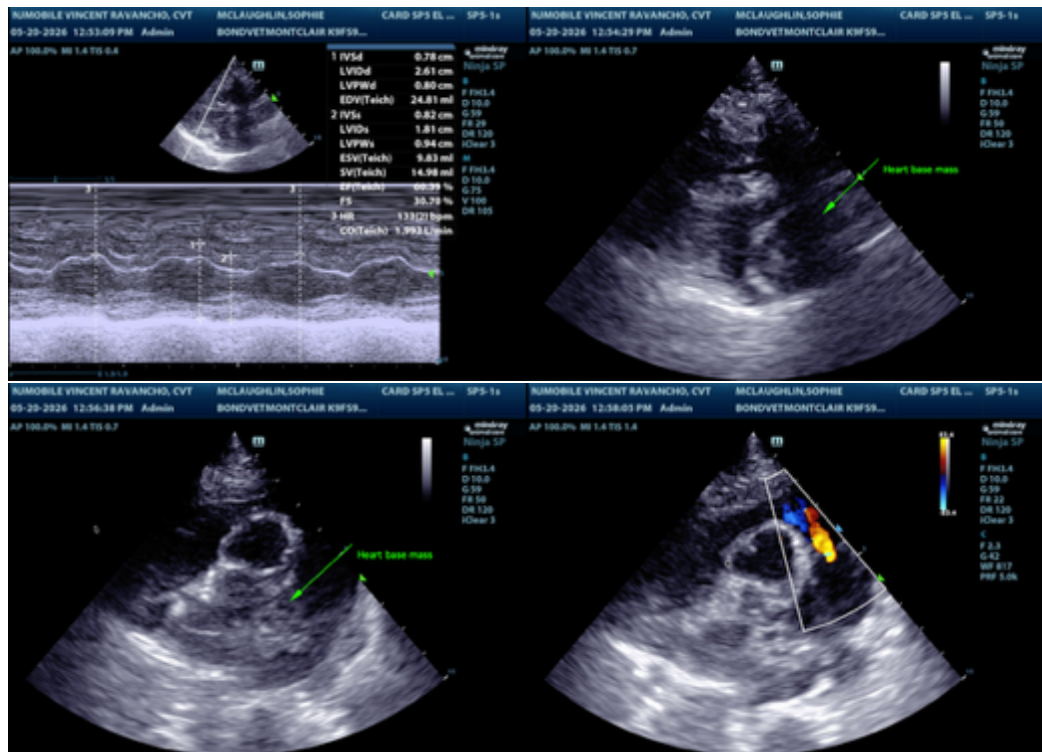
SEX

FS

Activity:
 No special considerations are necessary.

AGE

9 years 2 months



WEIGHT

11.4 kgs

INTERPRETED BY

Bradley Harris, DVM,
 DACVECC, DACVIM
 (cardiology)

IMAGING PERFORMED BY

Vincent Ravancho,
 CVT

HOSPITAL NAME

Bond Vet Mondclair

REFERRING VET

Dr. Sposato

The information and recommendations provided are based on the images presented by the referring veterinarian/sonographer. No evaluation can be communicated regarding pathology that was not visible in the image/video clips provided.

INVOICE

11976

Thank you for this referral. If the clinical or image interpretation does not parallel your findings or if I can be of any further assistance please contact me.

DATE

5/20/2026

Bradley Harris, DVM, DACVECC, DACVIM (cardiology)

info@SonoPath.com