



## PATIENT

Snickers Bango

## SPECIES

Feline

## BREED

Domestic Shorthair

## SEX

Spayed Female

## AGE

15 year

## WEIGHT

4.52 kg

## INTERPRETED BY

Bradley Harris, DVM,  
DACVECC, DACVIM  
(cardiology)

## IMAGING PERFORMED BY

Dr. Ethan Bloomer

## HOSPITAL NAME

Echosound Veterinary  
Mobile Imaging  
Services

## REFERRING VET

Dr. Kelly Vida

## INVOICE

77755

## DATE

5/20/26

## PRESENTING CLINICAL SIGNS

History: Patient presented recently for an acute collapse episode with ventroflexion of the neck. On exam, the patient had a new heart murmur and a significantly elevated blood pressure, and bloodwork showed a decreased Potassium (~2.3). Due to concerns for a vascular event/stroke and hypertension, the patient was placed on Amlodipine 1.25 mg SID and Clopidogrel 18.75 mg SID. Recheck on 5/18/26 showed improved but still mildly decreased Potassium at 3.1 and significantly elevated CK at ~5,000. The patient is currently much better at home, but echocardiogram was recommended for further work-up.

## ULTRASONOGRAPHIC EXAMINATION OF THE HEART

The left atrium is normal in dimension. There are no distinct left atrial thrombi/clots or spontaneous echo contrast appreciated. The left ventricle is normal in dimension as well as wall thickness, and no evidence of restriction. Left ventricular systolic function is normal, with adequate contractility based on fractional shortening and systolic left ventricular dimensions. The right atrium and ventricle are subjectively normal in dimension and systolic function. There is evidence of systolic anterior motion of the mitral valve with trace mitral regurgitation. The tricuspid valve leaflets presented normal linear structure, extension in systole, and union in diastole without regurgitation. The left ventricular outflow tract demonstrated turbulent flow and subjective structural valvular integrity. The visible aorta is unremarkable. Pulmonary outflow tract assessment revealed normal valve structure, laminar flow, and appropriate diameter and distensibility. There is no evidence of semilunar valve insufficiency or pulmonary hypertension documented. There is no visible pericardial, pleural, or free peritoneal fluid noted.

FELINE CARDIAC PARAMETERS	BODY WEIGHT (kg)	HR (BPM)	IVSd (cm)	LVIDd (cm)	LVWd (cm)	FS (%)	EF (%)
NORMAL PARAMETER	-----	150-240	0.3-0.6	1.0-2.1	0.25-0.6	35-67	80-100
PATIENT	4.52 kg	NM	0.55	1.22	0.45	72	NM
FELINE CARDIAC PARAMETERS	LA/AO (M-mode)	LA/AO HEART BASE (Sisson)	LAD LA MAX 4 Chamber		LVOT VEL. (m/s)	RVOT VEL. (m/s)	IVRT (m/)
NORMAL PARAMETER	<1.5	1.6	0.7-1.7		<1.6	<1.3	40-60
PATIENT	1.5	1.54	1.66		1.4	1.2	NM
Adapted from June Boon, Veterinary Echocardiography, 1998 Sisson D et al. JVIM 1991; 5: 232, Jacobs et al. Am J Vet Res 1985; 46:1705							

## ULTRASONOGRAPHIC FINDINGS

These findings are consistent with dynamic subaortic stenosis, as there is SAM present, but no convincing hypertrophy is identified. It is unlikely that any of the clinical/radiographic signs are related to underlying heart disease.



## PATIENT

Snickers Bango

## SPECIES

Feline

## BREED

Domestic Shorthair

## SEX

Spayed Female

## AGE

15 year

## WEIGHT

4.52 kg

## INTERPRETED BY

Bradley Harris, DVM,  
DACVECC, DACVIM  
(cardiology)

## IMAGING PERFORMED BY

Dr. Ethan Bloomer

## HOSPITAL NAME

Echosound Veterinary  
Mobile Imaging  
Services

## REFERRING VET

Dr. Kelly Vida

## INVOICE

77755

## DATE

5/20/26

\*\*Given the presentation of acute hypokalemia and muscle weakness/cervical ventroflexion, hyperaldosteronism is a concern. This is typically secondary to a functional adrenal tumor, and can result in systemic hypertension. These patients typically require aldosterone antagonists or surgery. Evaluation of the abdomen is recommended.

## INTERPRETATION OF THE FINDINGS & FURTHER RECOMMENDATIONS

Given the absence of any underlying heart disease, no cardiac therapy will be recommended. In addition, there are no cardiac objections to fluid therapy or steroid use. Owing to the presence of an outflow tract obstruction, a follow up echo is recommended in another 6-12 months to make sure no progression has occurred.

### Anesthesia considerations:

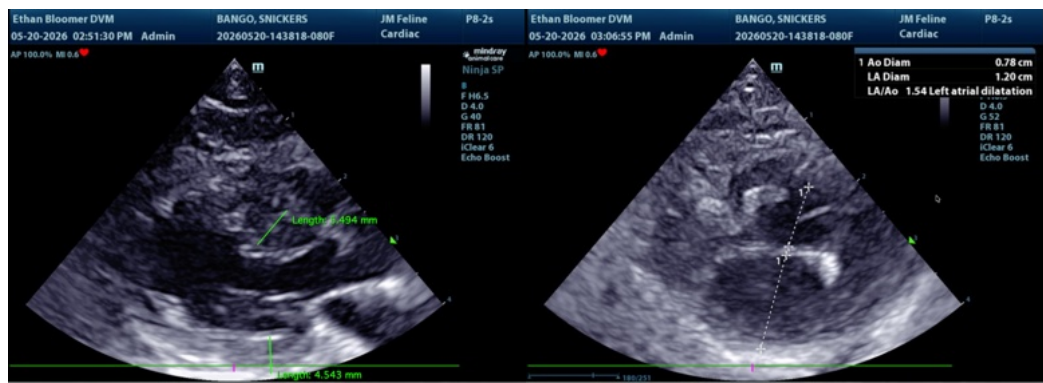
If anesthesia is necessary, then alpha-2 agonists, ketamine, high dose acepromazine, and Telazol should be avoided. Fluid therapy during anesthesia should be considered at a reduced rate (e.g., 5 ml/kg/hour) if possible (i.e., if not hypotensive). A shorter anesthetic duration will reduce the risk of complications. Pre-oxygenation is advised. Premedication with an opioid (i.e., butorphanol, hydromorphone, oxymorphone) with or without a benzodiazepine is generally the safest protocol. An induction agent such as Propofol, alfaxalone can be used to effect. Maintenance of anesthesia with isoflurane or sevoflurane is reasonable.

### Diet:

No special considerations are necessary. Any high-quality food from Hills, Royal Canin, Science Diet, Eukanuba, Iams, or Purina is reasonable.

### Activity:

No special considerations are necessary.





**PATIENT**

Snickers Bango

**SPECIES**

Feline

**BREED**

Domestic Shorthair

**SEX**

Spayed Female

**AGE**

15 year

**WEIGHT**

4.52 kg

**INTERPRETED BY**

Bradley Harris, DVM,  
DACVECC, DACVIM  
(cardiology)

**IMAGING PERFORMED BY**

Dr. Ethan Bloomer

**HOSPITAL NAME**

Echosound Veterinary  
Mobile Imaging  
Services

**REFERRING VET**

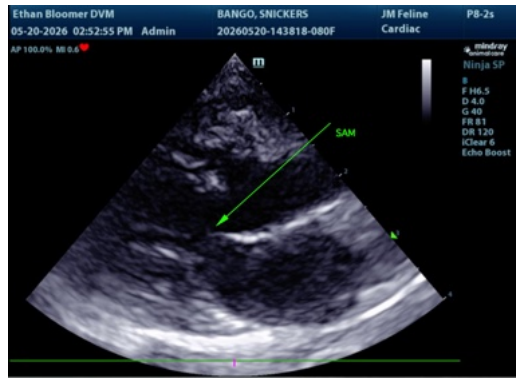
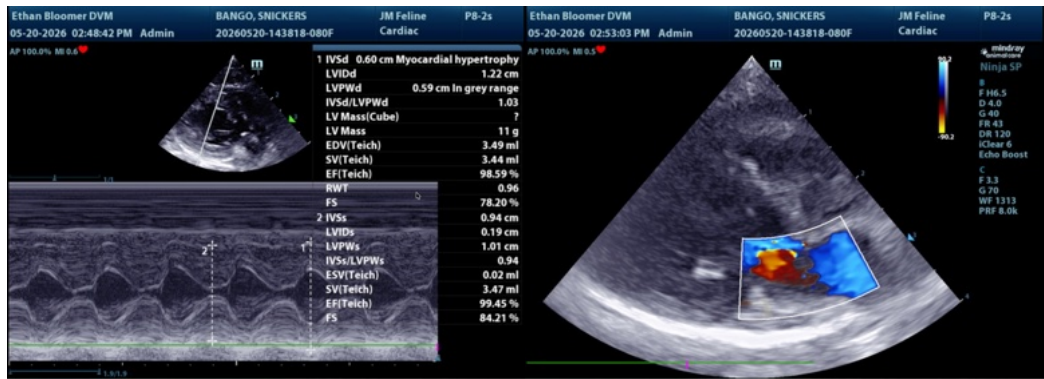
Dr. Kelly Vida

**INVOICE**

77755

**DATE**

5/20/26



The information and recommendations provided are based on the images presented by the referring veterinarian/sonographer. No evaluation can be communicated regarding pathology that was not visible in the image/video clips provided.

Thank you for this referral. If the clinical or image interpretation does not parallel your findings or if I can be of any further assistance please contact me.

Bradley Harris, DVM, DACVECC, DACVIM (cardiology)

[info@SonoPath.com](mailto:info@SonoPath.com)