



**PATIENT**

Punky Fernandez

**SPECIES**

Canine

**BREED**

Dachshund

**SEX**

Spayed female

**AGE**

16 years

**WEIGHT**

8.8 lbs

**INTERPRETED BY**

Bradley Harris, DVM,  
DACVECC, DACVIM  
(cardiology)

**IMAGING PERFORMED BY**

Dr. Ferrer

**HOSPITAL NAME**

Pulse Pet Ultrasound  
Service

**REFERRING VET**

Dr. Cajigas

**INVOICE**

77740

**DATE**

5/20/26

**PRESENTING CLINICAL SIGNS**

History: - Px presented as a referral for a double study (echocardiogram and abdominal ultrasound). Px originally presented to rDVM due to hematuria and a persistent dry cough. Radiographs were performed and cardiomegaly and a nephrolith were visualized. A urinalysis was also performed and a UTI was confirmed. No vomiting, no diarrhea, no PU/PD/PP, no exercise intolerance, and no episodes of syncope currently reported by owner. Px is currently taking the following Mx: Zeniquin 25mg tab, Meloxicam oral suspension 1.5mg/mL. Px was seen on 03/11/2025 for an echocardiogram study, the report will be attached below. Bloodwork, Urinalysis, and last performed echocardiogram report attached below for your reference.

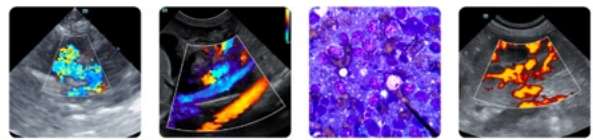
**ULTRASONOGRAPHIC EXAMINATION OF THE HEART**

The left atrium is normal in dimension. The left ventricle is normal in dimension, with normal systolic function. The right atrium and ventricle are normal in dimension, with normal systolic function. The anterior and posterior mitral valve leaflets are thickened and redundant consistent with myxomatous changes, and there is minimal prolapse. There is trivial mitral regurgitation identified. The tricuspid valve leaflets are appropriately thin with adequate apposition, intact chordae, no significant tricuspid regurgitation and no evidence of pulmonary hypertension. The left ventricular outflow tract demonstrated normal laminar flow and the visible aorta is unremarkable. The right ventricular outflow tract assessment revealed normal laminar flow, with appropriate main pulmonary artery diameter and right pulmonary artery distensibility. There is no pulmonic and mild aortic valve insufficiency identified. There is no visible pericardial, pleural, or free peritoneal fluid documented. No evidence of hepatic venous congestion is noted. The cardiac chambers, pericardial and visible extra-cardiac regions were free of masses, spontaneous echo contrast, or thrombi.

CANINE CARDIAC PARAMETERS	Body Weight kg	HR BPM	LAD 4 ch Long	RAD 4 ch Long	La/Ao Heart Base	LVIDd	LVIDs
NORMAL PARAMETER		50-100			<1.6		
PATIENT	4.0 kg	NM	2.32	NM	1.04	2.37	1.25
CANINE CARDIAC PARAMETERS	FS	EPSS	PV V MAX (m/s)	AV V Max (m/sec)	MR Vmax	TR Vmax	RPA distensibility (normal >30%)
NORMAL PARAMETER	28-40	<0.6	0.7-1.6	0.7-1.7	4.5-5.5	< 2.7	
PATIENT	47	0.3	0.6	1.2	NM	NM	30

**ULTRASONOGRAPHIC FINDINGS**

These findings are consistent with degenerative/myxomatous mitral valve disease with minimal to mild hemodynamic effects consistent with ACVIM Stage B1 disease. It is unlikely that any current morbidity is of cardiac origin.



## PATIENT

Punky Fernandez

## SPECIES

Canine

## BREED

Dachshund

## SEX

Spayed female

## AGE

16 years

## WEIGHT

8.8 lbs

## INTERPRETED BY

Bradley Harris, DVM,  
DACVECC, DACVIM  
(cardiology)

## IMAGING PERFORMED BY

Dr. Ferrer

## HOSPITAL NAME

Pulse Pet Ultrasound  
Service

## REFERRING VET

Dr. Cajigas

## INVOICE

77740

## DATE

5/20/26

## INTERPRETATION OF THE FINDINGS & FURTHER RECOMMENDATIONS

Given these findings, no cardiac therapy is recommended. There are no cardiac contraindications to anesthesia, fluid therapy, vasopressor therapy, or corticosteroids as indicated for further assessment and treatment. If not already performed, baseline thoracic radiographs and blood pressure are recommended. A recheck echocardiogram is recommended in 6 months.

### Anesthesia considerations:

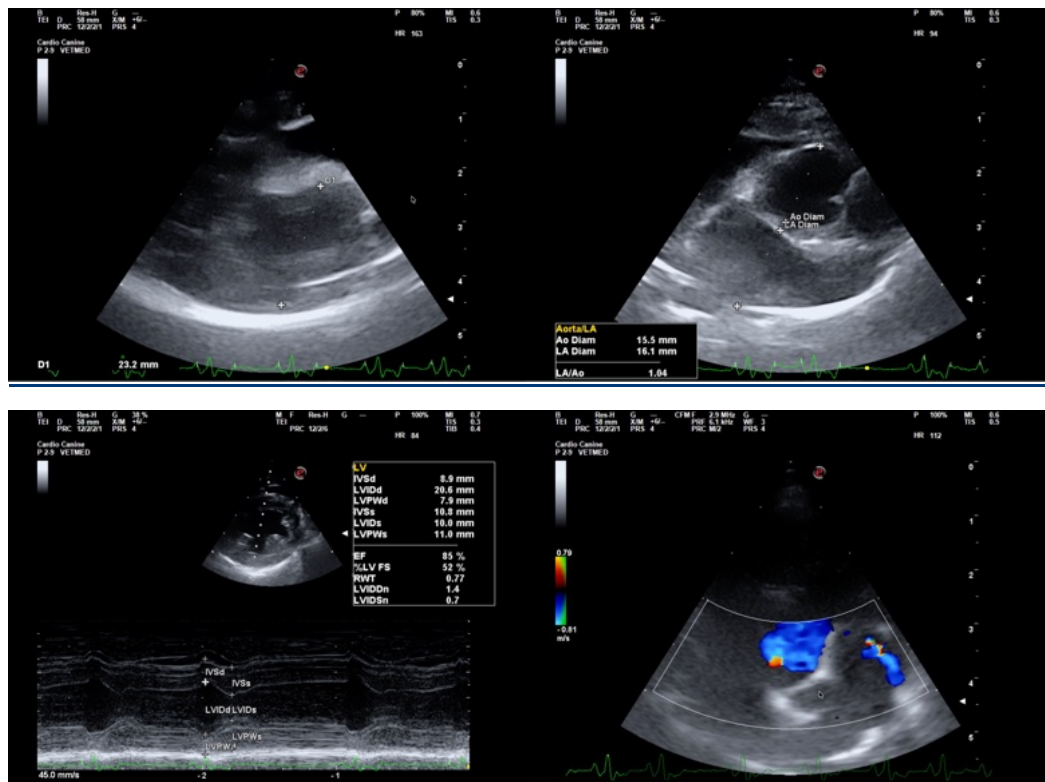
If anesthesia is necessary, alpha-2 agonists, ketamine, high dose acepromazine, and Telazol should be avoided. Fluid therapy during anesthesia should be considered at a conservative rate (e.g., 5 ml/kg/hour) if possible.

### Diet:

A high-quality food from Hills, Royal Canin, Science Diet, Eukanuba, Iams, or Purina that is highly palatable with adequate protein and calories for maintaining optimal body condition is reasonable.

### Activity:

No special considerations are necessary.



The information and recommendations provided are based on the images presented by the referring veterinarian/sonographer. No evaluation can be communicated regarding pathology that was not visible in the image/video clips provided.



## PATIENT

Punky Fernandez

## SPECIES

Canine

## BREED

Dachshund

## SEX

Spayed female

## AGE

16 years

## WEIGHT

8.8 lbs

## INTERPRETED BY

Bradley Harris, DVM,  
DACVECC, DACVIM  
(cardiology)

## IMAGING PERFORMED BY

Dr. Ferrer

## HOSPITAL NAME

Pulse Pet Ultrasound  
Service

## REFERRING VET

Dr. Cajigas

## INVOICE

77740

## DATE

5/20/26

Thank you for this referral. If the clinical or image interpretation does not parallel your findings or if I can be of any further assistance please contact me.

Bradley Harris, DVM, DACVECC, DACVIM (cardiology)

[info@SonoPath.com](mailto:info@SonoPath.com)