



## PATIENT

Davina Farrar

## SPECIES

Canine

## BREED

Rhodesian Ridgeback

## SEX

Spayed female

## AGE

5 years

## WEIGHT

115.4 lbs

## INTERPRETED BY

Bradley Harris, DVM,  
DACVECC, DACVIM  
(cardiology)

## IMAGING PERFORMED BY

Dr. Ackmann

## HOSPITAL NAME

Buffalo VC

## REFERRING VET

Dr. Bessler

## INVOICE

77685

## DATE

5/19/26

## PRESENTING CLINICAL SIGNS

History: Has started to have more rapid shallow breathing almost a pant but not with mouth open, duration of 1 week. Has had a cough/choking sound for last 3-4 days that happens sporadically. Eating and drinking fine and not lethargic. Acts normal otherwise. Pt diet is Diamond Grain Free.  
Abnormal PE/Chem/CBC/UA Results: Color paler pink, LN normal. HR fast and hard to hear but can hear an arrhythmia. EKG atrial fibrillation with HR 203, which is suggestive of underlying structural heart disease. Rads show enlarged heart with VHS 12.49 (10.7) and VLAS 3.33 also elevated. Mild pulmonary edema.

## ULTRASONOGRAPHIC EXAMINATION OF THE HEART

The left atrium is moderately enlarged. The left ventricle is moderately enlarged, with severely reduced systolic function. The right atrium and ventricle are normal in dimension, with normal systolic function. The anterior and posterior mitral valve leaflets are appropriately thin, but do not completely appose during systole due to the annular dilation, and there is no significant prolapse. There is moderate mitral regurgitation identified. The tricuspid valve leaflets are appropriately thin with adequate apposition, intact chordae, with mild tricuspid regurgitation and no evidence of pulmonary hypertension. The left ventricular outflow tract demonstrated normal laminar flow and the visible aorta is unremarkable. The right ventricular outflow tract assessment revealed normal laminar flow, with appropriate main pulmonary artery diameter and right pulmonary artery distensibility. There is no pulmonic and no aortic valve insufficiency identified. There is no visible pericardial, pleural, or free peritoneal fluid documented. No evidence of hepatic venous congestion is noted. The cardiac chambers, pericardial and visible extra-cardiac regions were free of masses, spontaneous echo contrast, or thrombi. There are numerous B-lines noted within the pulmonary parenchyma.

CANINE CARDIAC PARAMETERS	Body Weight kg	HR BPM	LAD 4 ch Long	RAD 4 ch Long	La/Ao Heart Base	LVIDd	LVIDs
NORMAL PARAMETER		50-100			<1.6		
PATIENT	52.45 kg	NM	5.86	3.65	2.05	7.18	5.51
CANINE CARDIAC PARAMETERS	FS	EPSS	PV V MAX (m/s)	AV V Max (m/sec)	MR Vmax	TR Vmax	RPA distensibility (normal >30%)
NORMAL PARAMETER	28-40	<0.6	0.7-1.6	0.7-1.7	4.5-5.5	< 2.7	
PATIENT	23	NM	0.8	NM	4.0	< 2.0	33

## ULTRASONOGRAPHIC FINDINGS

These findings are consistent with dilated cardiomyopathy with significant hemodynamic effects. Intrinsic myocardial dysfunction (ie DCM) is a concern. Other possibilities, including primary valve disease with secondary ventricular changes or myocardial depressant effects of systemic disease must



## PATIENT

Davina Farrar

## SPECIES

Canine

## BREED

Rhodesian Ridgeback

## SEX

Spayed female

## AGE

5 years

## WEIGHT

115.4 lbs

## INTERPRETED BY

Bradley Harris, DVM,  
DACVECC, DACVIM  
(cardiology)

## IMAGING PERFORMED BY

Dr. Ackmann

## HOSPITAL NAME

Buffalo VC

## REFERRING VET

Dr. Bessler

## INVOICE

77685

## DATE

5/19/26

also be considered. Because the owners are feeding a grain free diet, a secondary nutritional cardiomyopathy must also be considered. Given the degree of chamber enlargement and recent thoracic radiographs, congestive heart failure is a likely explanation for the clinical/radiographic signs.

## INTERPRETATION OF THE FINDINGS & FURTHER RECOMMENDATIONS

Therapy for CHF is recommended, with Lasix bolus (2-4 mg/kg IV PRN up to 10 mg/kg total dose) or a CRI (0.5-1 mg/kg/hr) as needed to resolve edema. Once oral therapy is started, therapy should include Lasix (2mg/kg BID), enalapril (0.5mg/kg BID assuming normotension and lack of renal insult), and Vetmedin (.25-.35mg/kg BID). Dobutamine (2.5-10 µg/kg/min as a CRI, starting at 2.5 µg/kg/min and increasing the dosage incrementally) may be used in addition to the above treatments to improve the left ventricular function and blood pressure in patients that fail to respond adequately to diuretics, pimobendan, sedation, oxygen, and comfort care measures. An immediate diet change is necessary, and the addition of taurine (50 mg/kg BID) also indicated. If there is any concern for metabolic/systemic disease, additional testing (complete bloodwork including T4 and resting cortisol, abdominal ultrasound) should be considered. Otherwise, a repeat chest X-rays, BP, and chemistry should be performed now for a baseline, and again in 1-2 weeks. A repeat echo is indicated in 3 months. Owners should monitor resting respiratory rate at home. Values above 30 breaths/minute or an increase in respiratory rate 10% above baseline should prompt veterinary re-evaluation.

The following sources for supplemental taurine are recommended:

- Mega taurine caps by Twinlab (1000mg capsule)
- Taurine by Swanson Health Products (500mg capsule)
- Taurine by NOW foods (500mg capsule)
- Taurine 500 by GNC (500mg tablet)

### Anesthesia considerations:

Anesthesia should be avoided until manifestations of congestive heart failure (edema/effusion/respiratory distress) have resolved. Following that time, if anesthesia is necessary, then alpha-2 agonists, ketamine, high dose acepromazine, and Telazol should be avoided. If an ACE inhibitor (enalapril, benazepril) or spironolactone is being given, it should not be administered on the morning of general anesthesia. Other cardiac medications should be administered per the normal dosing schedule. Anesthetic IV fluid use should be limited to < 3 ml/kg/hr and, if IV fluid therapy is administered during the procedure, a 1 mg/kg dose of IM Lasix should be administered when the patient is awake and standing in recovery. A shorter anesthetic duration will reduce the risk of complications. Pre-oxygenation is advised. Premedication with an opioid (i.e., butorphanol, hydromorphone, oxymorphone) with or without a benzodiazepine is generally the safest protocol. An induction agent such as Propofol, alfaxalone, or diazepam/etomidate can be used to effect. Maintenance of anesthesia with isoflurane or sevoflurane is reasonable. Dobutamine (2.5-10 µg/kg/min as a CRI, starting at 2.5 µg/kg/min and increasing the dosage incrementally) may be used in lieu of fluid boluses to augment systemic blood pressure.

### Diet:

A high-quality food from Hills, Royal Canin, Science Diet, Eukanuba, Iams, or Purina that is highly palatable with adequate protein and calories for maintaining optimal body condition with mild dietary sodium restriction (< 100 mg/100 kcal) is recommended. Consider omega-3 fatty acid supplementation. Avoid any boutique, exotic, or grain-free diets.

### Activity:

Moderate physical activity (meandering walks, exploring the backyard, playing with toys inside, getting excited when family gets home, etc.) is encouraged, but periods of strenuous aerobic activity (jogging,



**PATIENT**

Davina Farrar

**SPECIES**

Canine

**BREED**

Rhodesian Ridgeback

**SEX**

Spayed female

**AGE**

5 years

**WEIGHT**

115.4 lbs

**INTERPRETED BY**

Bradley Harris, DVM,  
DACVECC, DACVIM  
(cardiology)

**IMAGING PERFORMED BY**

Dr. Ackmann

**HOSPITAL NAME**

Buffalo VC

**REFERRING VET**

Dr. Bessler

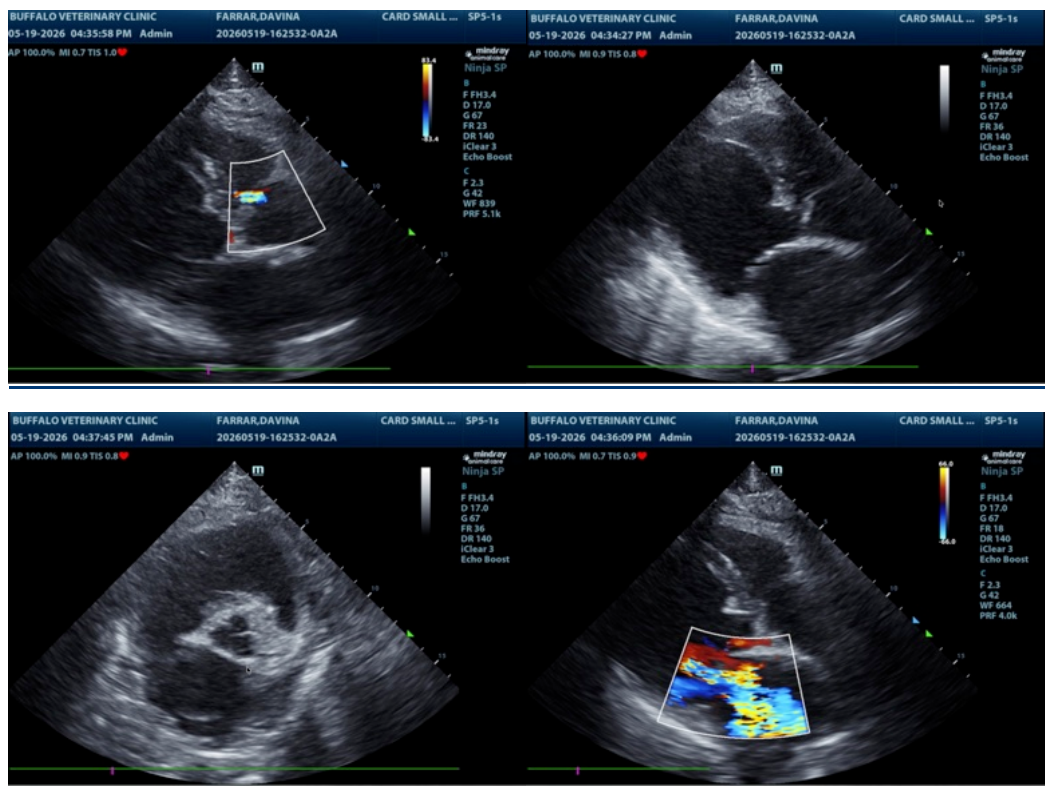
**INVOICE**

77685

**DATE**

5/19/26

strenuous outdoor ball play, prolonged play at the dog park, etc.) should be avoided, especially during periods of high heat (> 80 F) and humidity. Dogs with heart disease tend to tolerate cool and cold temperatures much better than high temperatures. Avoid sudden increases in activity (e.g. 2 block walks during the week but 2 mile walks followed by 30 minutes at the dog park on the weekends) as this may be difficult for the cardiovascular system to deal with.



The information and recommendations provided are based on the images presented by the referring veterinarian/sonographer. No evaluation can be communicated regarding pathology that was not visible in the image/video clips provided.

Thank you for this referral. If the clinical or image interpretation does not parallel your findings or if I can be of any further assistance please contact me.

Bradley Harris, DVM, DACVECC, DACVIM (cardiology)

[info@SonoPath.com](mailto:info@SonoPath.com)