

PATIENT

Bud Harvey

SPECIES

Canine

BREED

Labrador Retriever

SEX

Neutered male

AGE

3 years

WEIGHT

94.5 lbs

INTERPRETED BY

Brad Harris, DVM,
 DACVECC, DACVIM
 (cardiology)

IMAGING PERFORMED BY

-

HOSPITAL NAME

Armstrong AC

REFERRING VET

Dr. Aquino

INVOICE

77709

DATE

5/19/26

PRESENTING CLINICAL SIGNS

Reason for the Holter: Ventricular premature contractions, recheck after 1 year.
 Was an echo ever done on the animal? Did we do the report? If not, please attach the report.: Echo performed by SonoPath on 06/13/2025, first Holter Monitor applied on 07/07/2025 per SonoPath's recommendation.
 Any Medications: Pt is not on any medications aside from monthly hwp/ftp (Simparica Trio).

HOLTER MONITOR STUDY

Total Beats: 85824

Heart rate

Mean: 60

Minimum: 29

Maximum: 251

Predominant Rhythm: Normal sinus rhythm

Supraventricular Events: 0

Bradycardia Events: 40414

Ventricular Ectopic Events

Ventricular premature complexes: 555

Ventricular premature couplets: 0

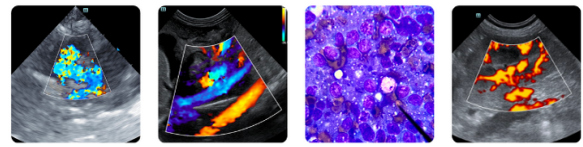
Ventricular runs or ventricular tachycardia: 0

HOLTER MONITOR FINDINGS

These findings identify an underlying normal sinus rhythm. A sinus tachycardia is seen at times, presumably with activity; but the rate appears to drop appropriately with rest. There are isolated single VPCs throughout. The complexes are monomorphic with single episodes of brief bigeminy, trigeminy, and quadrigeminy. No couplets, triplets or ventricular tachycardia is identified.

INTERPRETATION OF THE FINDINGS & FURTHER RECOMMENDATIONS

This monitor documents and underlying normal sinus rhythm with frequent single premature ventricular complexes. There are no other markers of malignancy, and no significant progression since the previous study. As such, no antiarrhythmic therapy will be recommended at this time. Continued close monitoring at home with a repeat Holter and echocardiogram in 12 months, or sooner if any clinical signs develop. Additional systemic evaluation may be indicated (if not already performed). The addition of fish oil supplementation (1000mg omega 3/6 BID) is also reasonable.



PATIENT

Bud Harvey

SPECIES

Canine

BREED

Labrador Retriever

SEX

Neutered male

AGE

3 years

WEIGHT

94.5 lbs

INTERPRETED BY

Brad Harris, DVM,
DACVECC, DACVIM
(cardiology)

IMAGING PERFORMED BY

-

HOSPITAL NAME

Armstrong AC

REFERRING VET

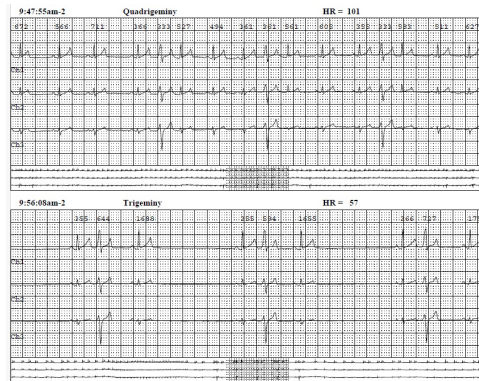
Dr. Aquino

INVOICE

77709

DATE

5/19/26



Thank you for this referral. If the clinical or image interpretation does not parallel your findings or if I can be of any further assistance please contact me.

Brad Harris, DVM, DACVECC, DACVIM (cardiology)

info@SonoPath.com