



PATIENT

Pumpkin Watzka

SPECIES

Feline

BREED

Domestic Longhair

SEX

Neutered male

AGE

5 years

WEIGHT

5.71 kg

INTERPRETED BY

Bradley Harris, DVM,
DACVECC, DACVIM
(cardiology)

IMAGING PERFORMED BY

Renee Trionfetti, VMD

HOSPITAL NAME

Firefly Veterinary
Urgent Care

REFERRING VET

Dr. Watzka

INVOICE

77669

DATE

5/18/26

PRESENTING CLINICAL SIGNS

History: Pumpkin is a 5 y/o MN DLH who was previous rehomed due to aggression. He has done well in current home. In February he had some issues with cystitis (hematuria, crystalluria and inappropriate urination) despite being on c/d multicare dry food. Switched to mostly canned food at that time as well as treatment with a short course of buprenorphine. Inappropriate urination continued sporadically, but UA showed resolution of hematuria. Patient was started on venlafaxine; inappropriate urination resolved, but patient did have some GI signs (soft stool and occasional vomiting). He has had occasional vomiting long-term which is the reason he is scheduled for ultrasound. Echo for cardiac screening, no HM.

Meds: Venlafaxine 6.25mg PO SID; Fortiflora SID

Unable to obtain Blood Pressure CBC/CHEM 11/2025 - unremarkable Lateral x-ray -> no evidence of bladder stones. UA 2/4/2026, free catch, Sedivue - >50 RBCs/hpf, 6-20 struvite crystals/hpf UA - 4/19/2026 normal

ULTRASONOGRAPHIC EXAMINATION OF THE HEART

The left atrium is normal in dimension. There are no distinct left atrial thrombi/clots or spontaneous echo contrast appreciated. The left ventricle is normal in dimension as well as wall thickness, and no evidence of restriction. Left ventricular systolic function is normal, with adequate contractility. The right atrium and ventricle are subjectively normal in dimension and systolic function. The anterior and posterior mitral and tricuspid valve leaflets presented normal linear structure, extension in systole, and union in diastole without regurgitation. There is no evidence of systolic anterior mitral valve motion documented. The left ventricular outflow tract demonstrated normal laminar flow and subjective structural valvular integrity. The visible aorta is unremarkable. Pulmonary outflow tract assessment revealed normal valve structure, laminar flow, and appropriate diameter and distensibility. There is no evidence of pulmonary hypertension documented. There is no visible pericardial, pleural, or free peritoneal fluid noted.

FELINE CARDIAC PARAMETERS	BODY WEIGHT (kg)	HR (BPM)	IVSd (cm)	LVIDd (cm)	LVWd (cm)	FS (%)	EF (%)
NORMAL PARAMETER	-----	150-240	0.3-0.6	1.0-2.1	0.25-0.6	35-67	80-100
PATIENT	5.71	170	0.45	1.43	0.47	28	58
FELINE CARDIAC PARAMETERS	LA/AO (M-mode)	LA/AO HEART BASE (Sisson)	LAD LA MAX 4 Chamber		LVOT VEL. (m/s)	RVOT VEL. (m/s)	IVRT (m/)
NORMAL PARAMETER	<1.5	1.6	0.7-1.7		<1.6	<1.3	40-60
PATIENT	1.55	1.08	1.25		0.7	0.6	NM
Adapted from June Boon, Veterinary Echocardiography, 1998 Sisson D et al. JVIM 1991; 5: 232, Jacobs et al. Am J Vet Res 1985; 46:1705							



PATIENT

Pumpkin Watzka

SPECIES

Feline

BREED

Domestic Longhair

SEX

Neutered male

AGE

5 years

WEIGHT

5.71 kg

INTERPRETED BY

Bradley Harris, DVM,
DACVECC, DACVIM
(cardiology)

IMAGING PERFORMED BY

Renee Trionfetti, VMD

HOSPITAL NAME

Firefly Veterinary
Urgent Care

REFERRING VET

Dr. Watzka

INVOICE

77669

DATE

5/18/26

ULTRASONOGRAPHIC FINDINGS

These findings are consistent with an essentially normal echocardiogram. Any murmur auscultated will be considered functional in origin.

INTERPRETATION OF THE FINDINGS & FURTHER RECOMMENDATIONS

Given these findings, no cardiac therapy is recommended. There are no cardiac contraindications to corticosteroids or fluid therapy as indicated for further treatment. No specific recheck echocardiogram is recommended.

Anesthesia considerations:

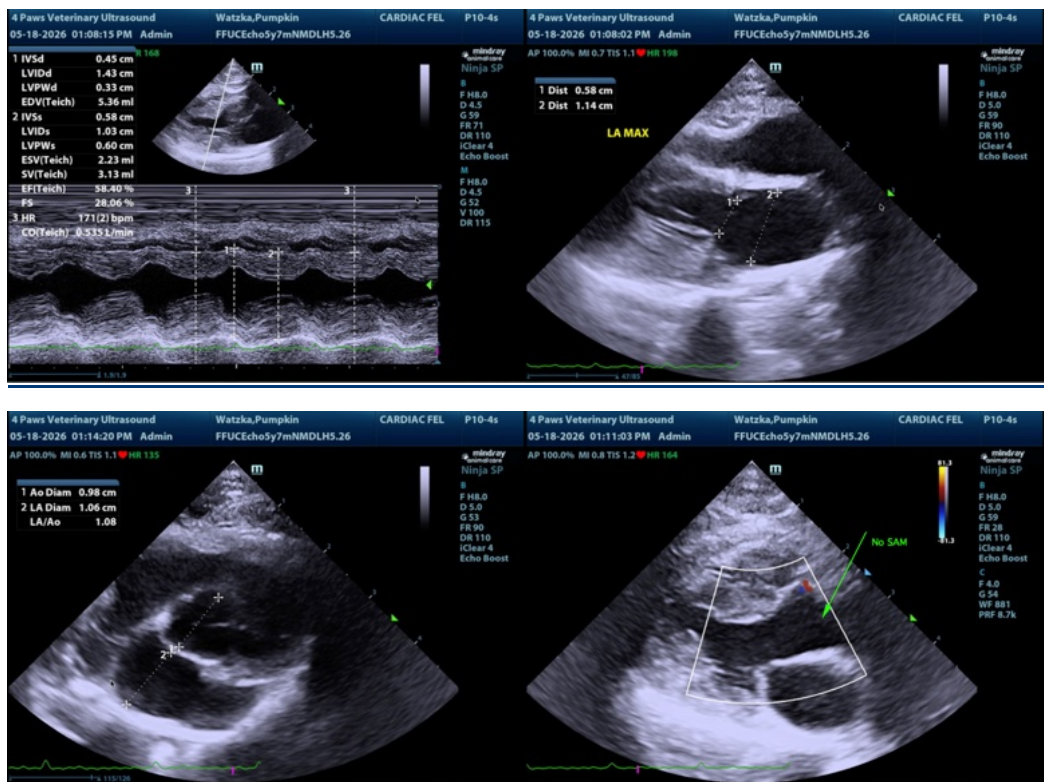
No special cardiac considerations are necessary

Diet:

No special considerations are necessary. Any high-quality food from Hills, Royal Canin, Science Diet, Eukanuba, Iams, or Purina is reasonable.

Activity:

No special considerations are necessary.



The information and recommendations provided are based on the images presented by the referring veterinarian/sonographer. No evaluation can be communicated regarding pathology that was not visible in the image/video clips provided.



PATIENT

Pumpkin Watzka

SPECIES

Feline

BREED

Domestic Longhair

SEX

Neutered male

AGE

5 years

WEIGHT

5.71 kg

INTERPRETED BY

Bradley Harris, DVM,
DACVECC, DACVIM
(cardiology)

IMAGING PERFORMED BY

Renee Trionfetti, VMD

HOSPITAL NAME

Firefly Veterinary
Urgent Care

REFERRING VET

Dr. Watzka

INVOICE

77669

DATE

5/18/26

Thank you for this referral. If the clinical or image interpretation does not parallel your findings or if I can be of any further assistance please contact me.

Bradley Harris, DVM, DACVECC, DACVIM (cardiology)

info@SonoPath.com