



PATIENT

Annie McIntosh

SPECIES

Canine

BREED

Miniature Pinscher

SEX

Spayed femlae

AGE

13 ½ years

WEIGHT

4.74 kg

INTERPRETED BY

Bradley Harris, DVM,
DACVECC, DACVIM
(cardiology)

IMAGING PERFORMED BY

Dr. Brian Barnes

HOSPITAL NAME

Westview VH

REFERRING VET

Dr. Barnes

INVOICE

75520

DATE

5/14/26

PRESENTING CLINICAL SIGNS

- 1) Colitis
- 2) Pancreatitis, chronic
- 3) Hepatopathy , benign ?
- 4) Gallbladder debris, developing early Mucocele
- 5) Chronic renal changes with mild medullary mineral
- 6) Gastroesophageal reflux secondary to cough
- 7) Allergic bronchitis
- 8) DMVD Stage B1
- 9) Trace TR
- 1) Coughing on and off

Blood work pending, Dog is BAR/H Pink MM. Hyper Eyes aging changes lens. Ears bilateral otitis externa, more debris in right canal. Grade 1-2 dental disease, no halitosis, and no gingivitis. LN palpate normal, Heart is reg/reg with grade 2-3/6 holosystolic murmur, PMI left hemithorax murmurs and no Arrhythmias. Lungs are clear with no adventitial sounds. Easily induced tracheal cough with digital palpation Abdomen NAF with palpation. Coat and skin look good, No limping

ULTRASONOGRAPHIC EXAMINATION OF THE HEART

The left atrium is normal in dimension. The left ventricle is normal in dimension, with normal systolic function. The right atrium and ventricle are normal in dimension, with normal systolic function. The anterior and posterior mitral valve leaflets are thickened and redundant consistent with myxomatous changes, and there is mild prolapse. There is mild mitral regurgitation identified. The tricuspid valve leaflets are minimally thickened, with trivial tricuspid regurgitation and no evidence of pulmonary hypertension. The left ventricular outflow tract demonstrated normal laminar flow and the visible aorta is unremarkable. The right ventricular outflow tract assessment revealed normal laminar flow, with appropriate main pulmonary artery diameter and right pulmonary artery distensibility. There is no pulmonic and no aortic valve insufficiency identified. There is no visible pericardial, pleural, or free peritoneal fluid documented. No evidence of hepatic venous congestion is noted. The cardiac chambers, pericardial and visible extra-cardiac regions were free of masses, spontaneous echo contrast, or thrombi.

CANINE CARDIAC PARAMETERS	Body Weight kg	HR BPM	LAD 4 ch Long	RAD 4 ch Long	La/Ao Heart Base	LVIDd	LVIDs
NORMAL PARAMETER		50-100			<1.6		
PATIENT	4.74 kg	150	2.51	1.8	1.36	2.34	1.14
CANINE CARDIAC PARAMETERS	FS	EPSS	PV V MAX (m/s)	AV V Max (m/sec)	MR Vmax	TR Vmax	RPA distensibility (normal >30%)
NORMAL PARAMETER	28-40	<0.6	0.7-1.6	0.7-1.7	4.5-5.5	< 2.7	
PATIENT	51	0.3	1.0	1.3	4.0	NM	NM



PATIENT

Annie McIntosh

SPECIES

Canine

BREED

Miniature Pinscher

SEX

Spayed femlae

AGE

13 ½ years

WEIGHT

4.74 kg

INTERPRETED BY

Bradley Harris, DVM,
DACVECC, DACVIM
(cardiology)

IMAGING PERFORMED BY

Dr. Brian Barnes

HOSPITAL NAME

Westview VH

REFERRING VET

Dr. Barnes

INVOICE

75520

DATE

5/14/26

ULTRASONOGRAPHIC FINDINGS

These findings are consistent with degenerative/myxomatous mitral valve disease with minimal to mild hemodynamic effects consistent with ACVIM Stage B1 disease. It is unlikely that any current morbidity is of cardiac origin.

INTERPRETATION OF THE FINDINGS & FURTHER RECOMMENDATIONS

Given these findings, no cardiac therapy is recommended. There are no cardiac contraindications to anesthesia, fluid therapy, vasopressor therapy, or corticosteroids as indicated for further assessment and treatment. If not already performed, baseline thoracic radiographs and blood pressure are recommended. A recheck echocardiogram is recommended in 6 months.

Anesthesia considerations:

If anesthesia is necessary, alpha-2 agonists, ketamine, high dose acepromazine, and Telazol should be avoided. Fluid therapy during anesthesia should be considered at a conservative rate (e.g., 5 ml/kg/hour) if possible.

Diet:

A high-quality food from Hills, Royal Canin, Science Diet, Eukanuba, Iams, or Purina that is highly palatable with adequate protein and calories for maintaining optimal body condition is reasonable.

Activity:

No special considerations are necessary.



PATIENT

Annie McIntosh

SPECIES

Canine

BREED

Miniature Pinscher

SEX

Spayed femlae

AGE

13 ½ years

WEIGHT

4.74 kg

INTERPRETED BY

Bradley Harris, DVM,
DACVECC, DACVIM
(cardiology)

IMAGING PERFORMED BY

Dr. Brian Barnes

HOSPITAL NAME

Westview VH

REFERRING VET

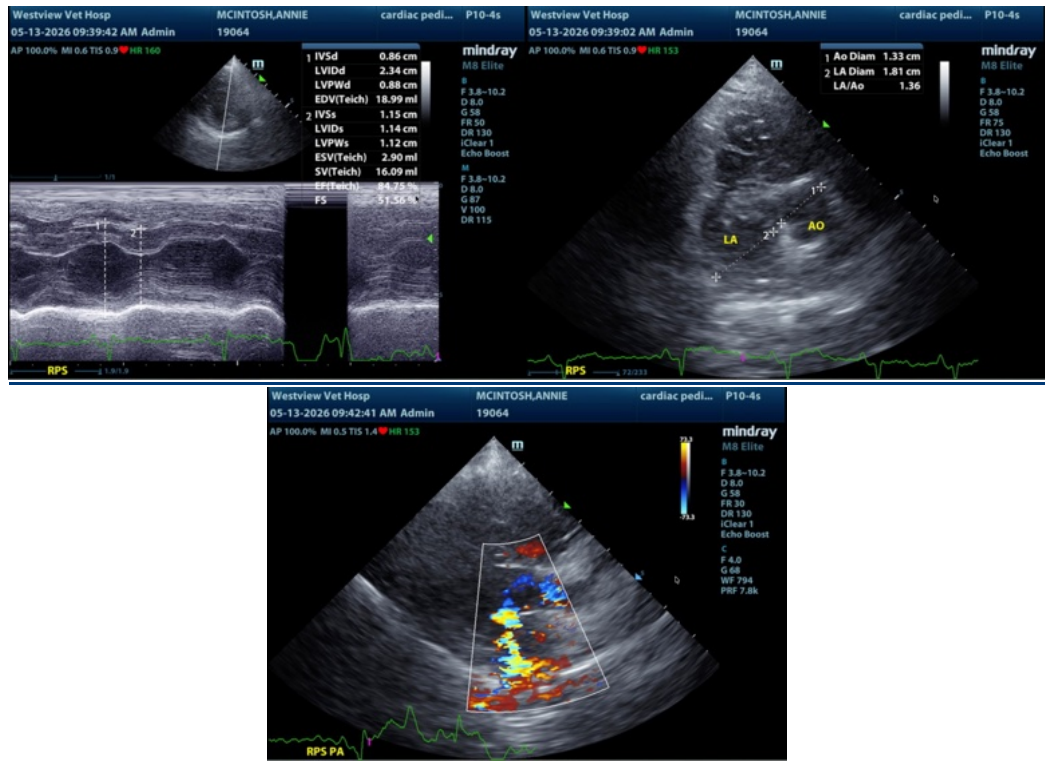
Dr. Barnes

INVOICE

75520

DATE

5/14/26



The information and recommendations provided are based on the images presented by the referring veterinarian/sonographer. No evaluation can be communicated regarding pathology that was not visible in the image/video clips provided.

Thank you for this referral. If the clinical or image interpretation does not parallel your findings or if I can be of any further assistance please contact me.

Bradley Harris, DVM, DACVECC, DACVIM (cardiology)

info@SonoPath.com