



**DATE PRESENTING CLINICAL SIGNS**

5/12/26

**PATIENT**

Sunny Abate

**SPECIES**

Canine

**BREED**

Golden Retriever

**SEX**

Spayed female

**AGE**

3/18/15

**WEIGHT**

91.7 lbs

**INTERPRETED BY**

Bradley Harris, DVM,  
DACVECC, DACVIM  
(cardiology)

**HOSPITAL NAME**

Chadwell AH

**REFERRING VET**

Dr. Schaupp

**INVOICE**

75344

**History:** Exercise intolerance, gets winded easily, not keeping up on walks. This pet has always been overweight but recently lost 4 lbs. History of protein losing nephropathy (under control). PE - heart sounds a bit muffled, no heart murmur, obese, no pain on palpation of spine, walking well, gets up from sitting position well. No pain on rotation of coxofemoral joints. Pink mmemb.  
**Pertinent abnormal PE/Chem/CBC/UA Results:** Attached, reported as: Mildly anemic.. Radiographs - possible slight right sided heart enlargement.  
**Current medications:** Dasuquin, Telmisartan 20 mg - 2 tabs PO QD  
**Blood Pressure:** 100mmHg  
**Sedation used:** Not required to complete full diagnostic ultrasound.  
**Pertinent previous ultrasound results:** No previous.  
**STAT:** Not requested.  
**Imaging performed by:** Stephanie Warga RDCS, RVT.

**ULTRASONOGRAPHIC EXAMINATION OF THE HEART**

The left atrium is normal in dimension. The left ventricle is normal in dimension, with normal systolic function. The right atrium and ventricle are normal in dimension, with normal systolic function. The anterior and posterior mitral valve leaflets are appropriately thin with adequate apposition, intact chordae, and there is no significant prolapse. There is no significant mitral regurgitation identified. The tricuspid valve leaflets are appropriately thin with adequate apposition, intact chordae, with trivial tricuspid regurgitation and evidence of borderline pulmonary hypertension. The left ventricular outflow tract demonstrated normal laminar flow and the visible aorta is unremarkable. The right ventricular outflow tract assessment revealed normal laminar flow, with appropriate main pulmonary artery diameter and right pulmonary artery distensibility. There is no pulmonic and no aortic valve insufficiency identified. There is no visible pericardial, pleural, or free peritoneal fluid documented. No evidence of hepatic venous congestion is noted. The cardiac chambers, pericardial and visible extra-cardiac regions were free of masses, spontaneous echo contrast, or thrombi.

CANINE CARDIAC PARAMETERS	Body Weight kg	HR BPM	LAD 4 ch Long	RAD 4 ch Long	La/Ao Heart Base	LVIDd	LVIDs
NORMAL PARAMETER		50-100			<1.6		
PATIENT	41.68	70	4.1	3.44	1.45	3.75	2.82
CANINE CARDIAC PARAMETERS	FS	EPSS	PV V MAX (m/s)	AV V Max (m/sec)	MR Vmax	TR Vmax	RPA distensibility (normal >30%)
NORMAL PARAMETER	28-40	<0.6	0.7-1.6	0.7-1.7	4.5-5.5	< 2.7	
PATIENT	25	0.5	1.3	1.6	Not Present	2.8	30

**ECG:**

A six-lead ECG is available for review. The average heart rate is approximately 70bpm, with a normal mean electrical axis. The QRS complexes are sinus in origin, with appropriate P-Q intervals. There are irregular R-R intervals, consistent with respiratory variation. There is no evidence of atrial or ventricular ectopy, nor any atrioventricular block. The underlying rhythm is most consistent with a respiratory sinus arrhythmia (normal physiologic change).

## ULTRASONOGRAPHIC FINDINGS

These findings are consistent with an essentially normal echocardiogram. Any murmur will be considered functional in origin. No cardiac cause of the morbidity is identified.

## INTERPRETATION OF THE FINDINGS & FURTHER RECOMMENDATIONS

Given these findings, no cardiac therapy is recommended. There are no cardiac contraindications to fluid therapy or corticosteroid therapy, as indicated for further assessment and treatment. No specific cardiac recheck is recommended unless a murmur or clinical signs of heart disease develop.

### Anesthesia considerations:

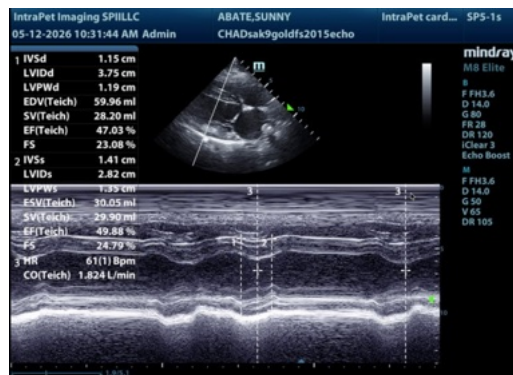
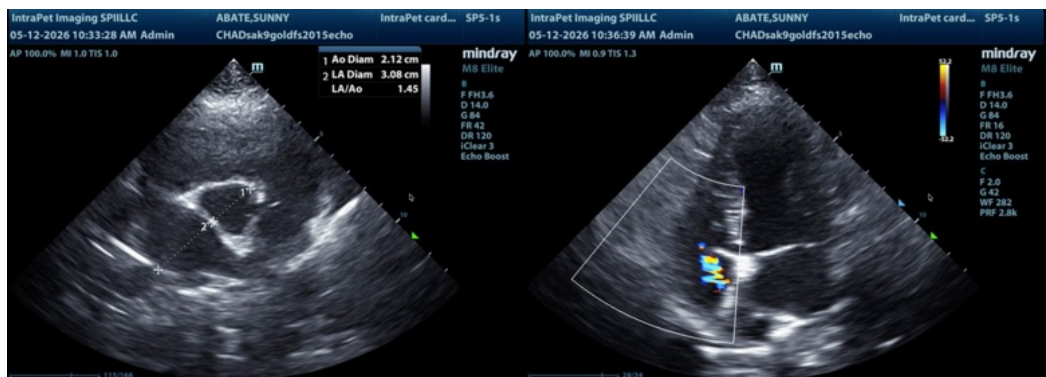
No special considerations are necessary.

### Diet:

No special considerations are necessary. Any high-quality food from Hills, Royal Canin, Science Diet, Eukanuba, Iams, or Purina is reasonable.

### Activity:

No special considerations are necessary.



The information and recommendations provided are based on the images presented by the referring veterinarian/sonographer. No evaluation can be communicated regarding pathology that was not visible in the image/video clips provided.

Thank you for this referral. If the clinical or image interpretation does not parallel your findings or if I can be of any further assistance please contact me.

Bradley Harris, DVM, DACVECC, DACVIM (cardiology)  
[info@SonoPath.com](mailto:info@SonoPath.com)