



**DATE PRESENTING CLINICAL SIGNS**

5/12/26

**PATIENT**

Bodhi Hannah

**SPECIES**

Canine

**BREED**

Chihuahua Mix

**SEX**

Neutered male

**AGE**

1/14/18

**WEIGHT**

9 lbs

**INTERPRETED BY**

Bradley Harris, DVM,  
DACVECC, DACVIM  
(cardiology)

**HOSPITAL NAME**

Falls Road AH

**REFERRING VET**

Dr. Herko

**INVOICE**

75322

**History:** Presented last night for dyspnea, pericardial and pleural effusion noted. Thoraco and pericardial centesis were performed.

**Pertinent abnormal PE/Chem/CBC/CBC/UA Results:** Labwork attached.

**Current medications:** None listed.

**Blood Pressure:** N/A.

**Sedation used:** Not required to complete full diagnostic ultrasound.

**Pertinent previous ultrasound results:** No previous.

**STAT:** requested.

**Imaging performed by:** Andi Parkinson RDMS

**ULTRASONOGRAPHIC EXAMINATION OF THE HEART**

The left atrium is normal in dimension. The left ventricle is normal to small in dimension with normal systolic function and mild intraventricular septal flattening. The right atrium is subjectively small in dimension and displays evidence of diastolic collapse/compression. The cranial aspect of the right atrioventricular wall has a sizable defect (2.8 x 2.8cm) with cavitation and mixed echogenicity that appears to be encroaching into the right ventricular lumen and may involve aspects of the tricuspid valve. The anterior and posterior mitral and tricuspid valve leaflets presented normal linear structure, extension in systole, and union in diastole without prolapse or myxomatous changes noted. There is mild pericardial, no pleural, and no free peritoneal fluid noted. The remaining cardiac chambers and visible extra-cardiac regions were free of masses, spontaneous echo contrast, or thrombi.

No cardiac measurements obtained on this patient.

**ULTRASONOGRAPHIC FINDINGS**

These findings identify pericardial effusion in the setting of a lesion in the wall of the right atrium/ventricle. The appearance and location of the mass is consistent with a thrombus, which may be a result of the reported pericardiocentesis. However, the size of the defect and its invasion into the right ventricular lumen makes this less clear. If this is indeed a tumor, the location/appearance of the mass is consistent with hemangiosarcoma, and the pericardial effusion is most likely neoplastic in origin.

**INTERPRETATION OF THE FINDINGS & FURTHER RECOMMENDATIONS**

At this time, an additional pericardiocentesis is not recommended, unless there are significant clinical signs of cardiac tamponade. No cardiac medications will be recommended at this time. A repeat evaluation is recommended in 1-2 weeks (or sooner if clinical signs develop) to re-evaluate the lesion. A thrombus would be expected to begin remodeling within that time period. If it is hemangiosarcoma, the prognosis is very poor, as recurrent effusions are likely, as is the presence of neoplasia elsewhere in the body. Ideally, an abdominal ultrasound should be considered to identify evidence of neoplasia elsewhere in the body, which (or may not) affect prognosis. If no additional masses can be identified, there may be merit to considering surgical intervention, either by taking the entire pericardium (subtotal pericardiectomy), or creation of a smaller hole via approaches less invasive than a median sternotomy. The value of surgery is simply to avoid the effects of recurrent effusion and need for multiple taps; unfortunately surgery does not alter the natural course of disease, which usually only affords a prognosis of a few months.

Anesthesia considerations:

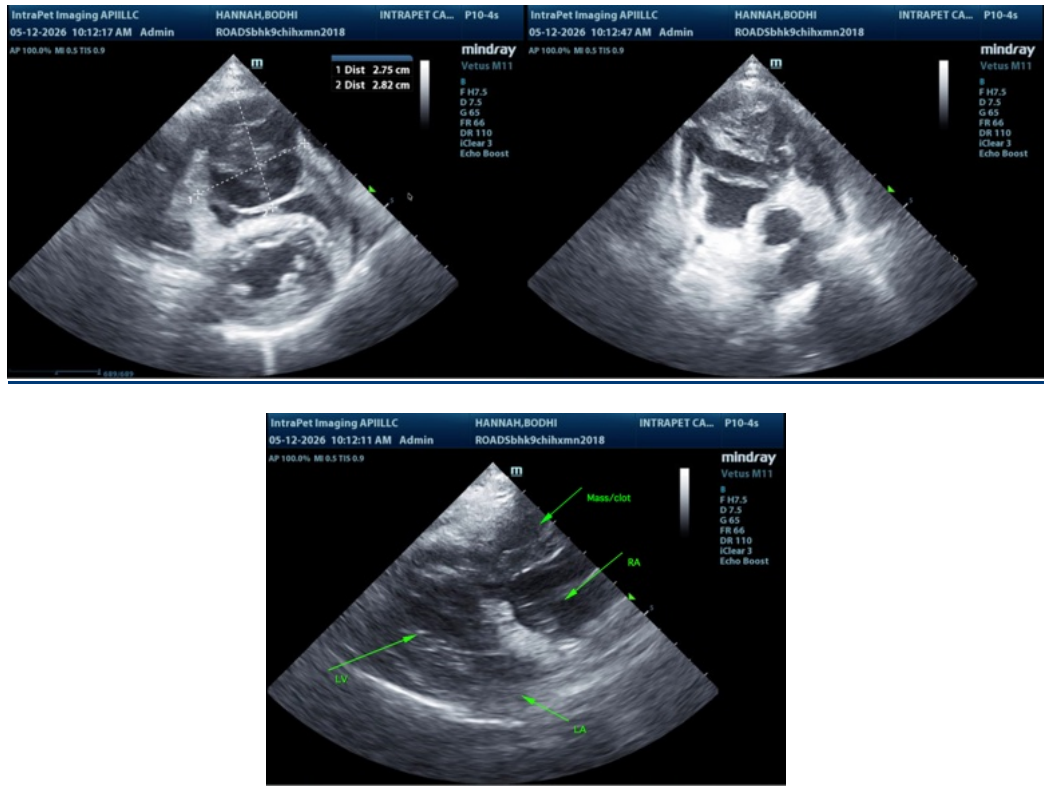
Anesthesia should be avoided until any signs of CHF and pericardial effusion have resolved. If anesthesia is necessary after that time, then alpha-2 agonists, ketamine, high dose acepromazine, and Telazol should be avoided. Fluid therapy is often necessary in the setting of cardiac tamponade to improve venous return. A shorter anesthetic duration will reduce the risk of complications. Pre-oxygenation is advised. Premedication with an opioid (e.g., butorphanol, hydromorphone, oxymorphone) with or without a benzodiazepine is generally the safest protocol. An induction agent such as Propofol, alfaxalone, or diazepam/etomidate can be used to effect. Maintenance of anesthesia with isoflurane or sevoflurane is reasonable.

Diet:

No special considerations are necessary. Any high-quality food from Hills, Royal Canin, Science Diet, Eukanuba, Iams, or Purina is reasonable.

Activity:

Moderate physical activity (meandering walks, exploring the back yard, playing with toys inside, getting excited when family gets home, etc.) is encouraged, but periods of strenuous aerobic activity (jogging, strenuous outdoor ball play, prolonged play at the dog park, etc.) should be avoided, especially during periods of high heat (> 80 F) and humidity. Dogs with heart disease tend to tolerate cool and cold temperatures much better than high temperatures. Avoid sudden increases in activity (e.g. 2 block walks during the week but 2 mile walks followed by 30 minutes at the dog park on the weekends) as this may be difficult for the cardiovascular system to deal with.



The information and recommendations provided are based on the images presented by the

**referring veterinarian/sonographer. No evaluation can be communicated regarding pathology that was not visible in the image/video clips provided.**

Thank you for this referral. If the clinical or image interpretation does not parallel your findings or if I can be of any further assistance please contact me.

Bradley Harris, DVM, DACVECC, DACVIM (cardiology)  
[info@SonoPath.com](mailto:info@SonoPath.com)